



**Australasian Division of the International Academy of Pathology Limited**

ABN 73 008 593 815

**PO Box 74, Cherrybrook, NSW 2126**

**Tel: +61 2 9894 6811 [www.iap-aus.org.au](http://www.iap-aus.org.au)**

## **Slide Seminar:**

### **FNA Casebook Pt 1: Salivary Gland**

**Cases 1 – 3**

## **Chair of the Session**

**Siaw Ming Chai**

PathWest Laboratory Medicine, Perth, WA, Australia

## **Keynote Speaker**

**Min En Nga**

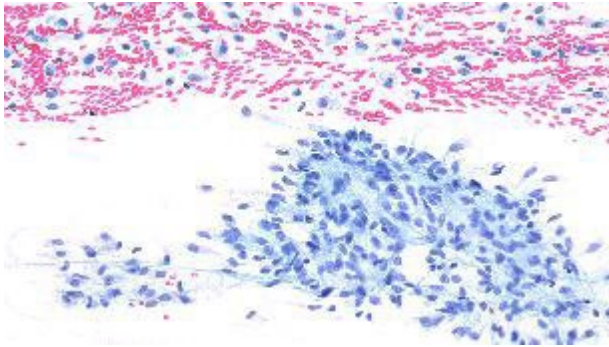
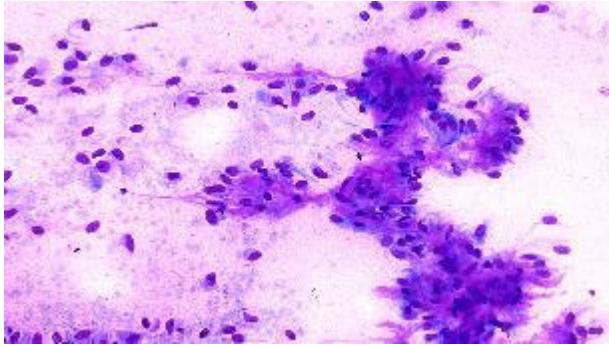
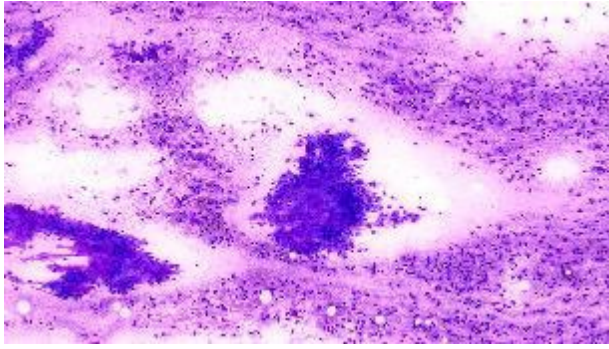
Yong Loo Lin School of Medicine, National University of Singapore &  
National University Hospital, Singapore.

**Note:** All images are subject to copyright and are only for personal use, and not for sharing or distribution.

## **Case 1**

### **A parotid lump**

**Clinical History:** A 36 year old female. Left angle of jaw lump

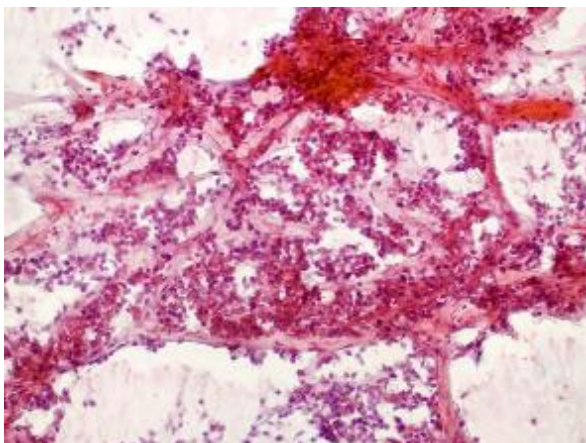
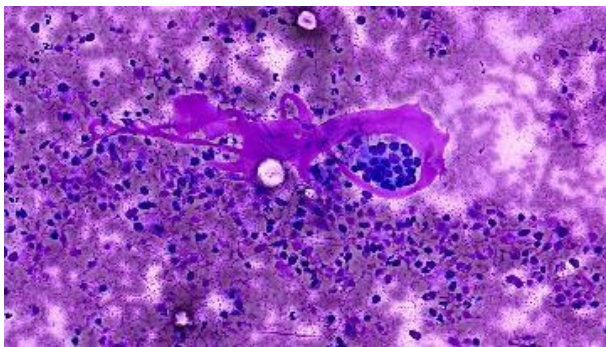
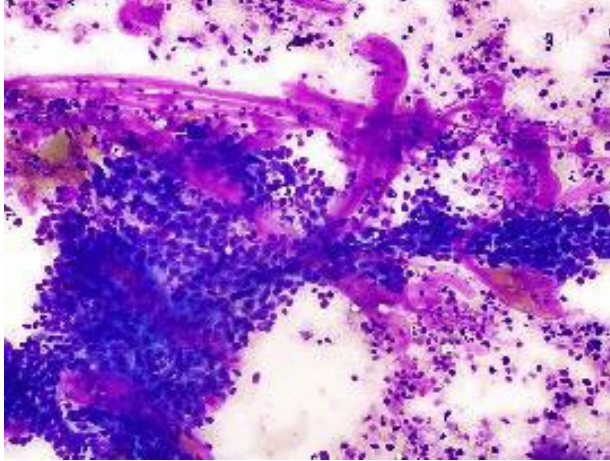


Note: All images are subject to copyright and are only for personal use, and not for sharing or distribution.

## Case 2

### A parotid lump

**Clinical History:** A 53 year old female. Right parotid lump, painless

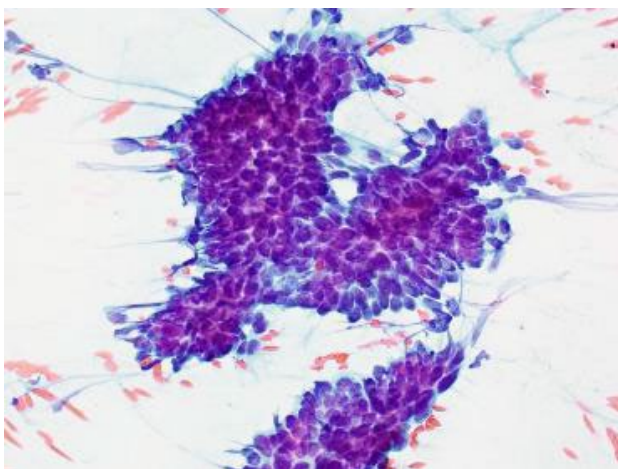
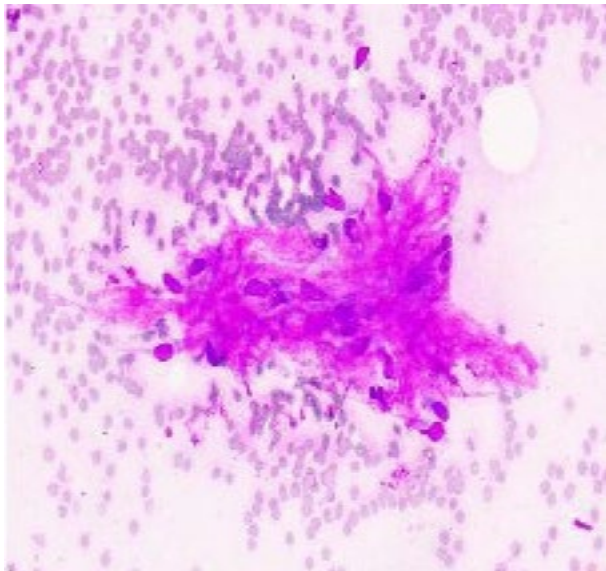
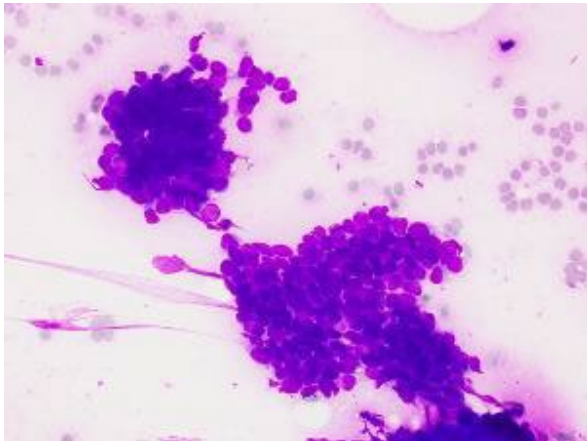


Note: All images are subject to copyright and are only for personal use, and not for sharing or distribution.

### **Case 3**

#### **A parotid Lump**

**Clinical History:** A 72 year old male. Left parotid mass.



Note: All images are subject to copyright and are only for personal use, and not for sharing or distribution.