



International Academy of Pathology Master Class Cytology Exam

Associate Professor Elizabeth Salisbury

Clinical Director

Department of Tissue Pathology and Diagnostic Oncology, ICPMR,
Westmead Hospital



What is the expected range of cases?

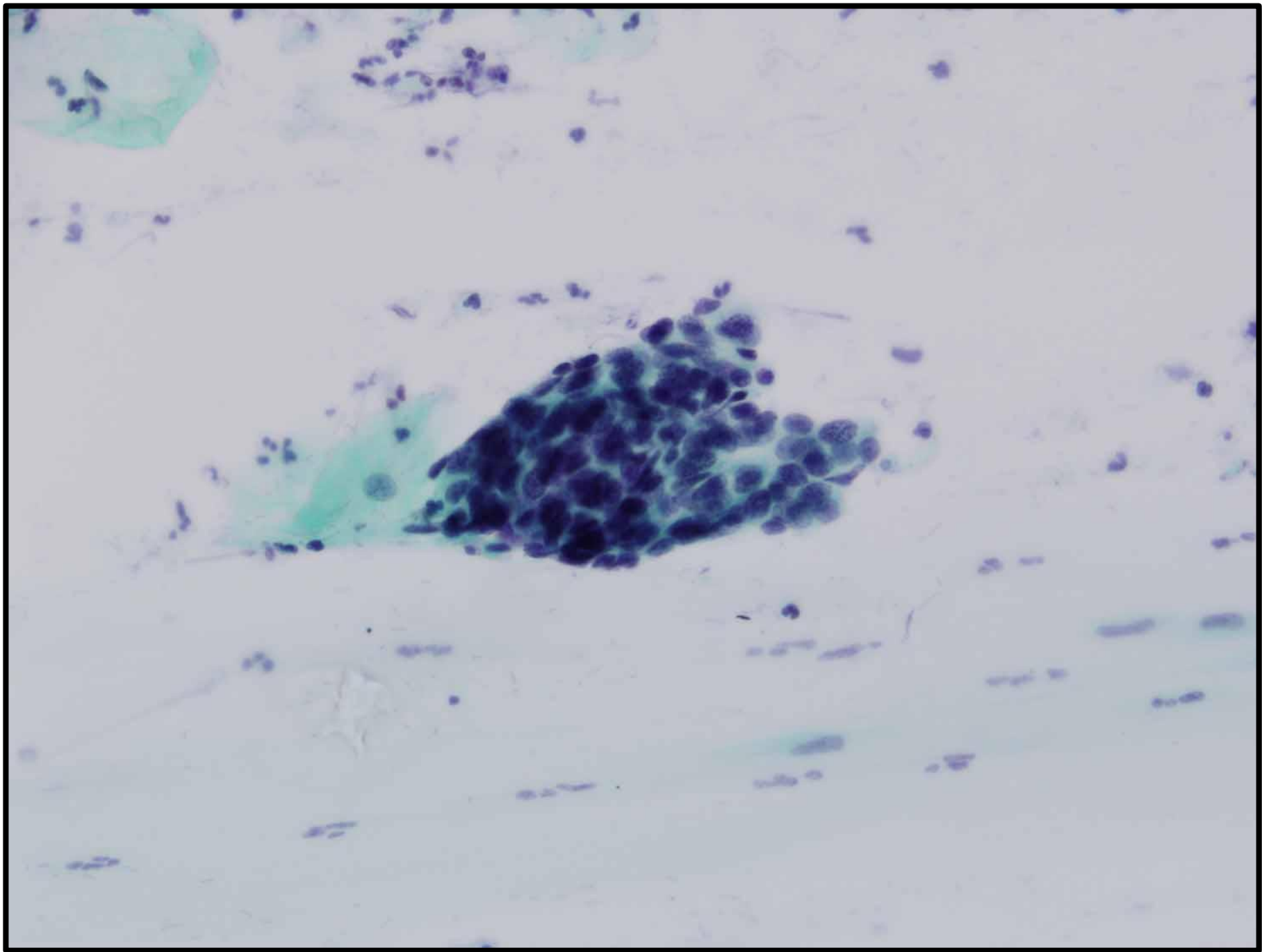
- ▶ ***If you can scrape it, drain it, collect it or stick a needle in it – it may appear in exam***
- ▶ All body fluids (eg. CSF, pericardial, pleural, ascitic, joint, urine, sputum)
- ▶ All body surfaces (eg, oral cavity, peritoneum, cervix, vagina/vulva, bronchi)
- ▶ All solid organs (eg. Liver, lung, kidney, lymph nodes, thyroid, thymus, pancreas, brain)
- ▶ All superficial lumps and bumps (incl breast, salivary glands, soft tissues, skin, cysts)

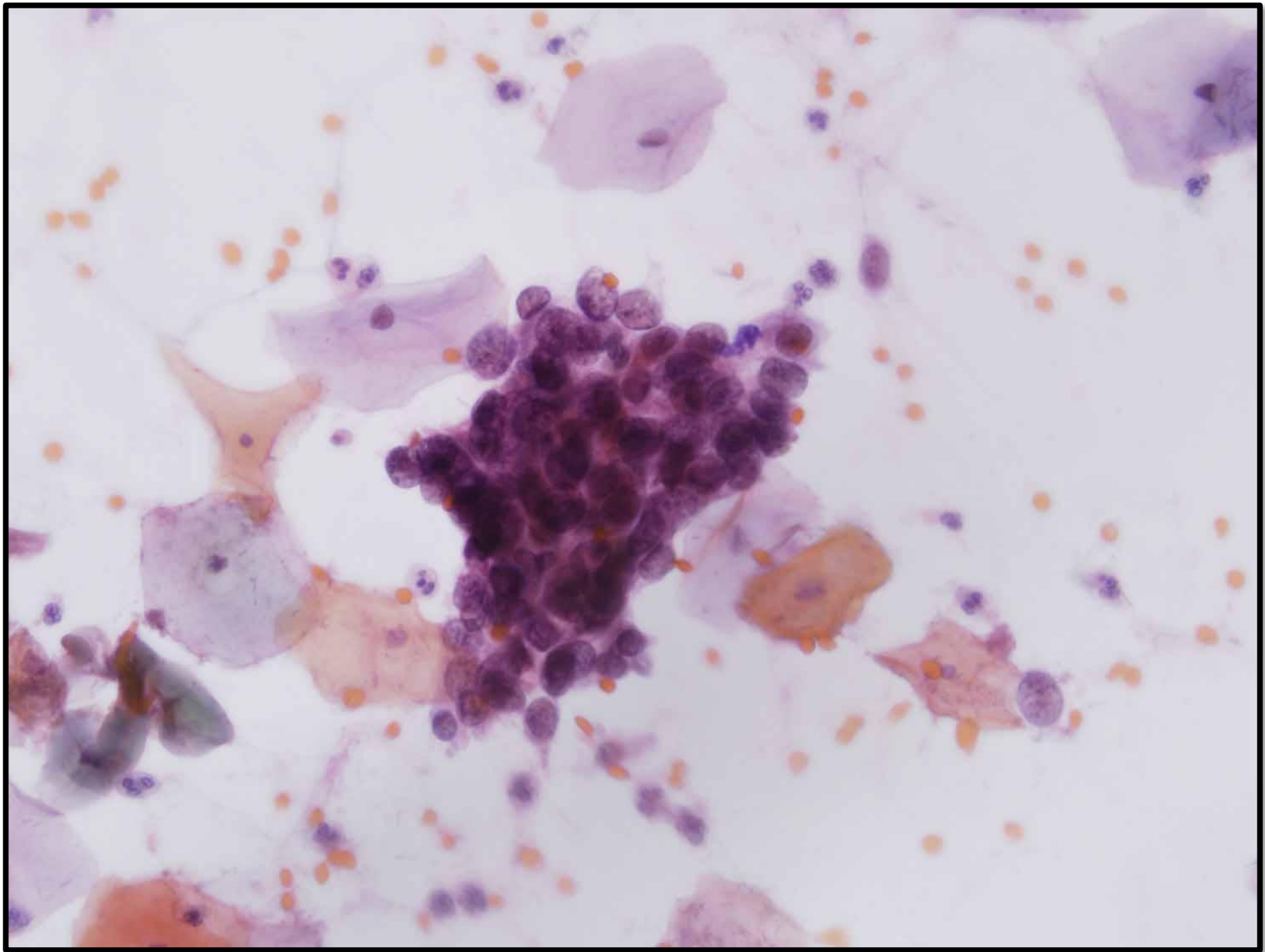
Summary

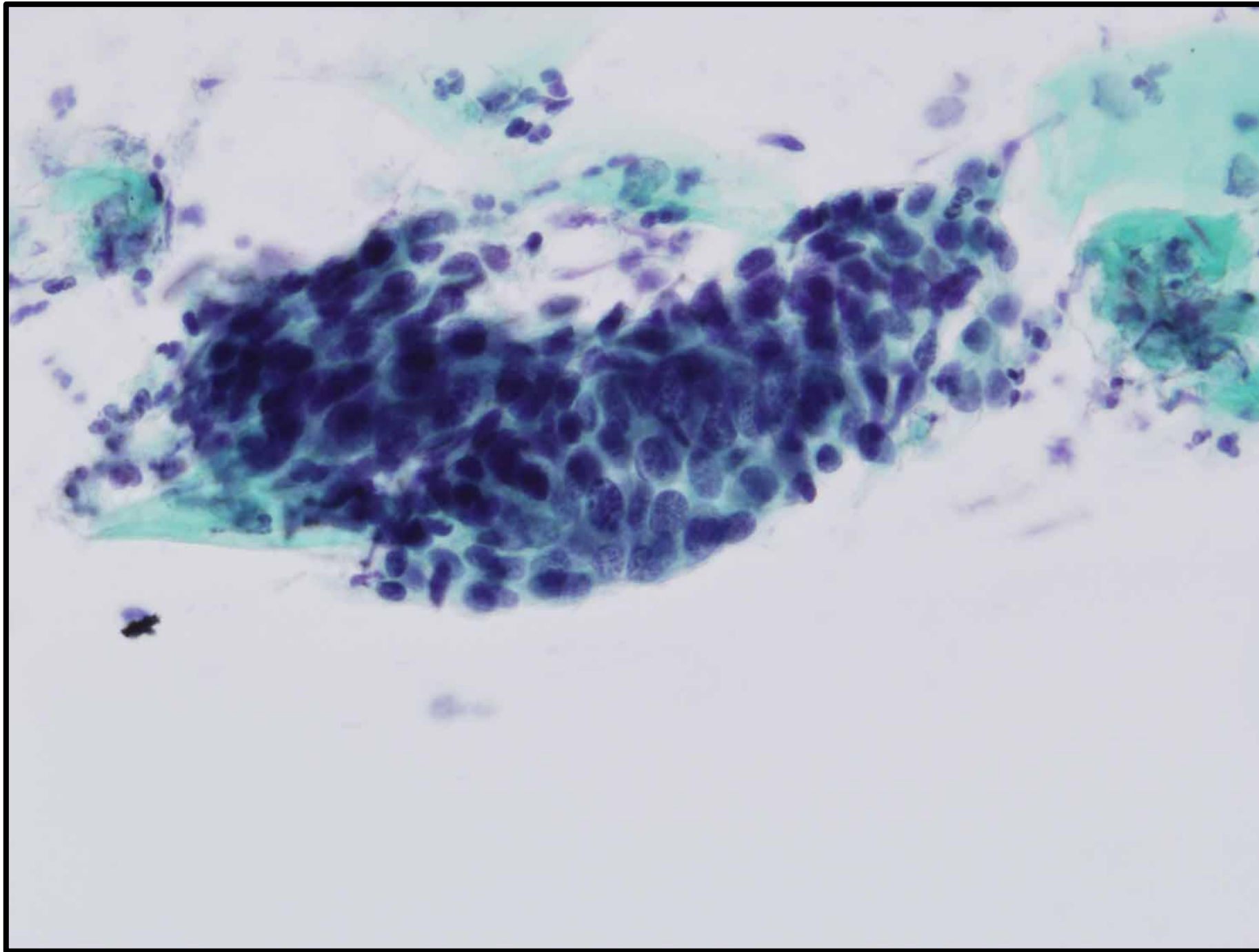
- Be mindful of correct terminology
- Be logical – Is it normal tissue? Is it inflammatory? Can I see any organisms? Is it neoplastic (primary v secondary)? Can I match the cyto features to my knowledge of histo?
- Remember ancillary tests (IPX, Flow Cytometry, Cytogenetics, EM)
- State your preferred diagnosis clearly
- Look at as many real cases as you can and look at the pictures in cyto books and on line

Case 1

F39. Post coital bleeding. LBC

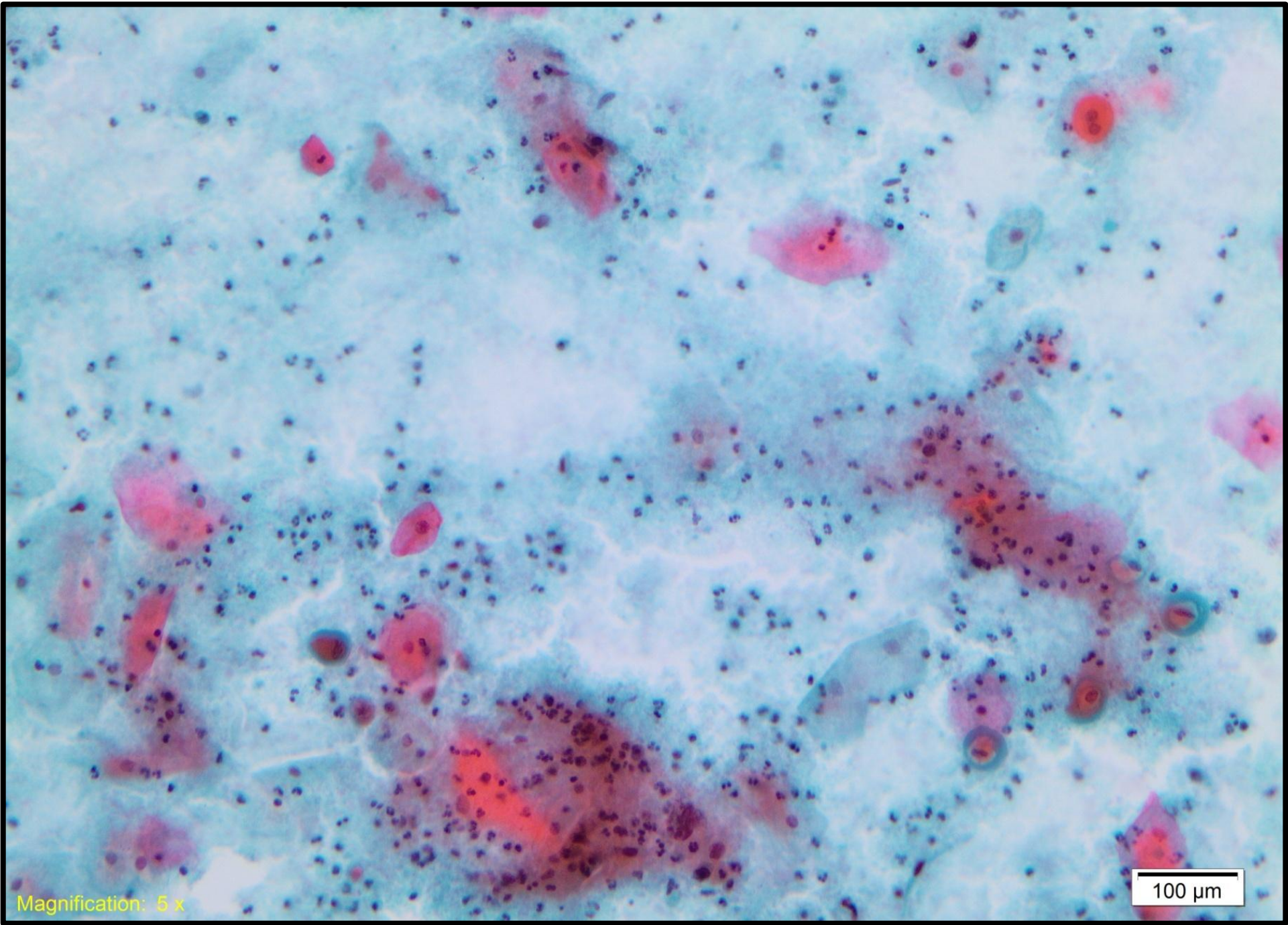






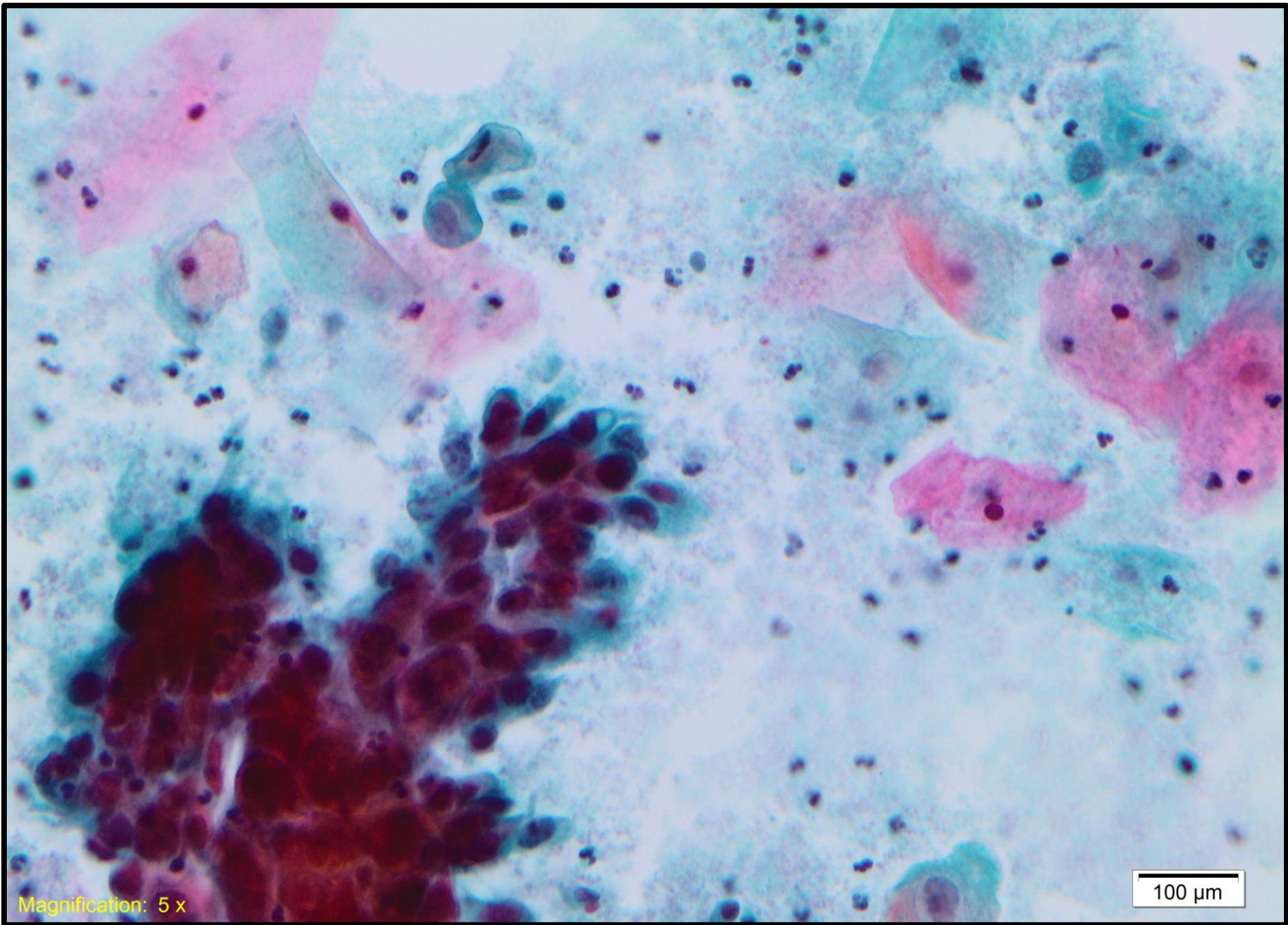
Case 2

F70. Vaginal discharge. Never had pap smear.



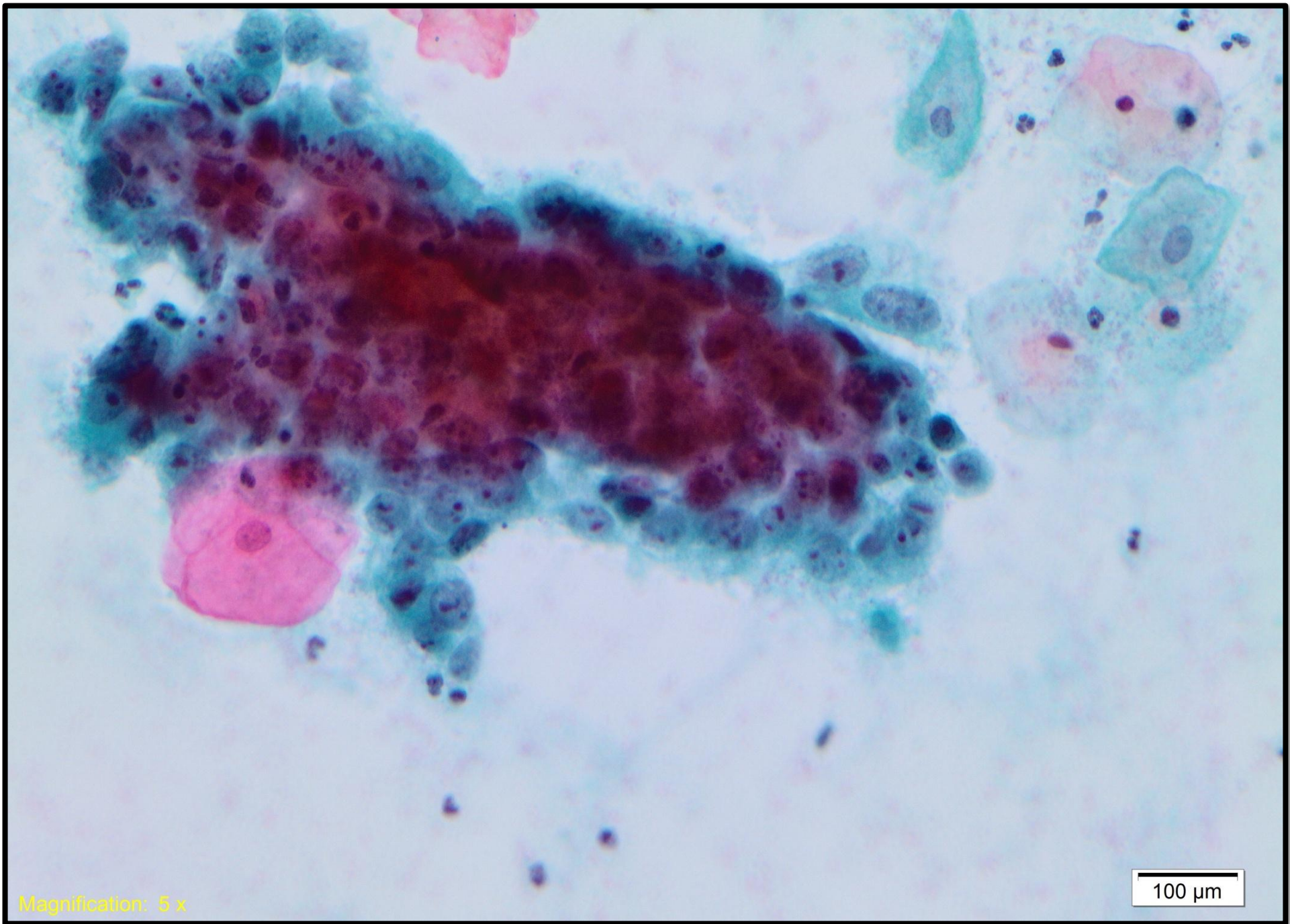
Magnification: 5 x

100 μ m



Magnification: 5 x

100 μm

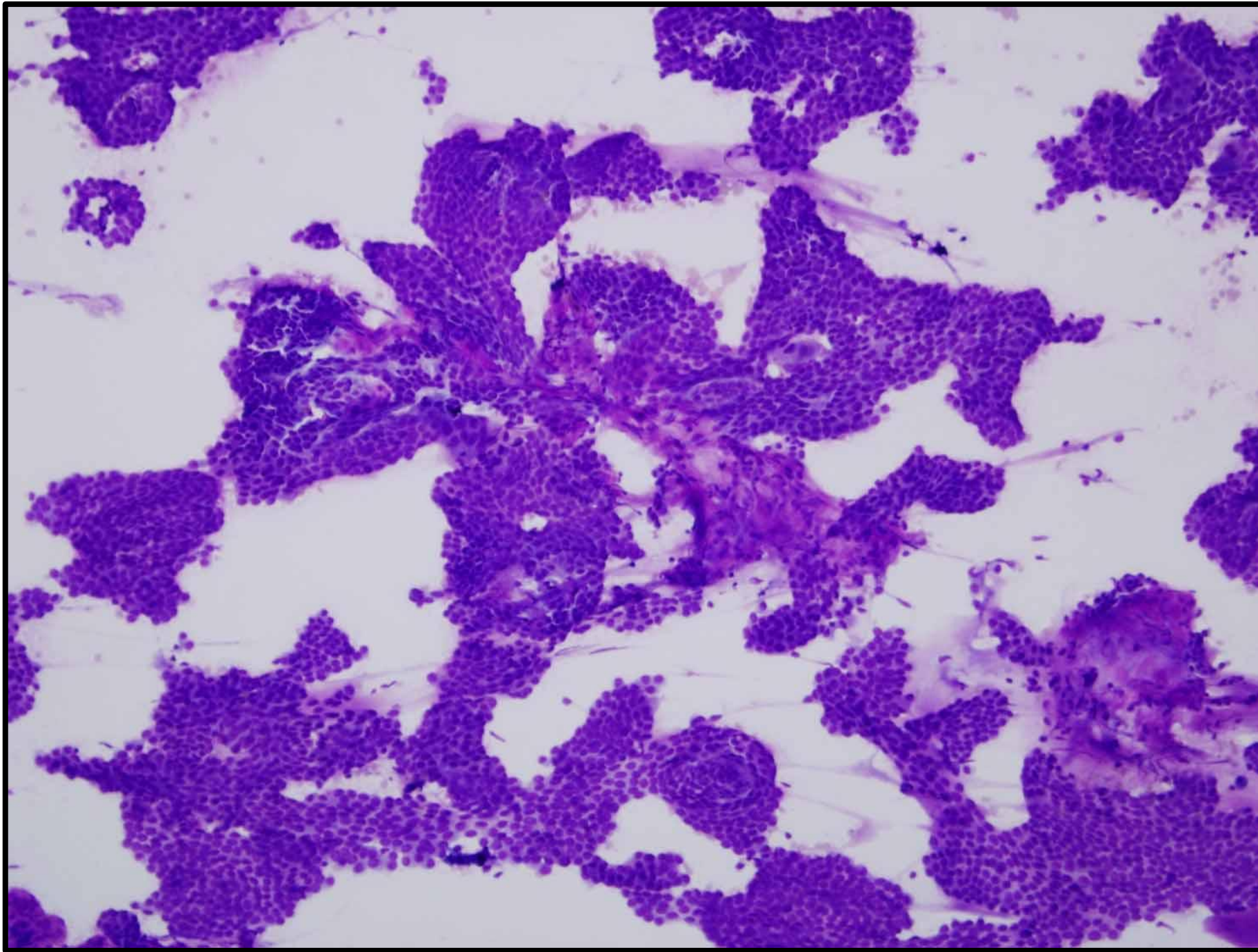


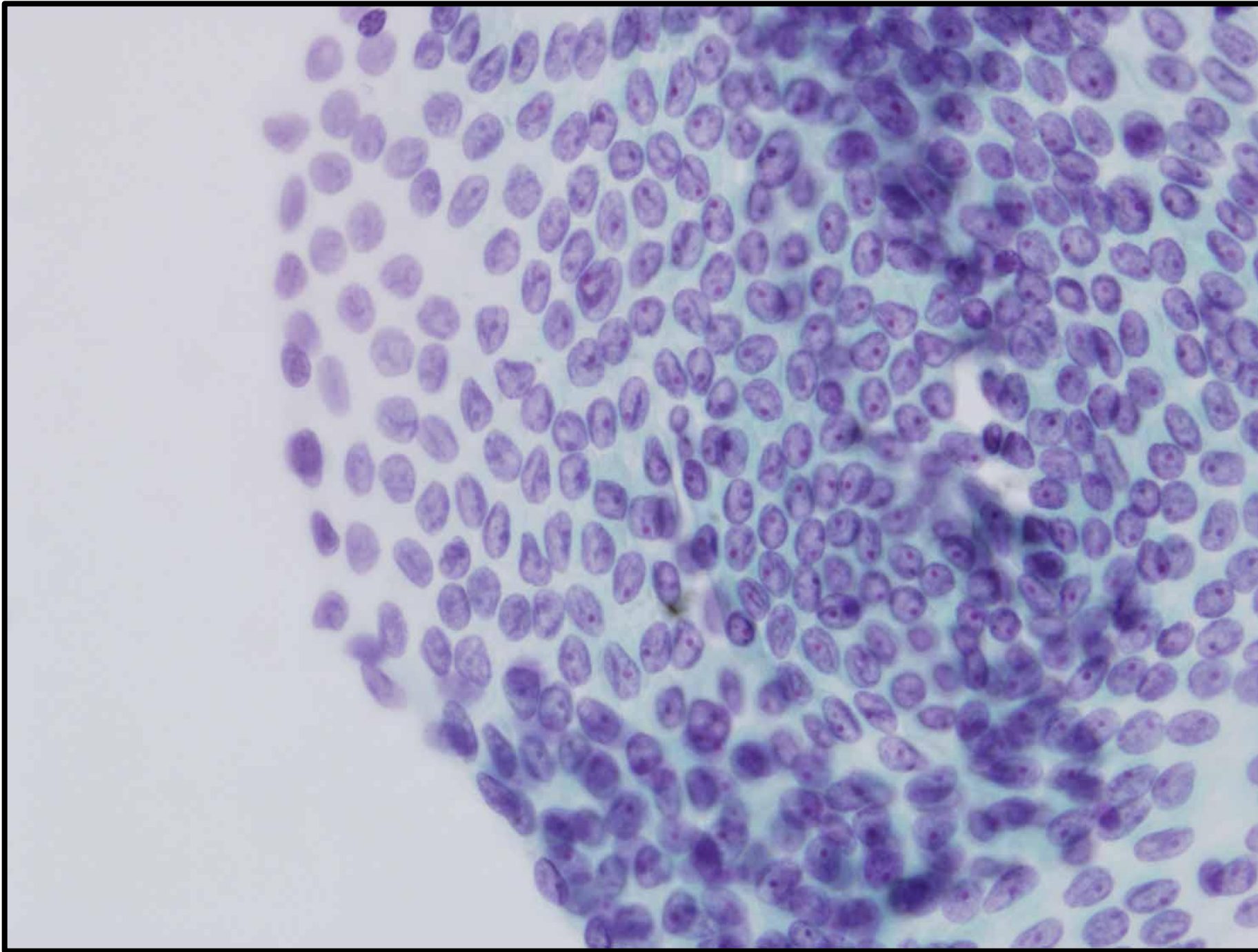
Magnification: 5 x

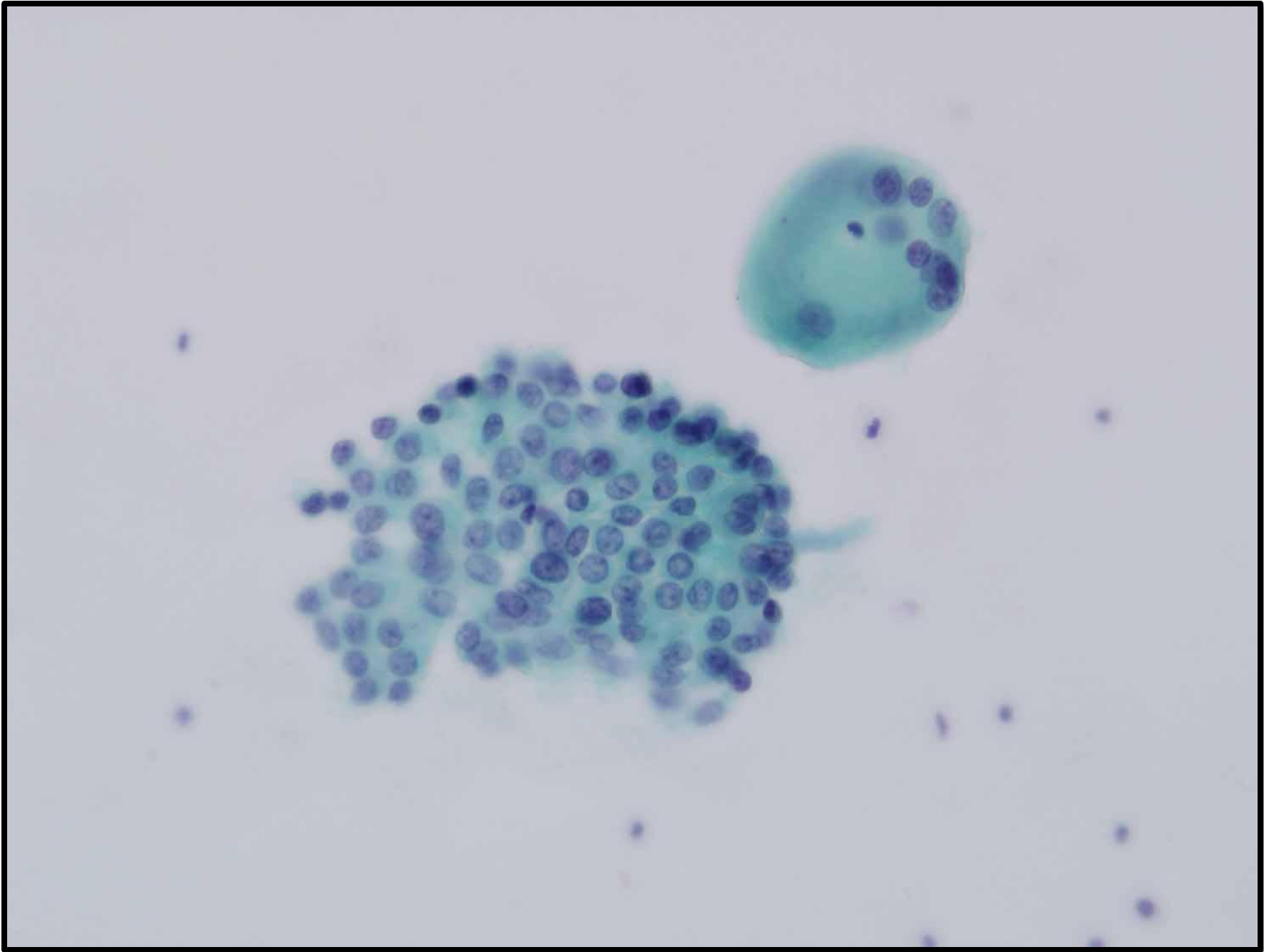
100 μ m

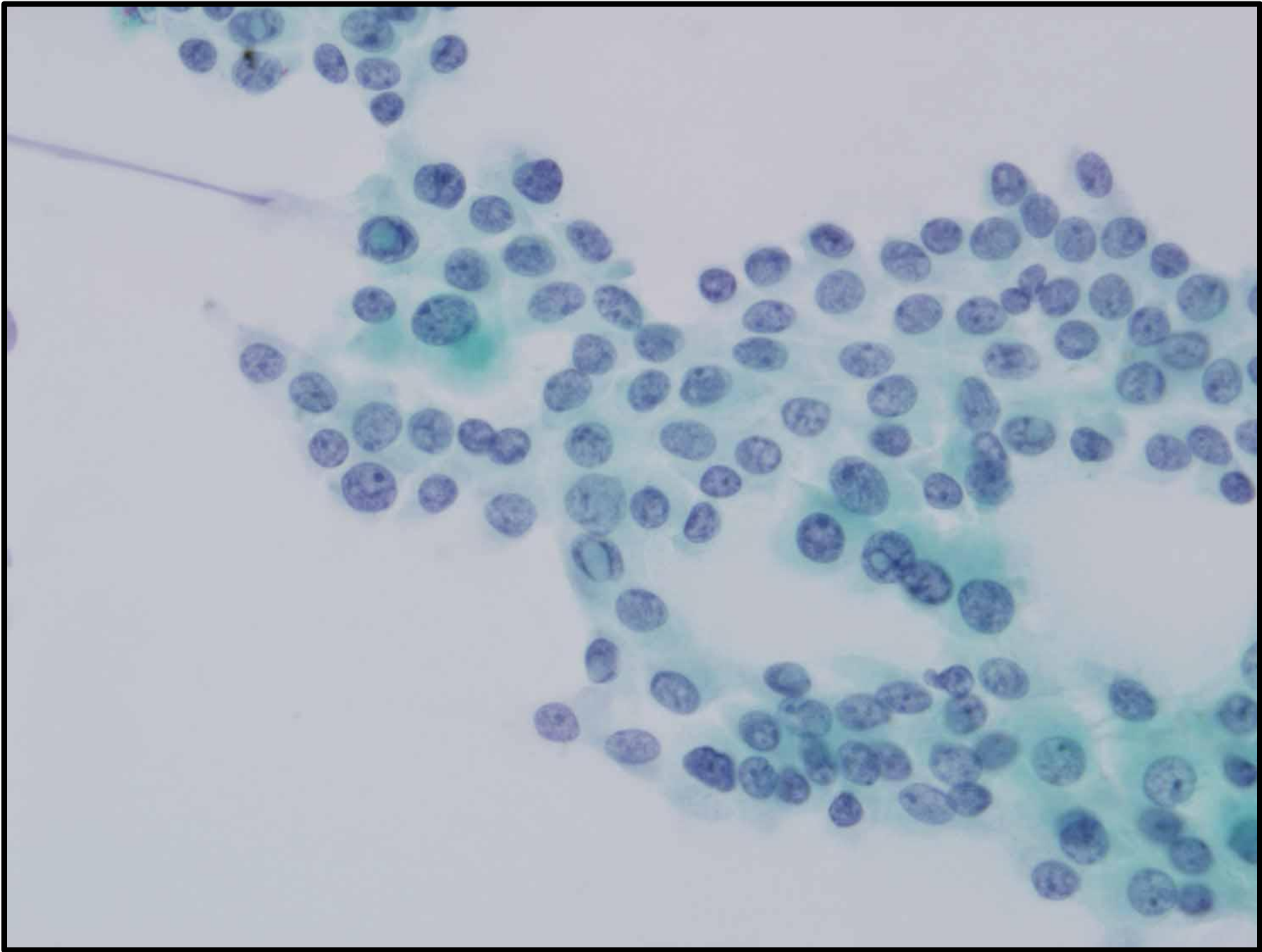
Case 3

F25. FNA Thyroid.



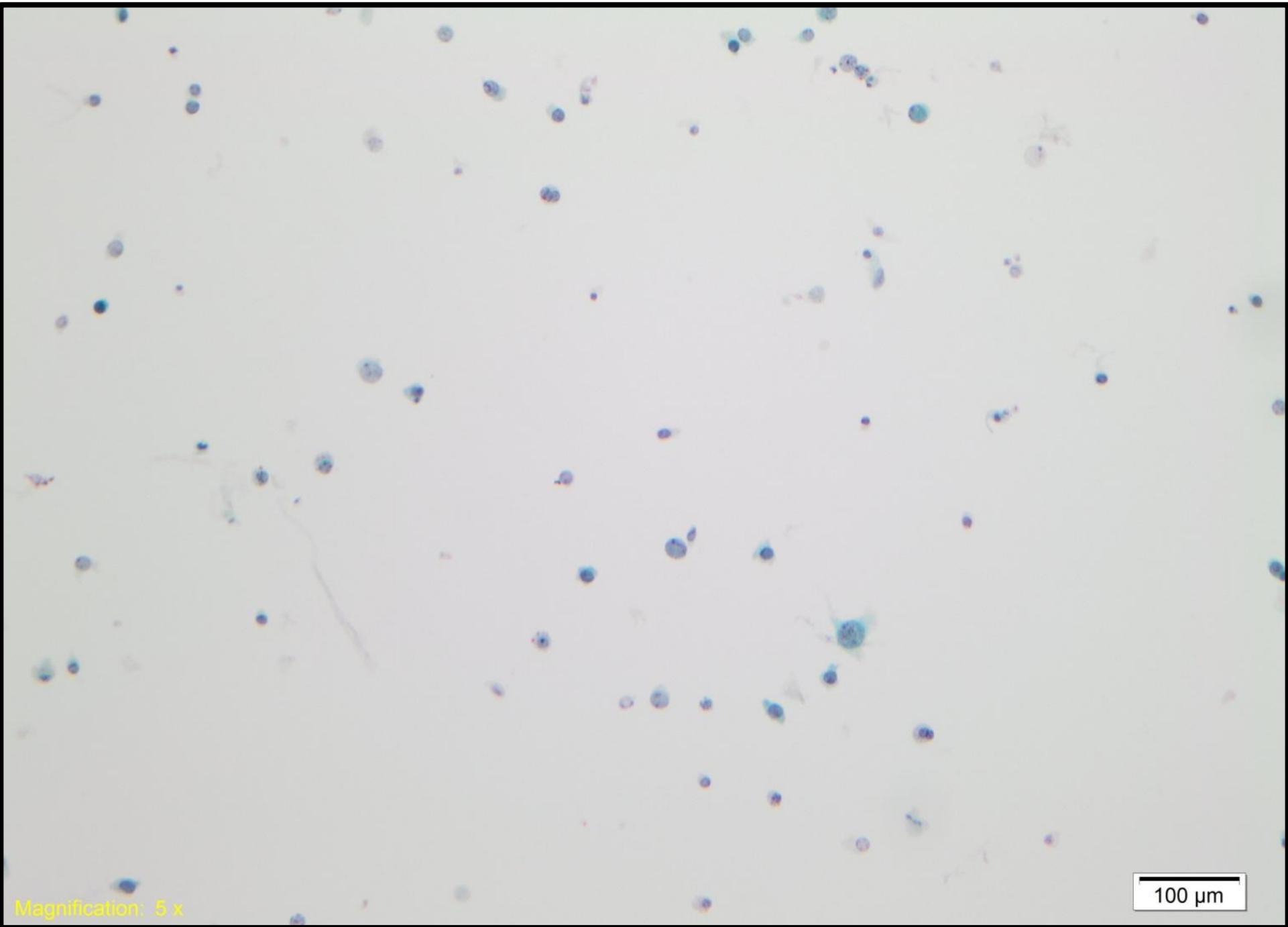





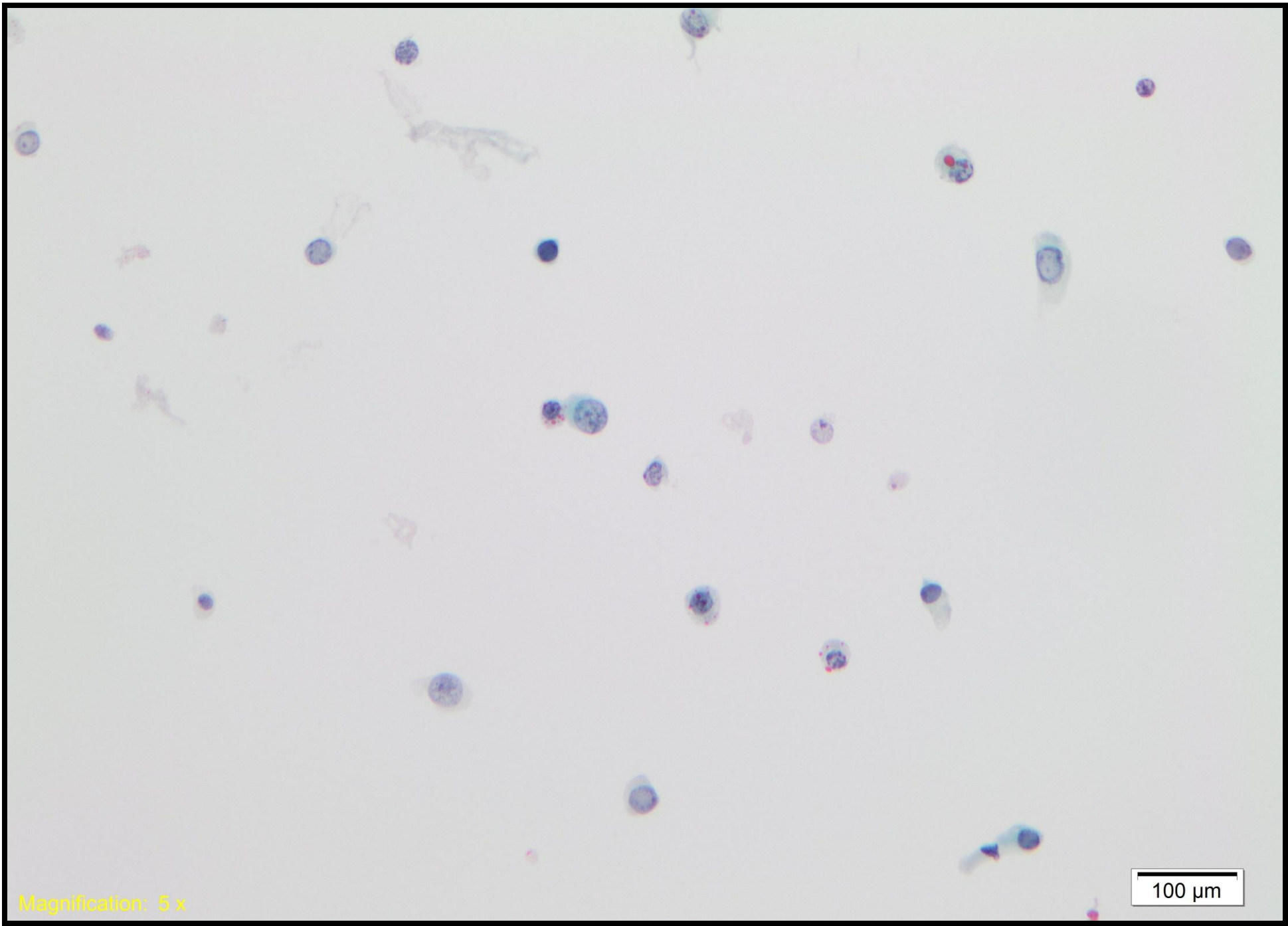
Case 4

M50. Renal transplant. Urine.



Magnification: 5 x

100 μm

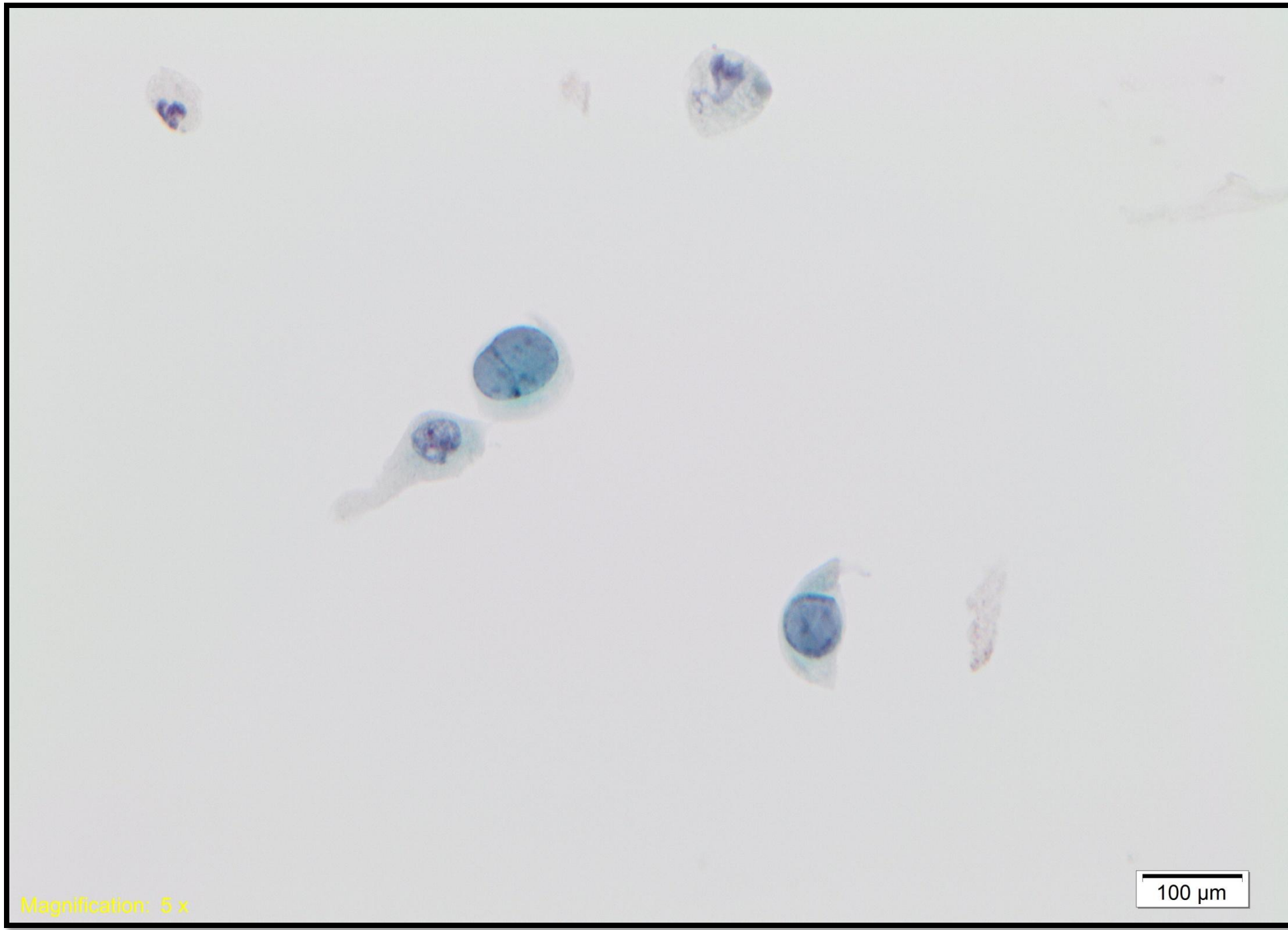


Magnification: 5 x

100 μm

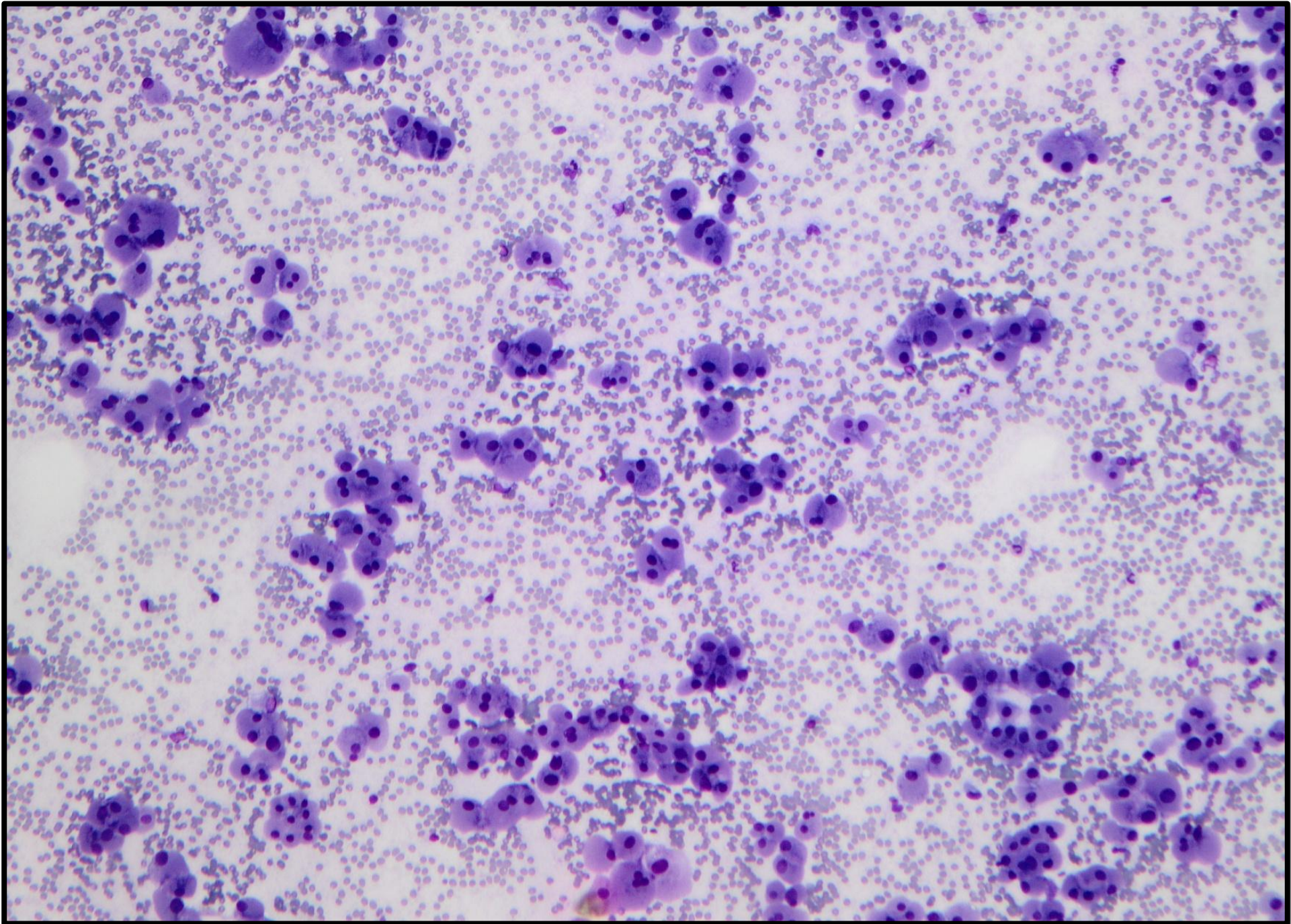
Magnification: 5 x

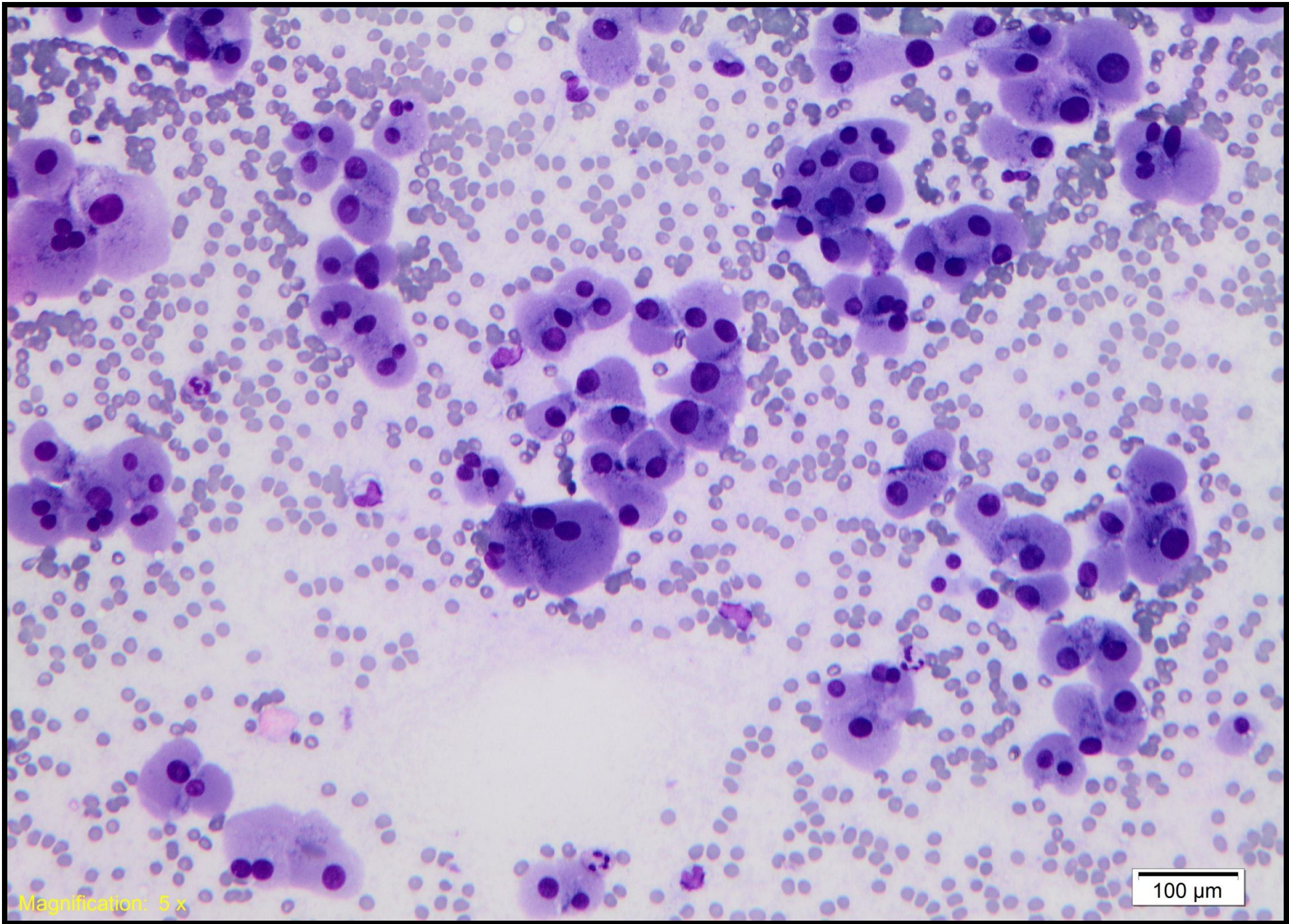
100 μ m



Case 5

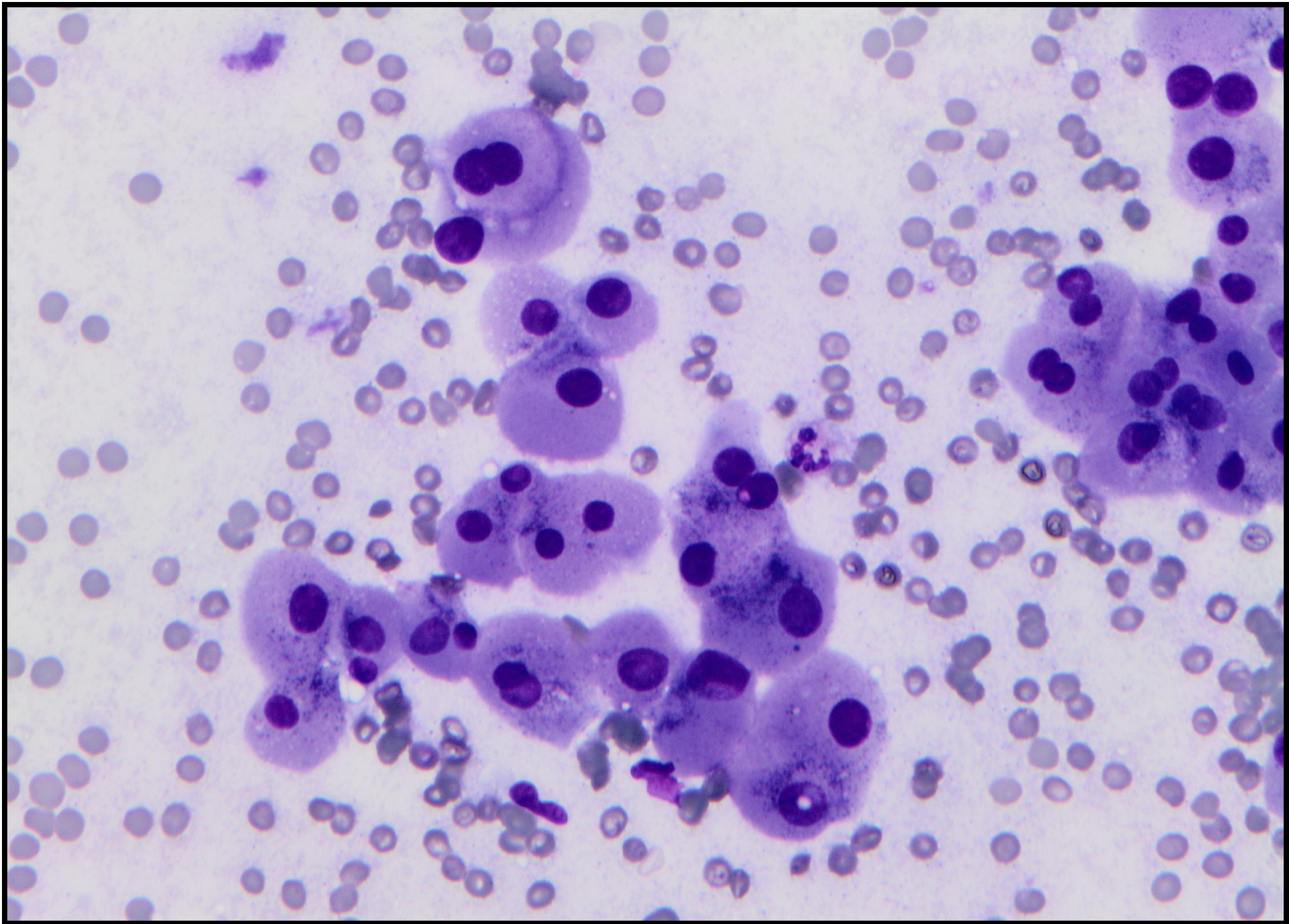
F60. FNA Thyroid

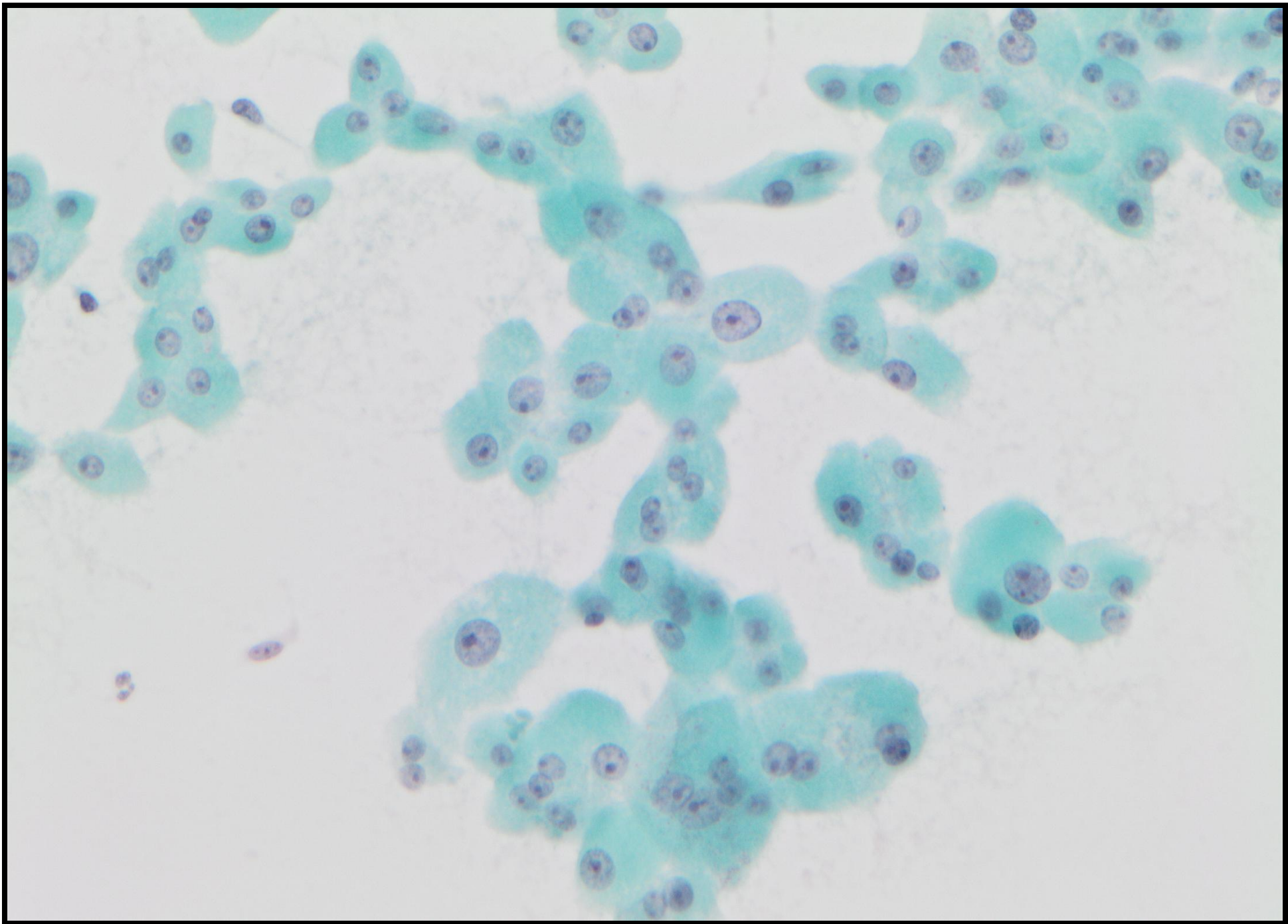




Magnification: 5 x

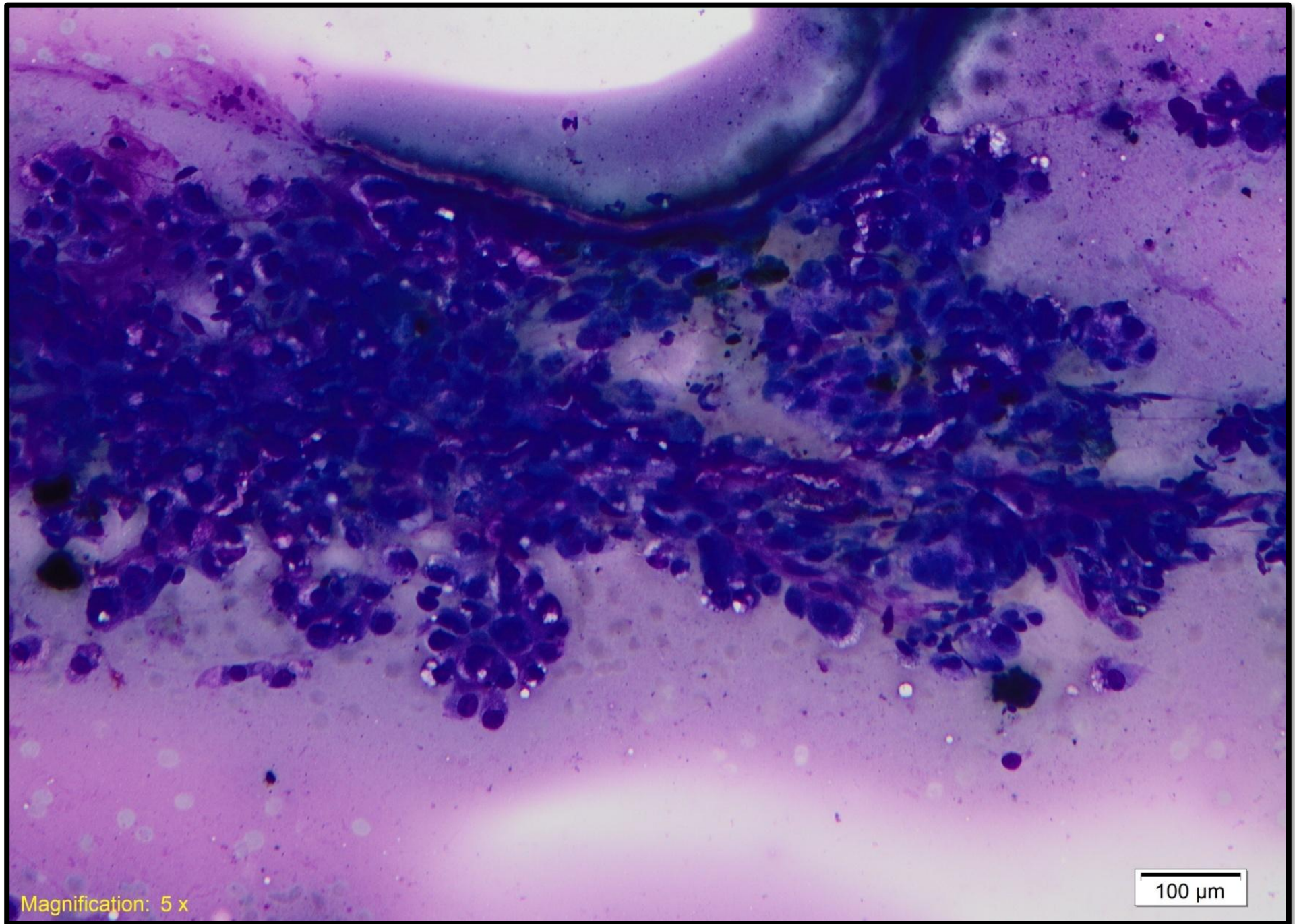
100 μm





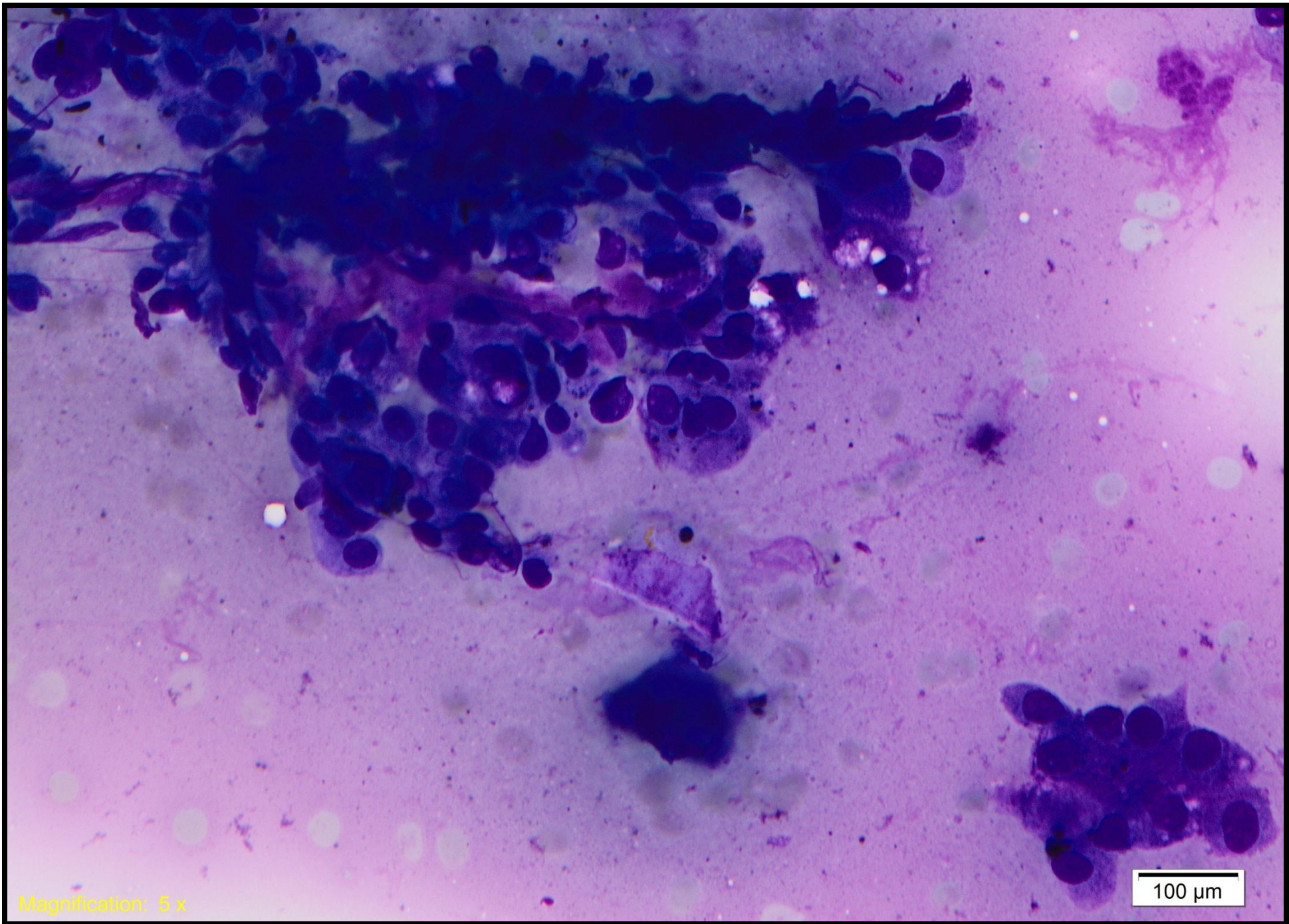
Case 6

M65. Cirrhosis. FNA Liver mass.



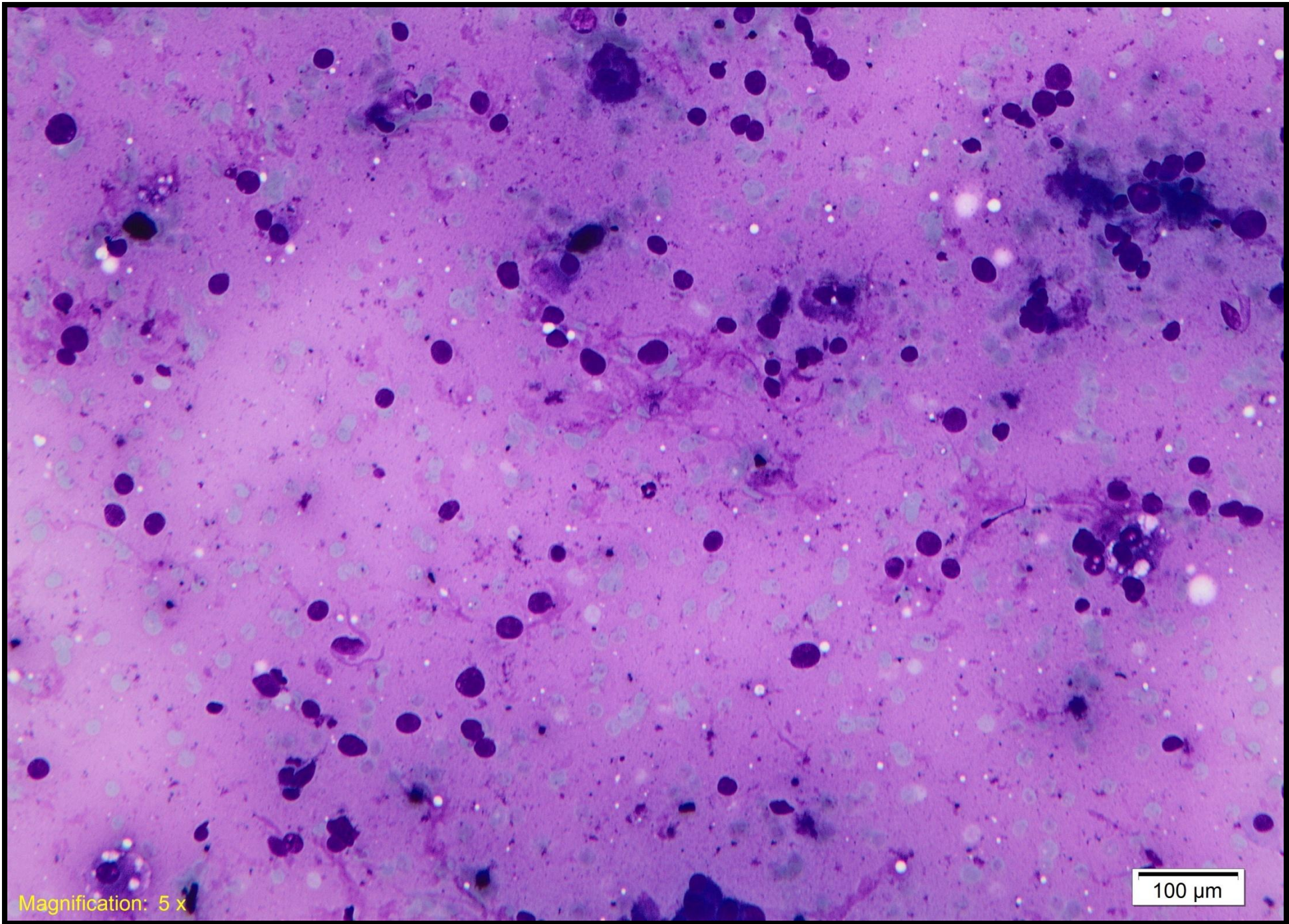
Magnification: 5 x

100 μm



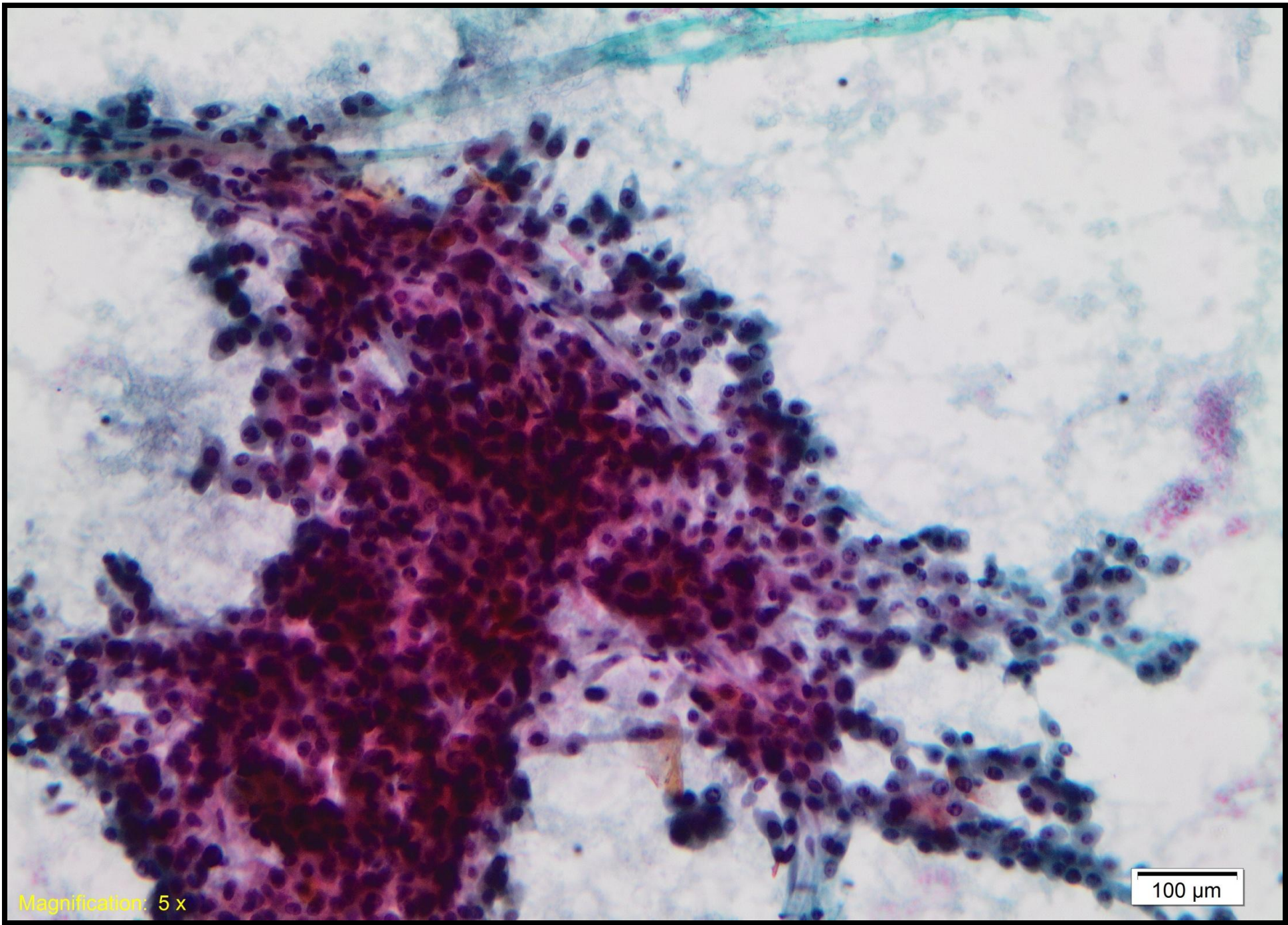
Magnification: 5 x

100 μm



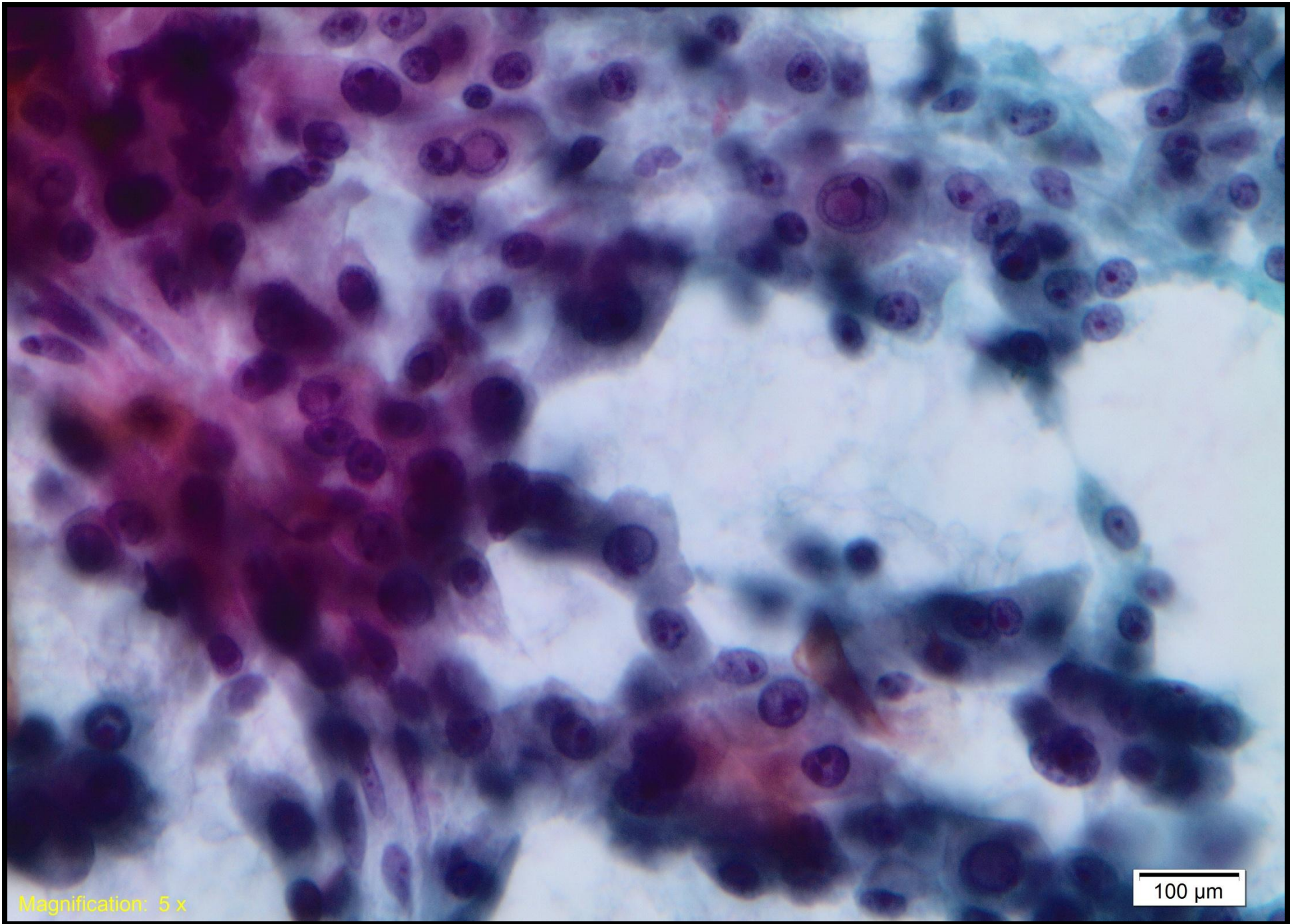
Magnification: 5 x

100 μ m



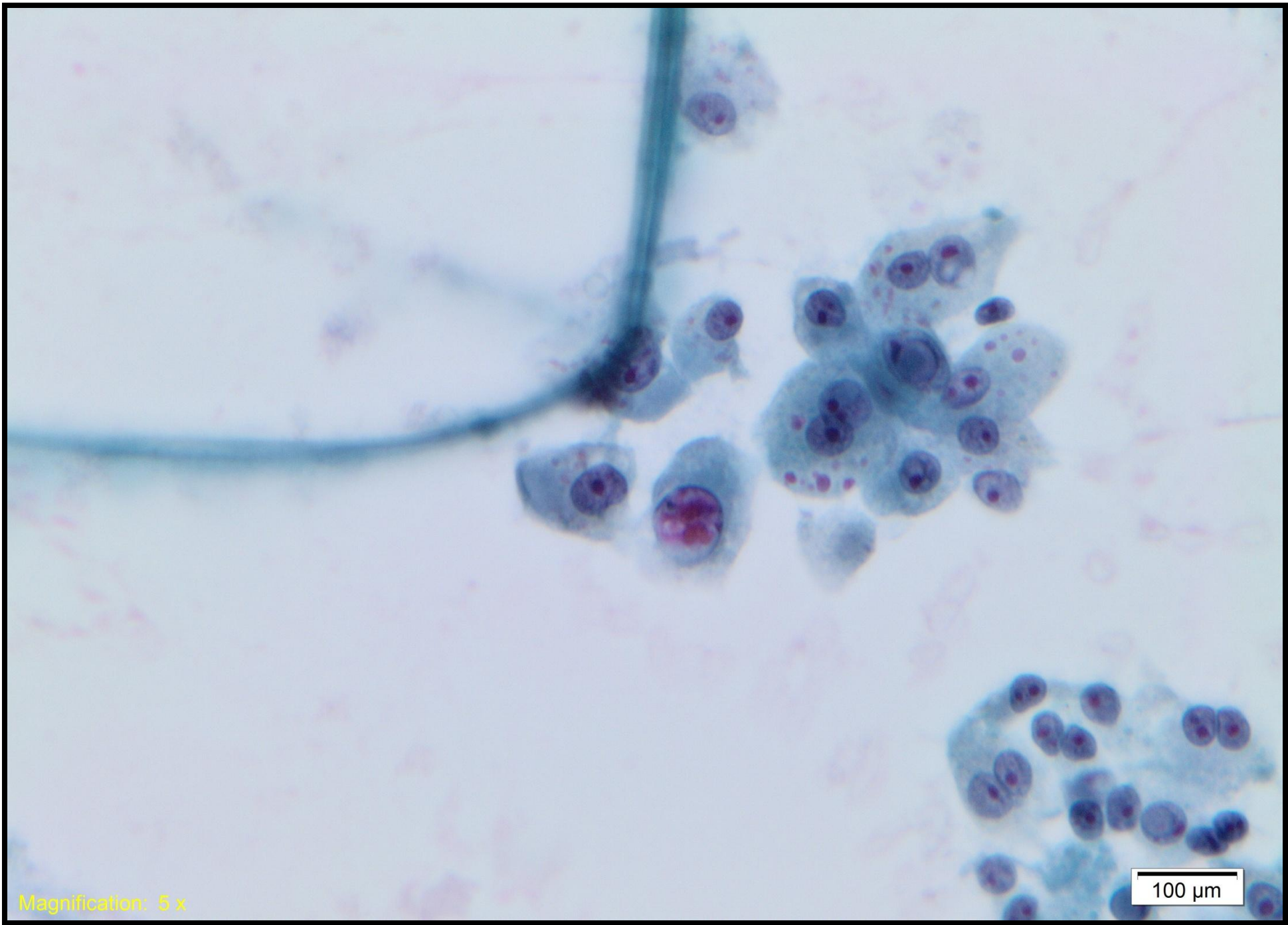
Magnification: 5 x

100 μm



Magnification: 5 x

100 μ m

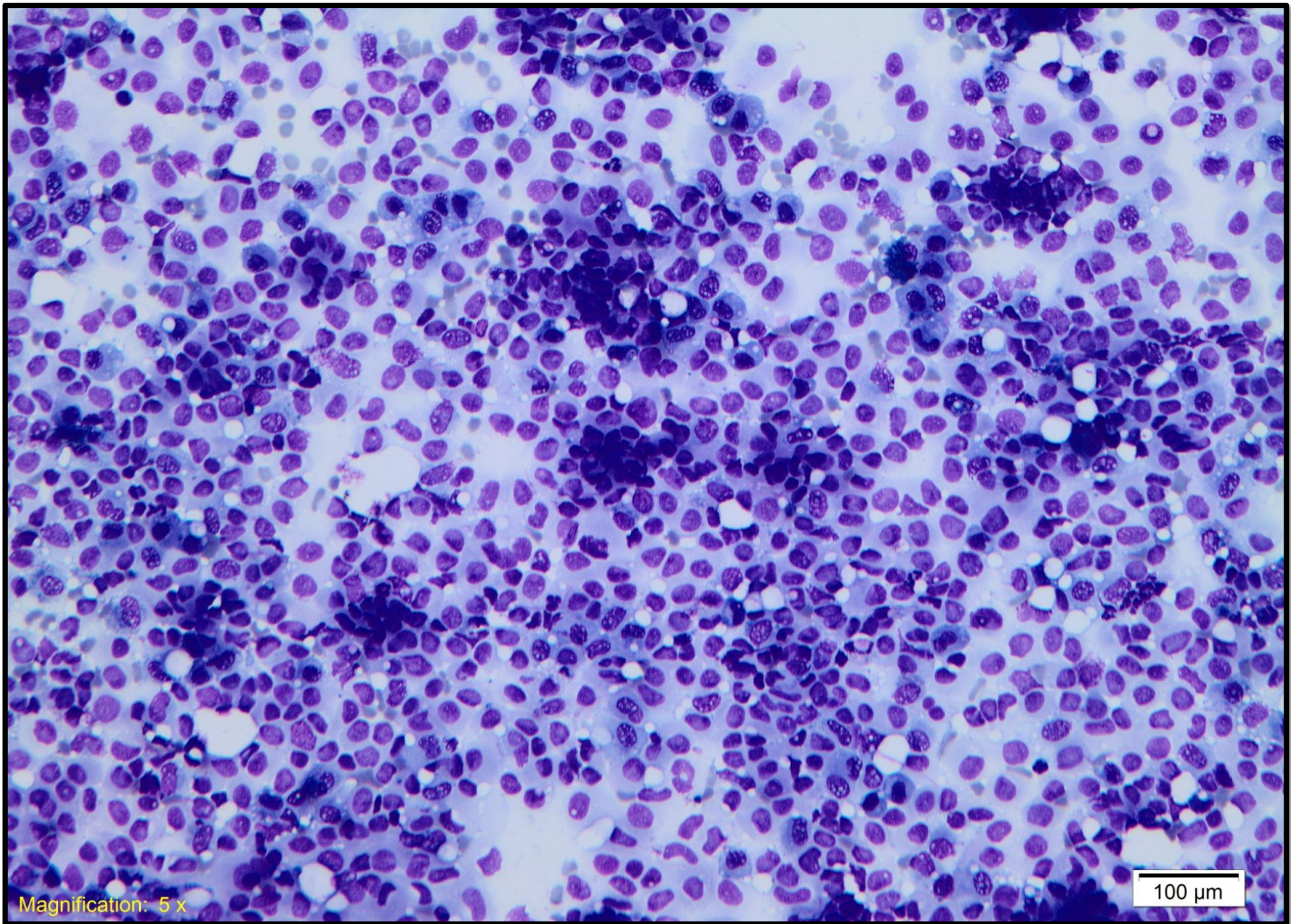


Magnification: 5 x

100 μ m

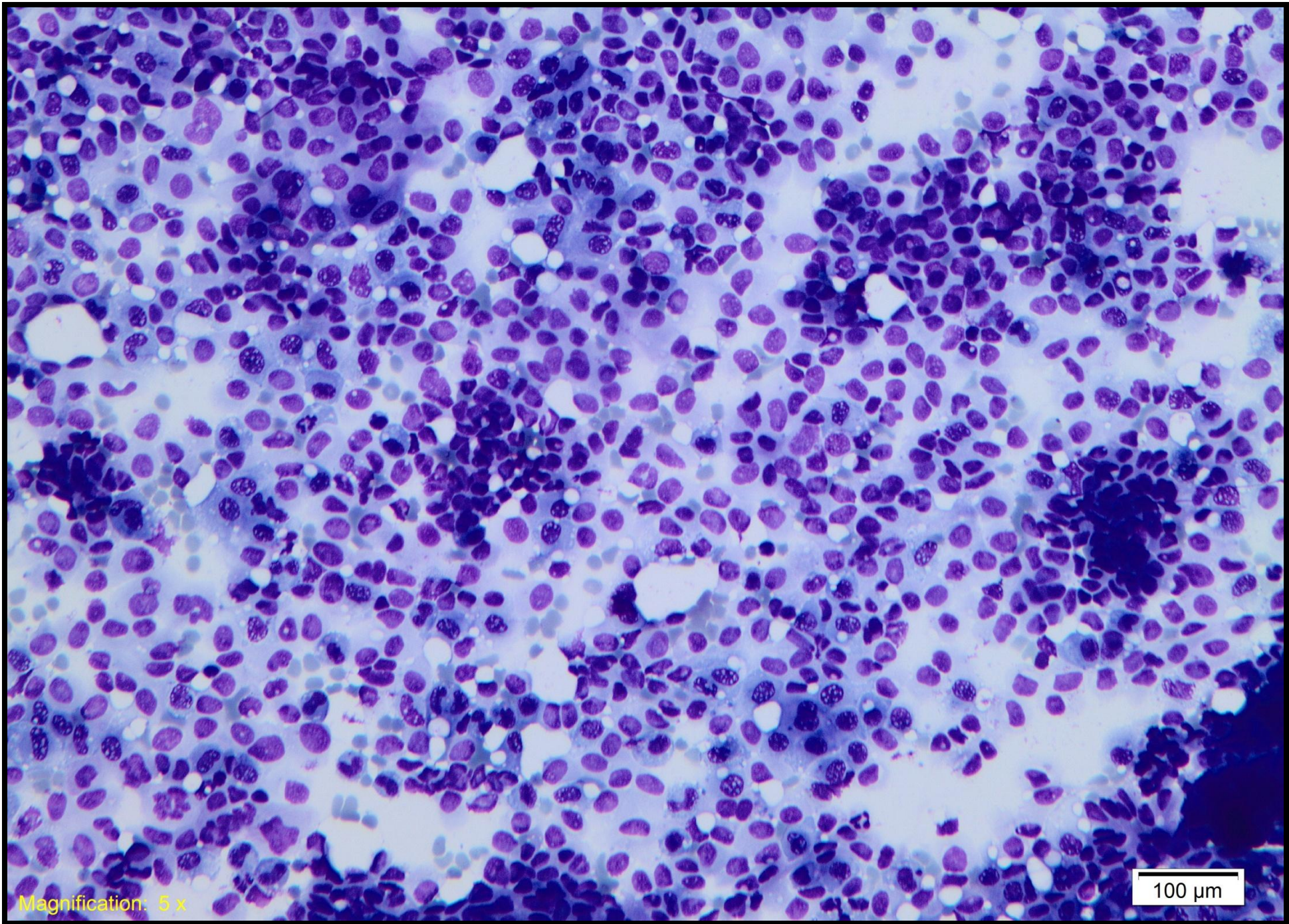
Case 7

F45. Peritoneal Washings at time of hysterectomy.



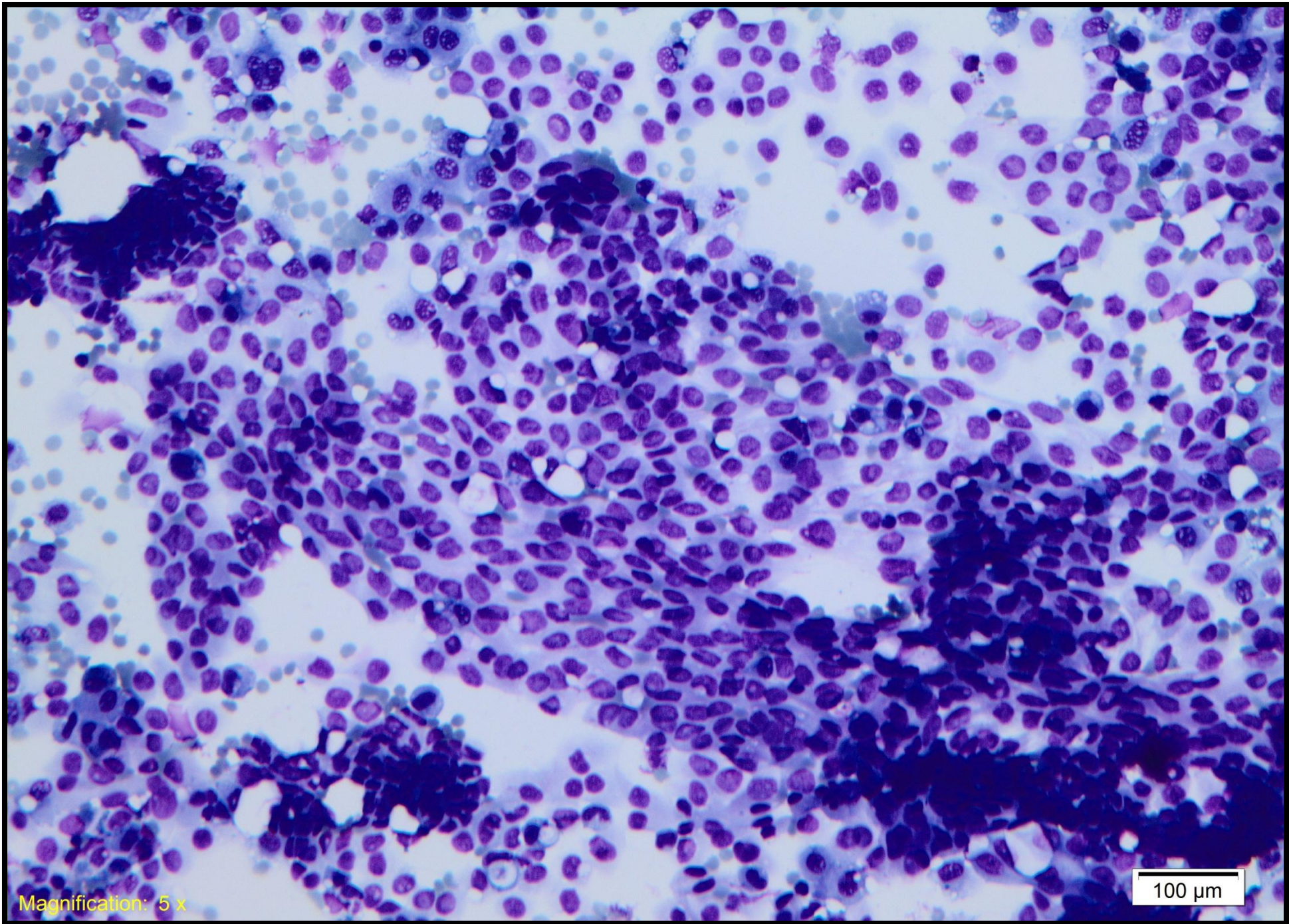
Magnification: 5 x

100 μ m



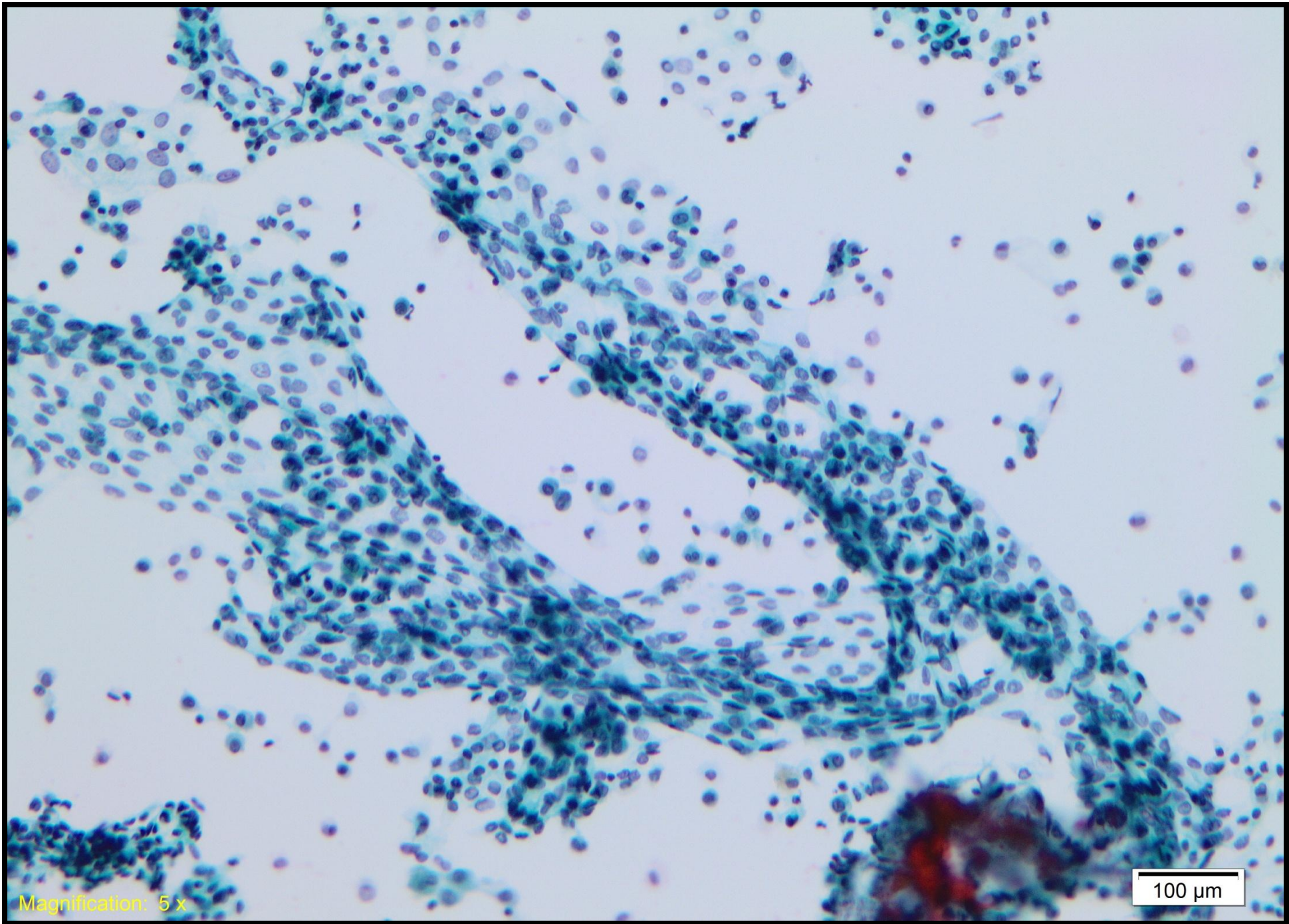
Magnification: 5 x

100 μm



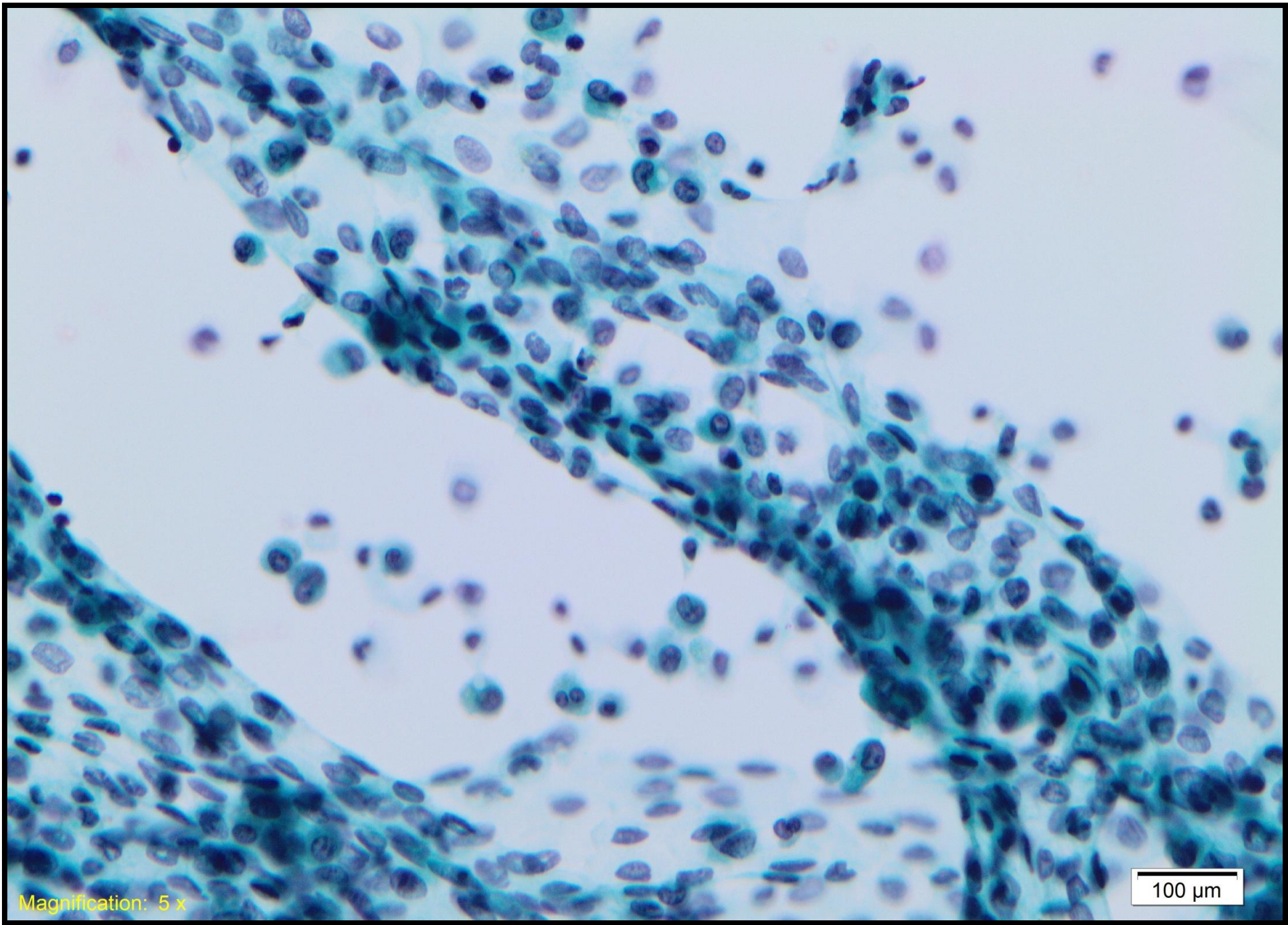
Magnification: 5 x

100 μ m



Magnification: 5 x

100 μm

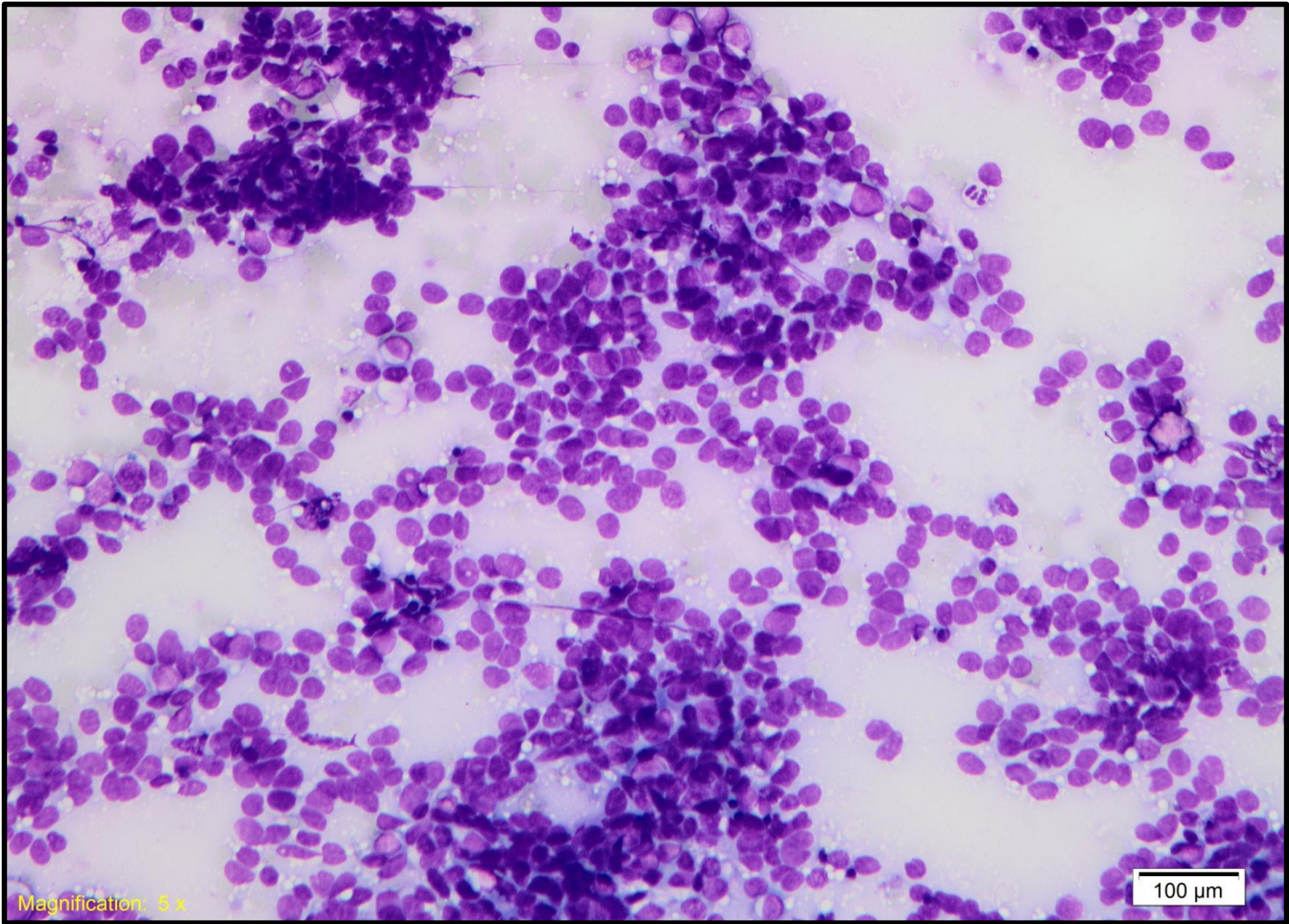


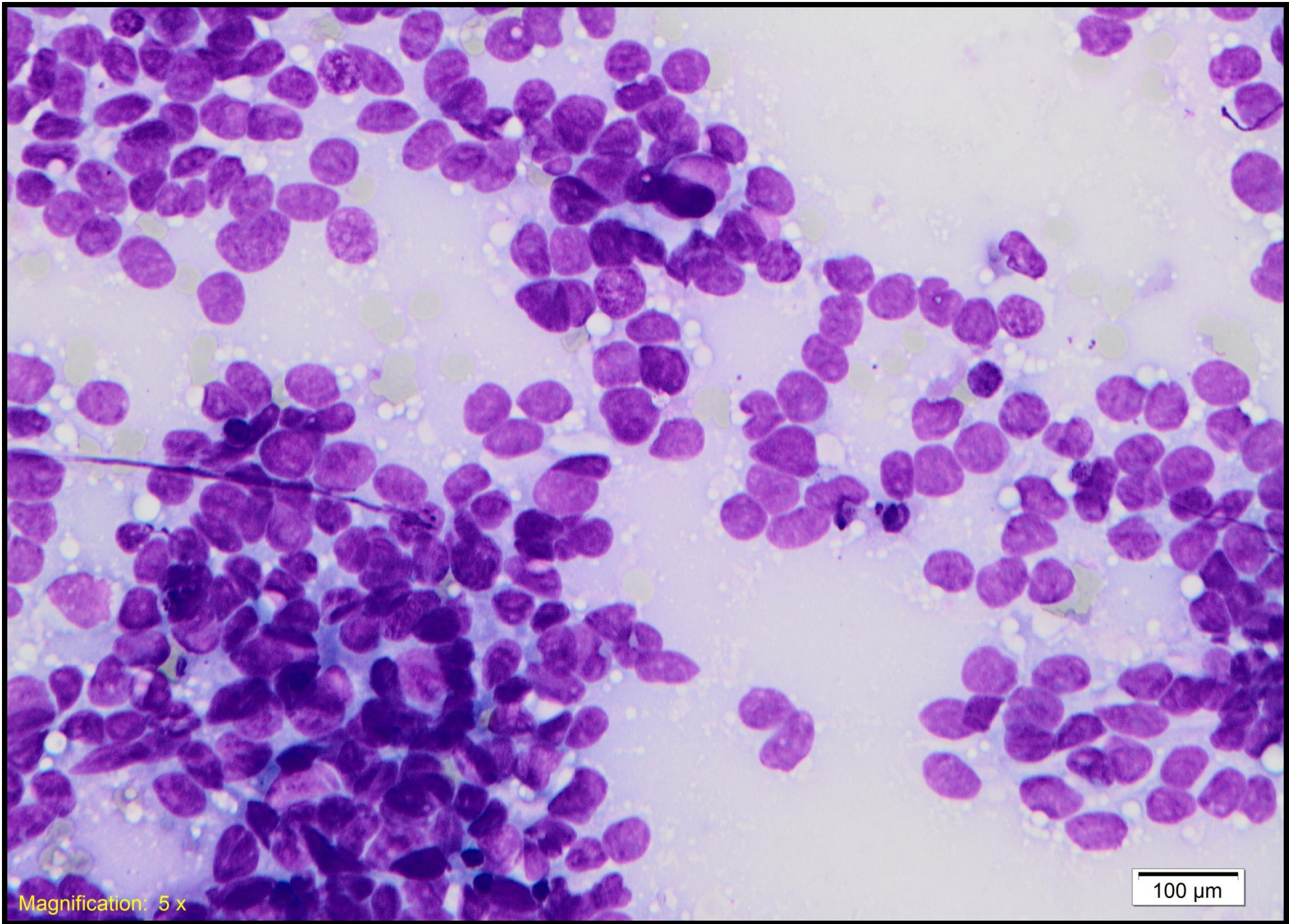
Magnification: 5 x

100 μm

Case 8

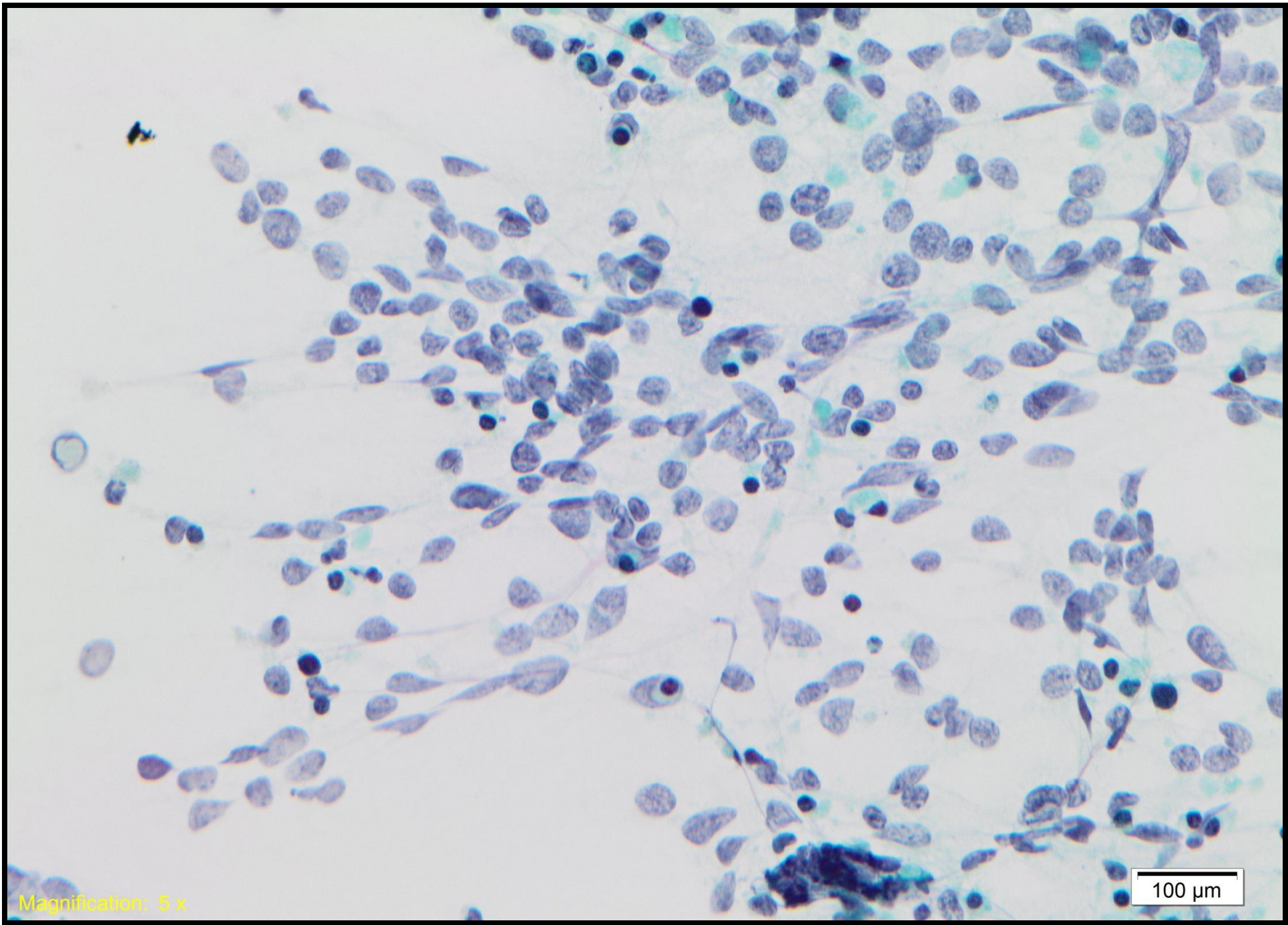
M75. EBUS FNA enlarged hilar LN





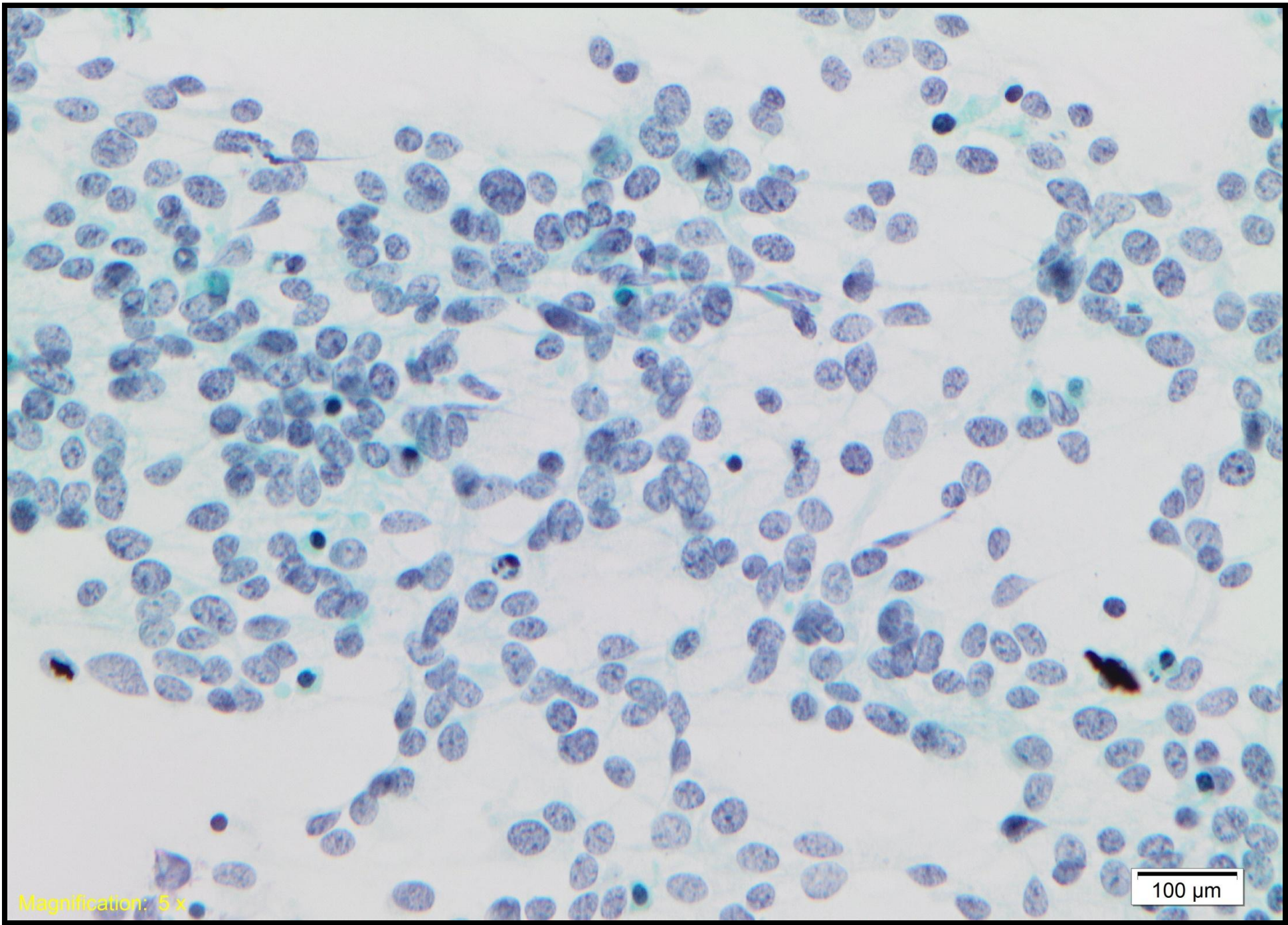
Magnification: 5 x

100 μm



Magnification: 5 x

100 μm

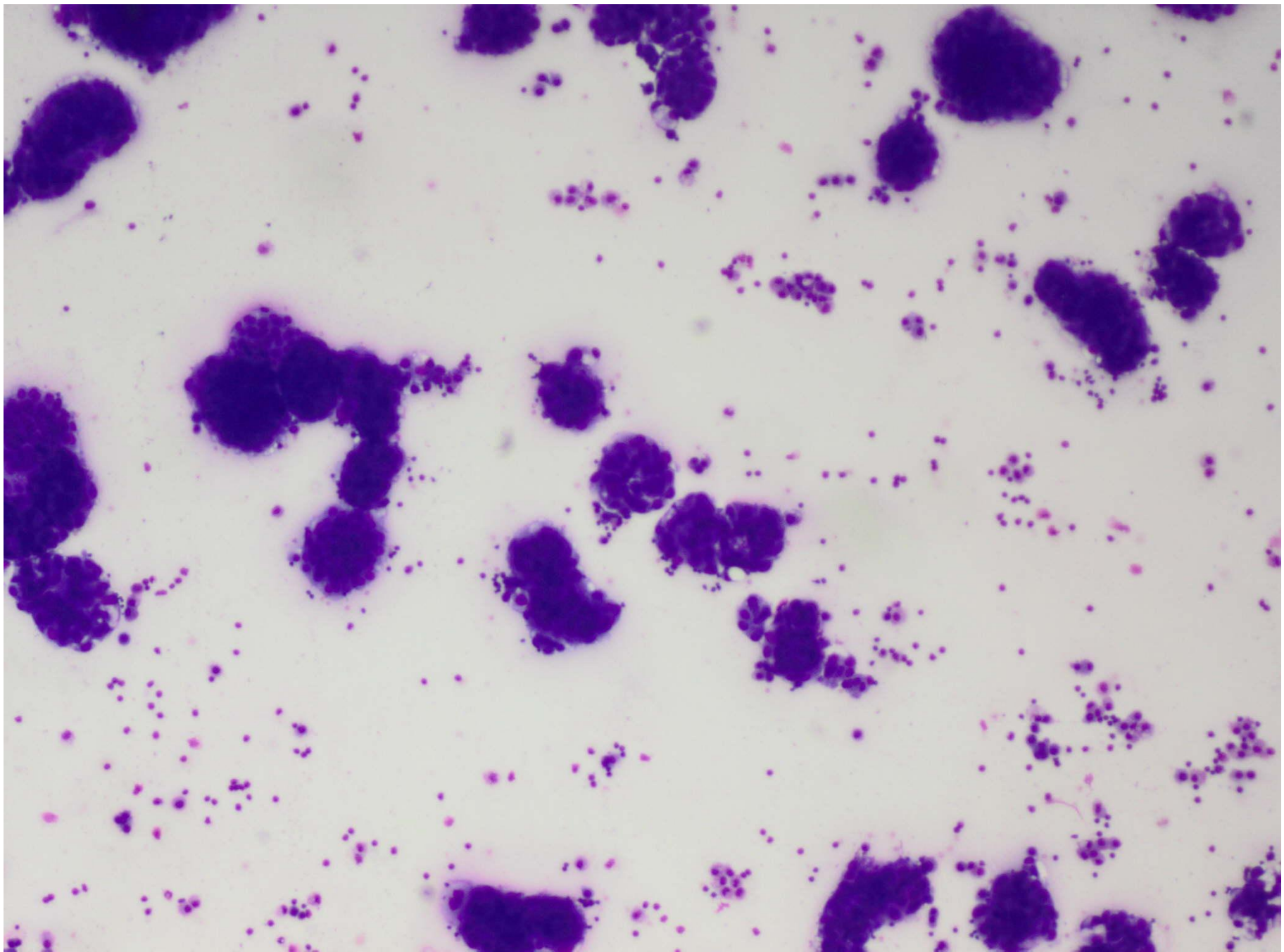


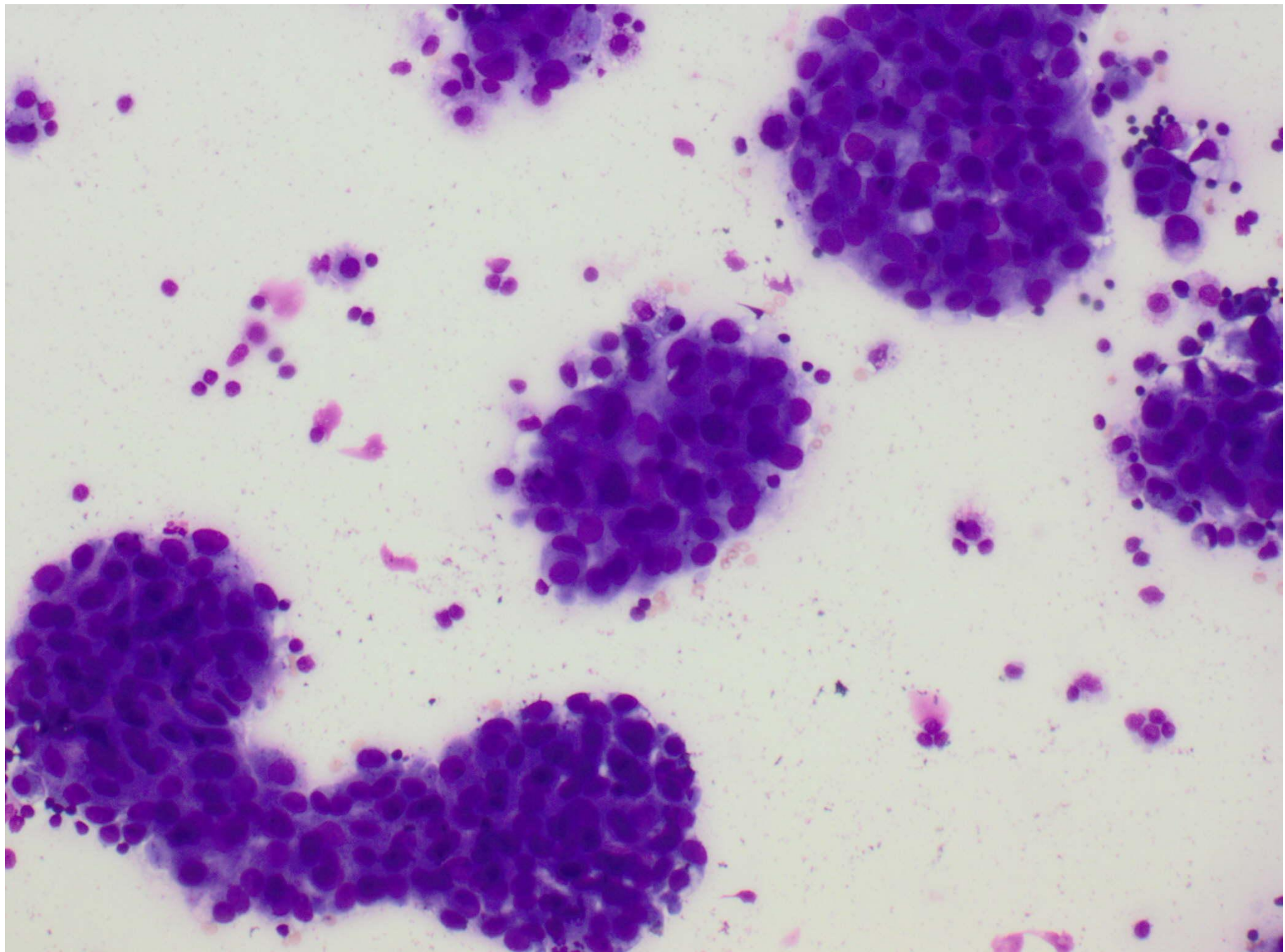
Magnification: 5 x

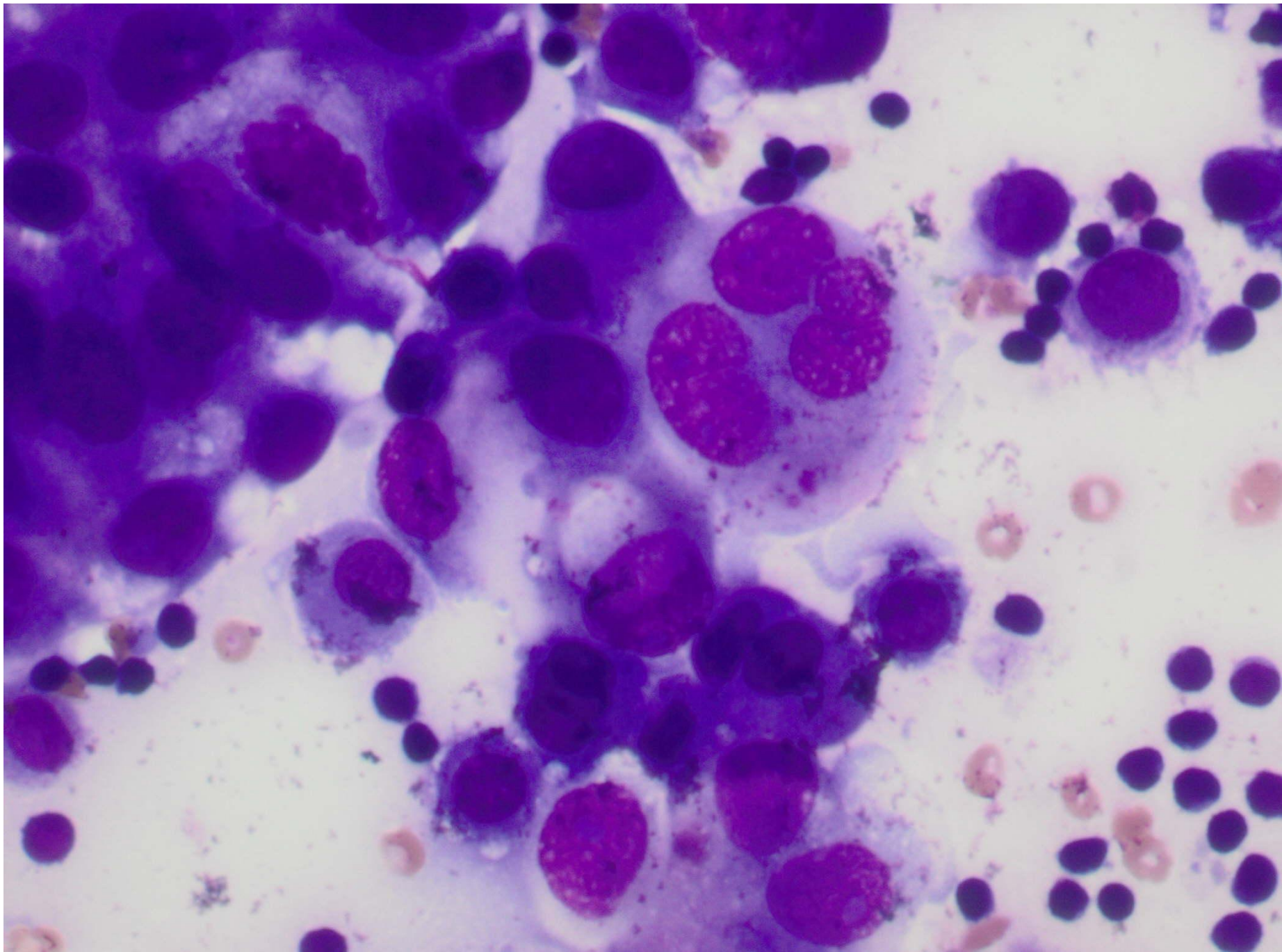
100 μ m

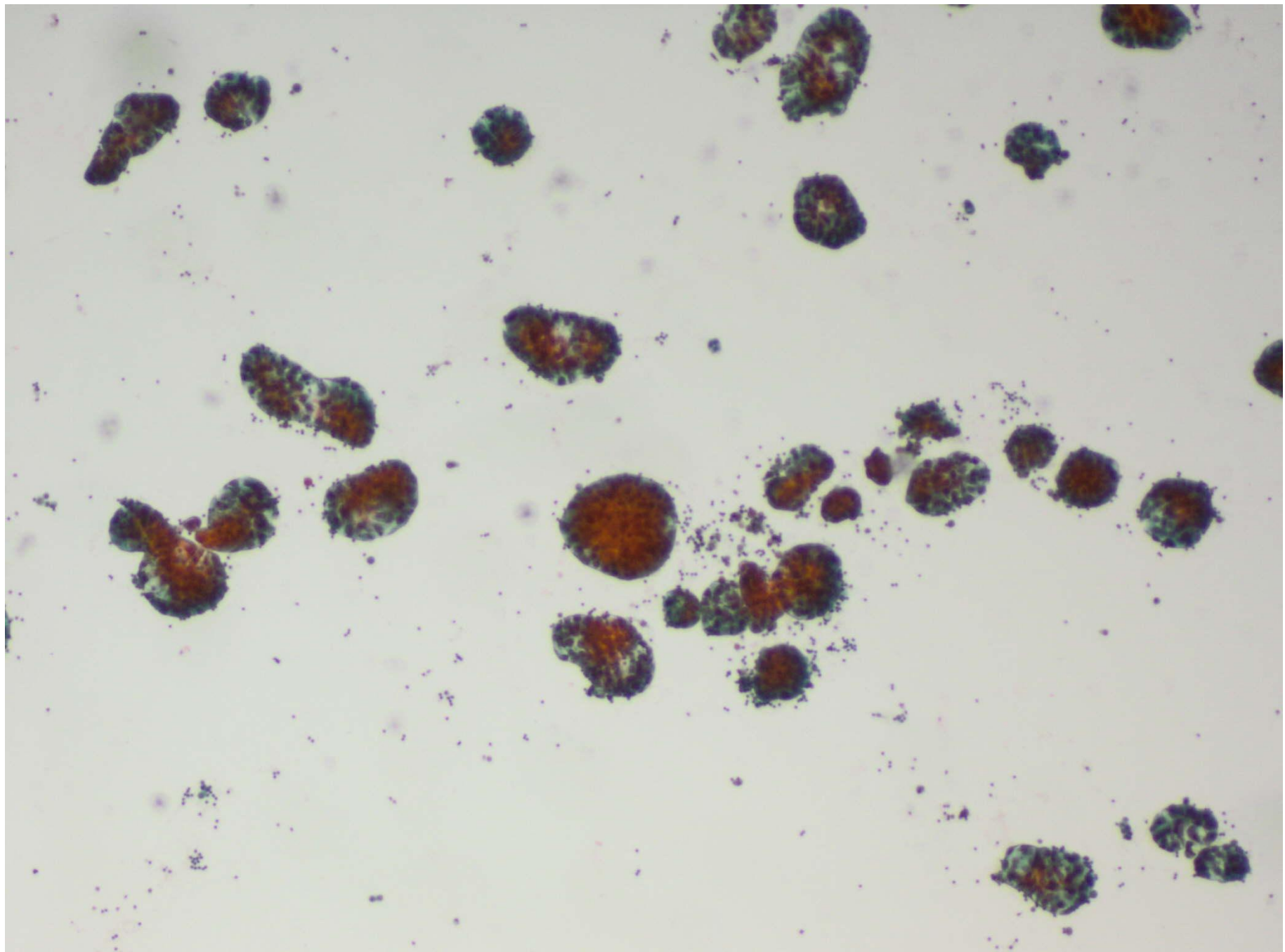
Case 9

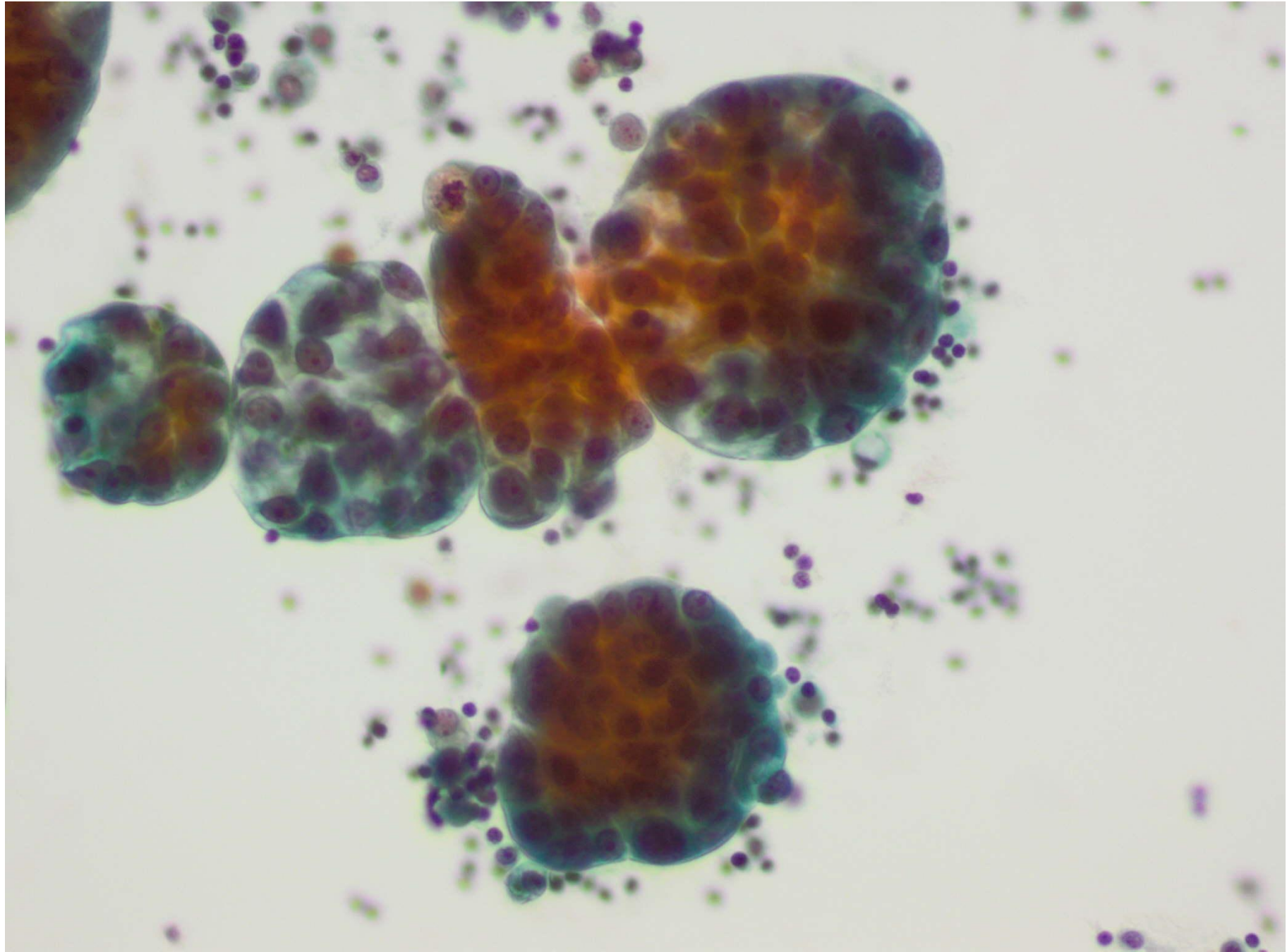
F60. Pleural effusion

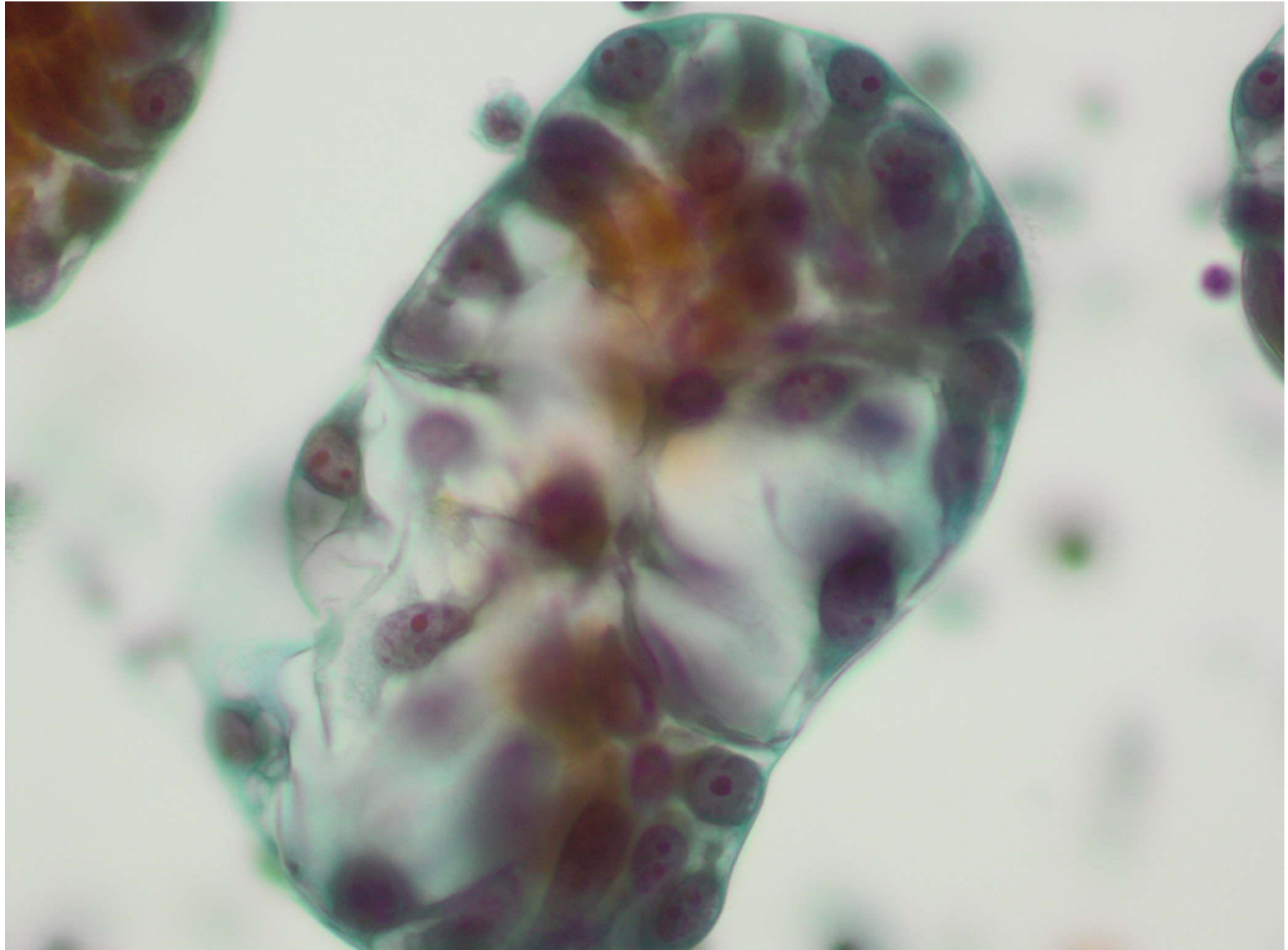


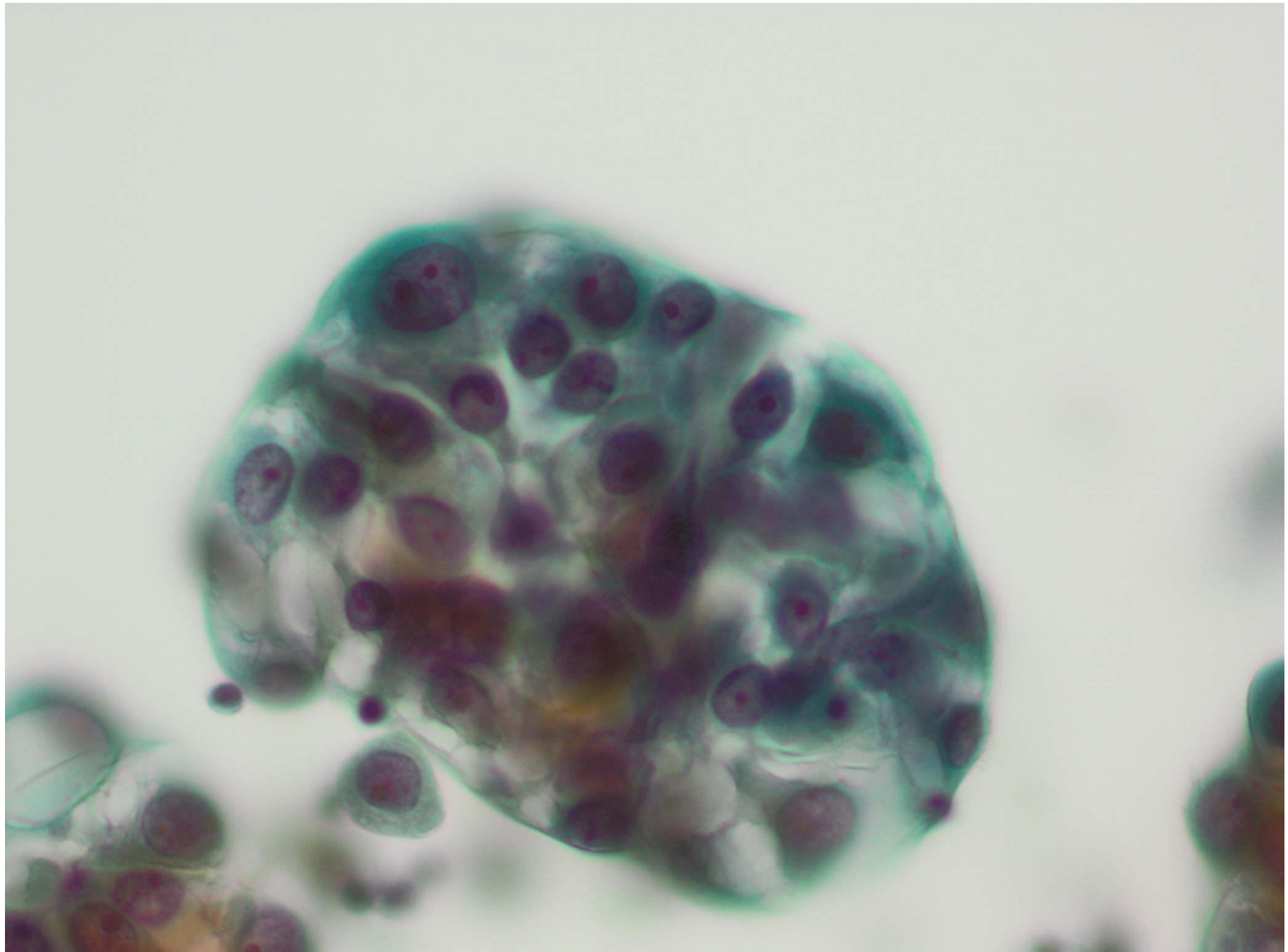






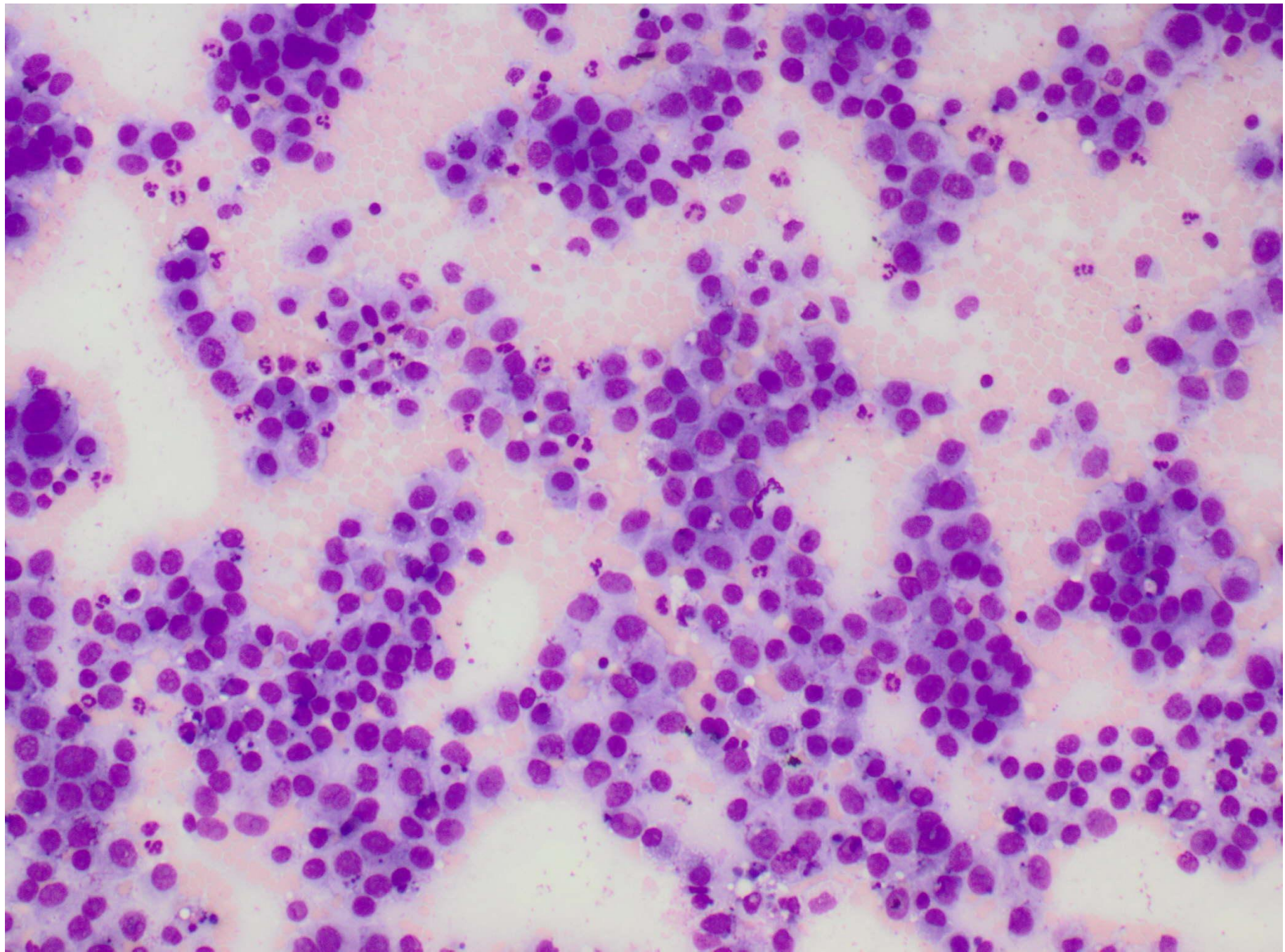


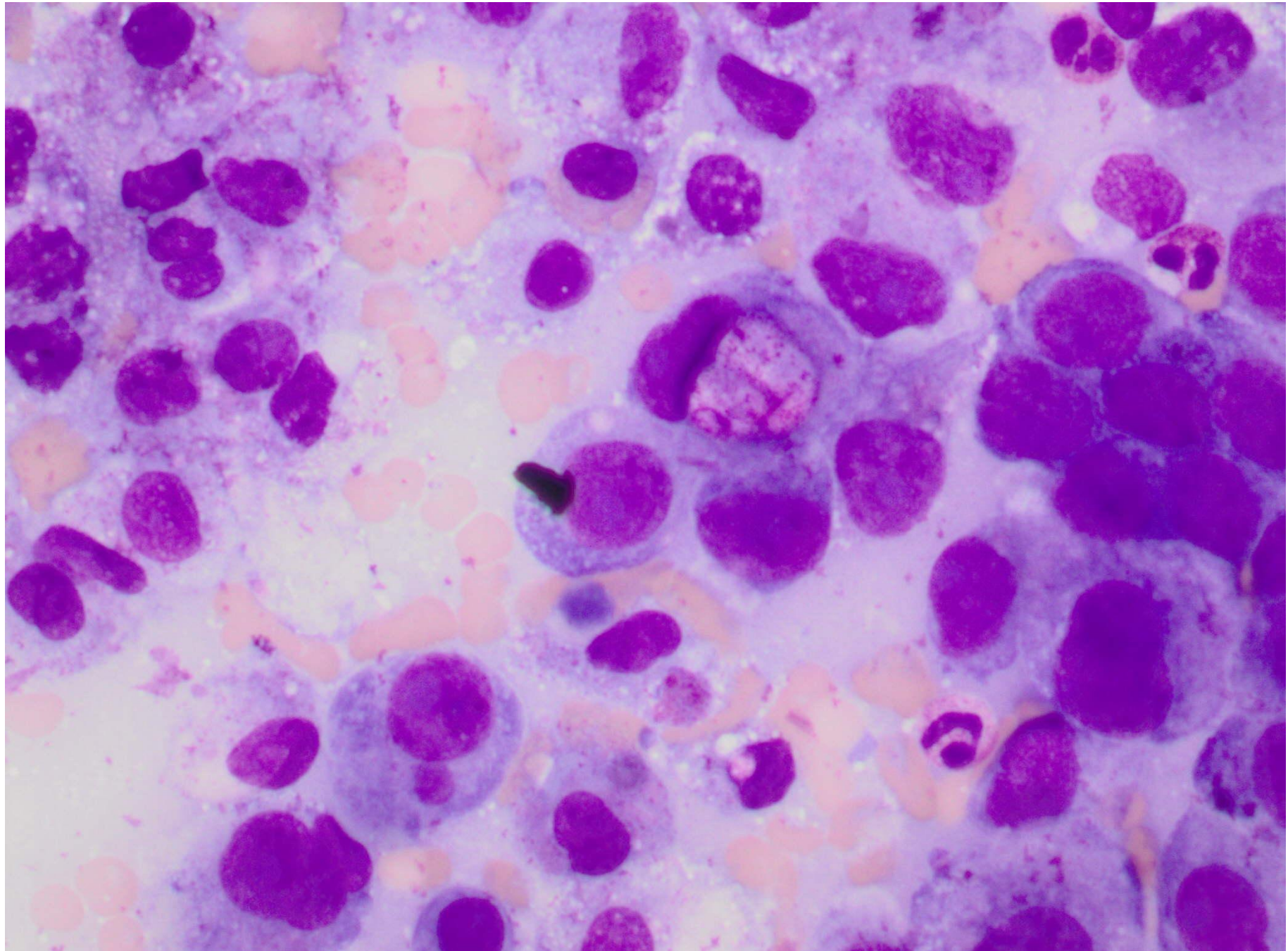


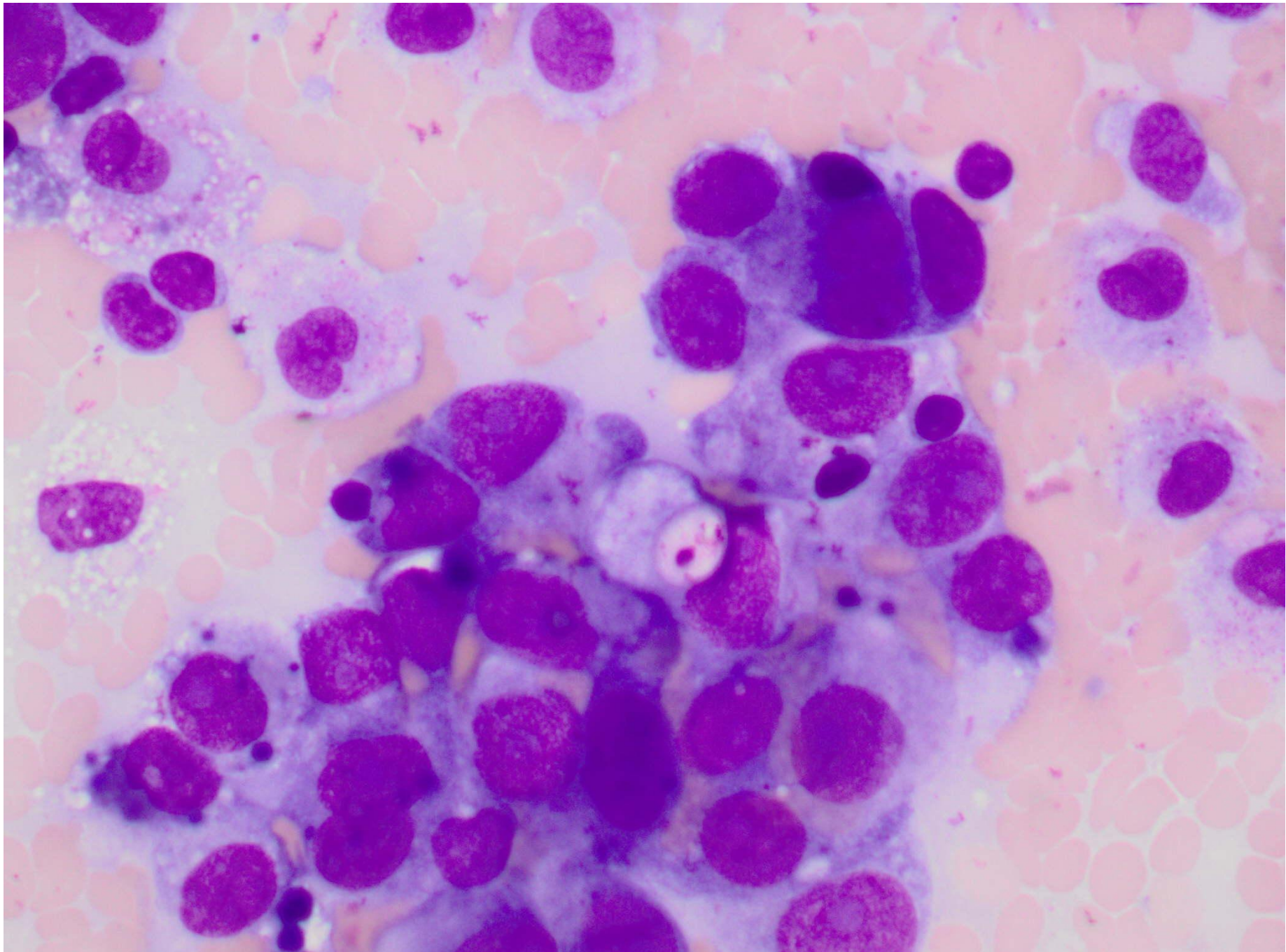


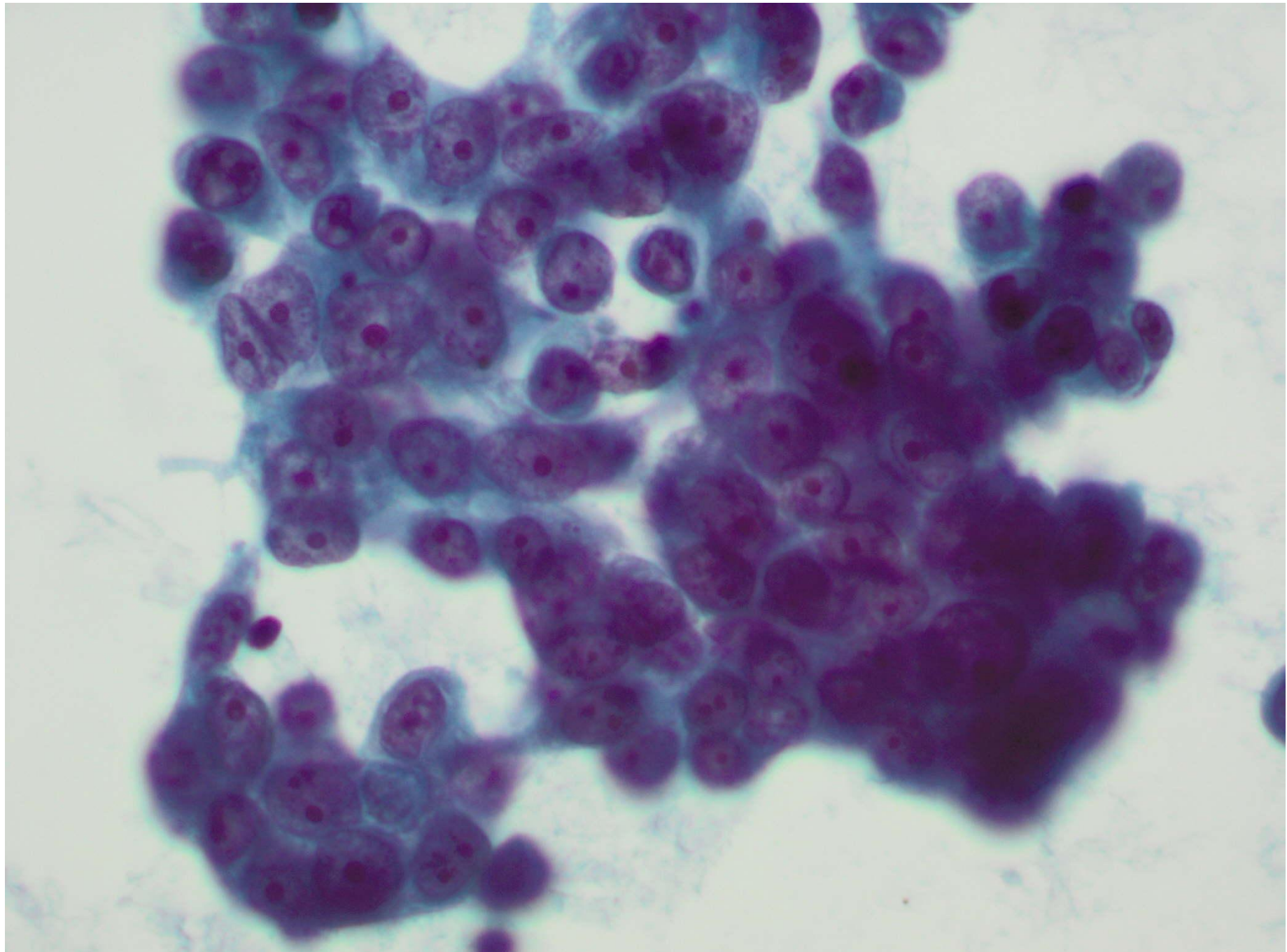
Case 10

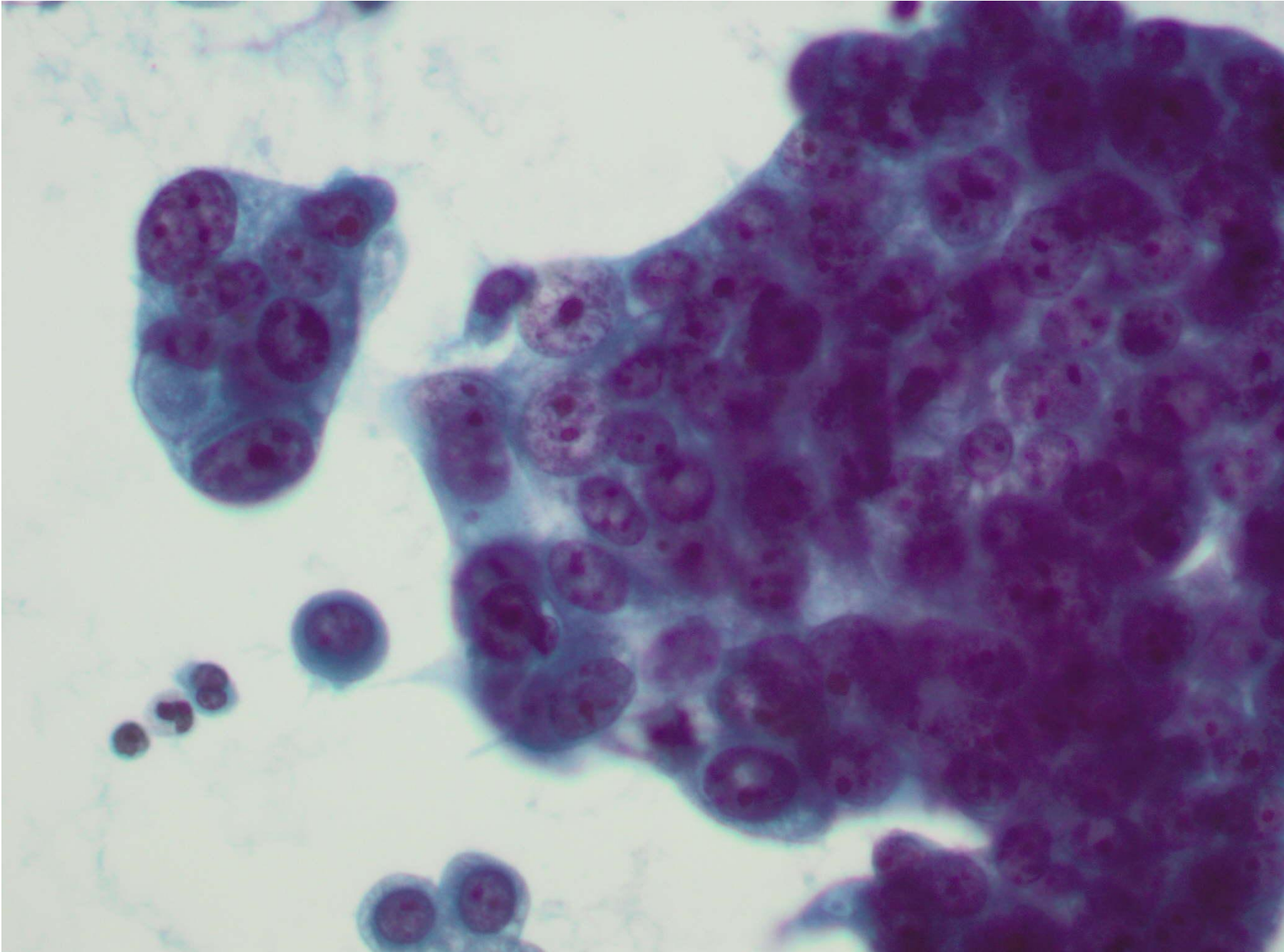
Male 55. Left pleural effusion.

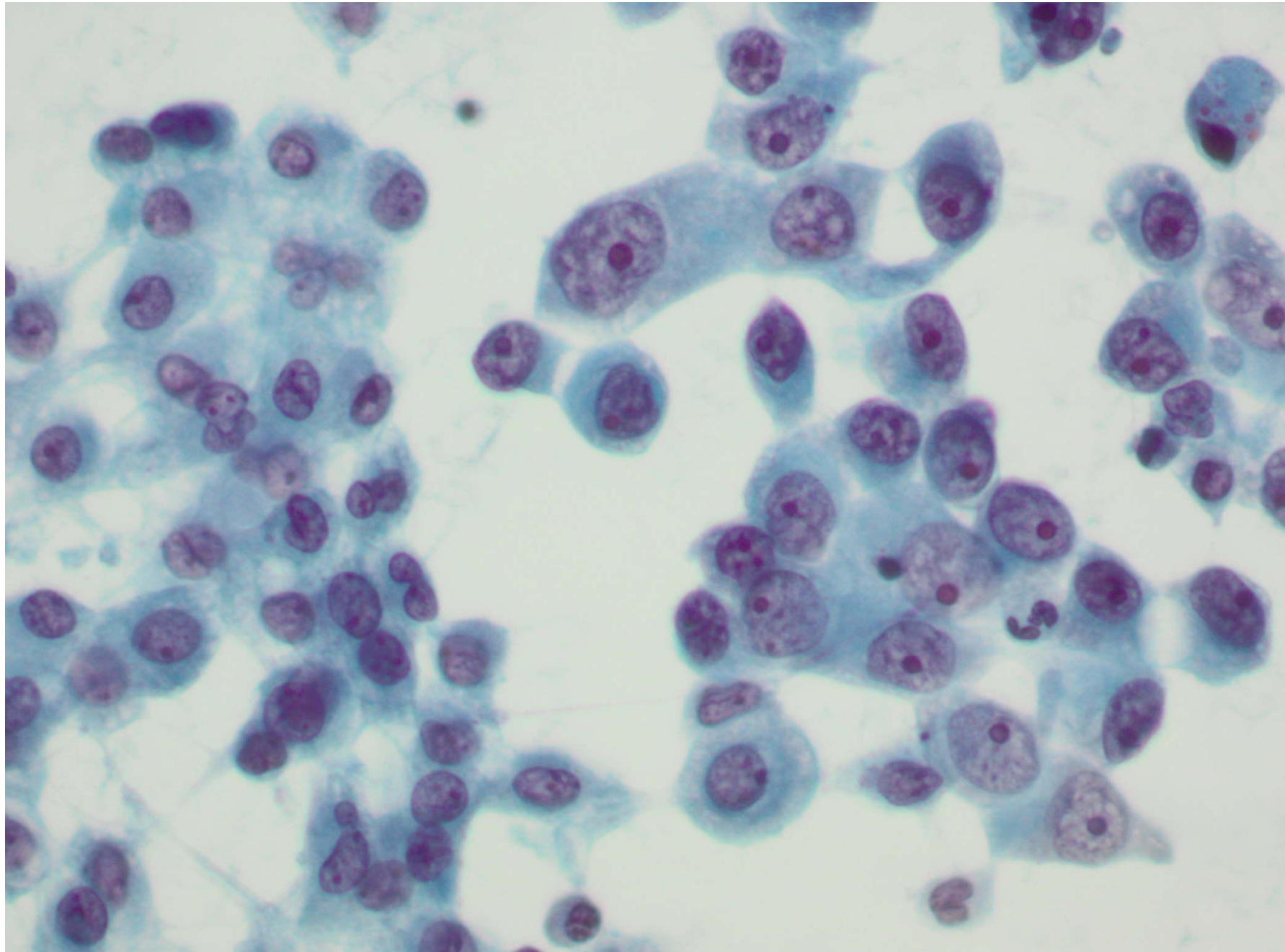









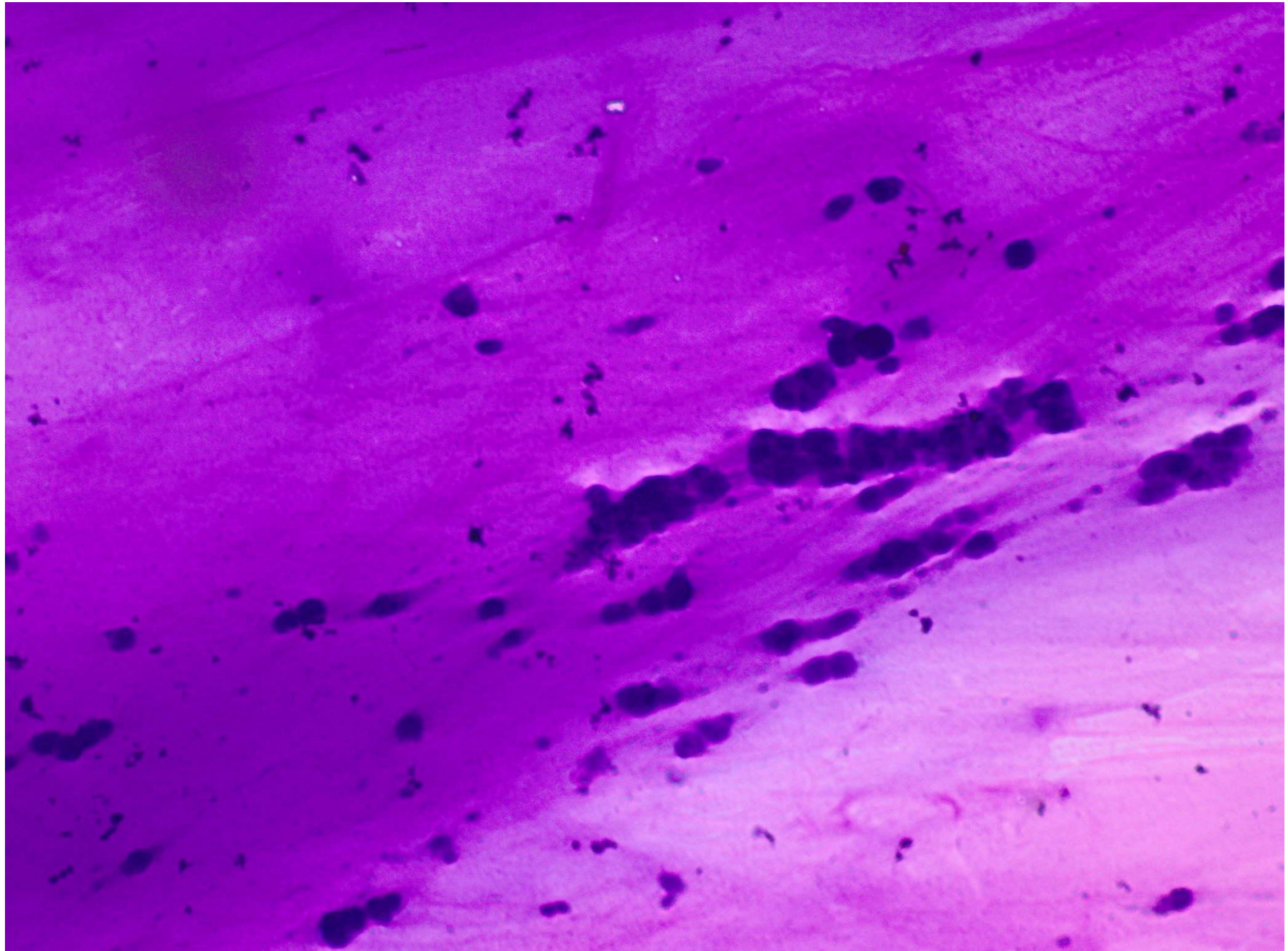


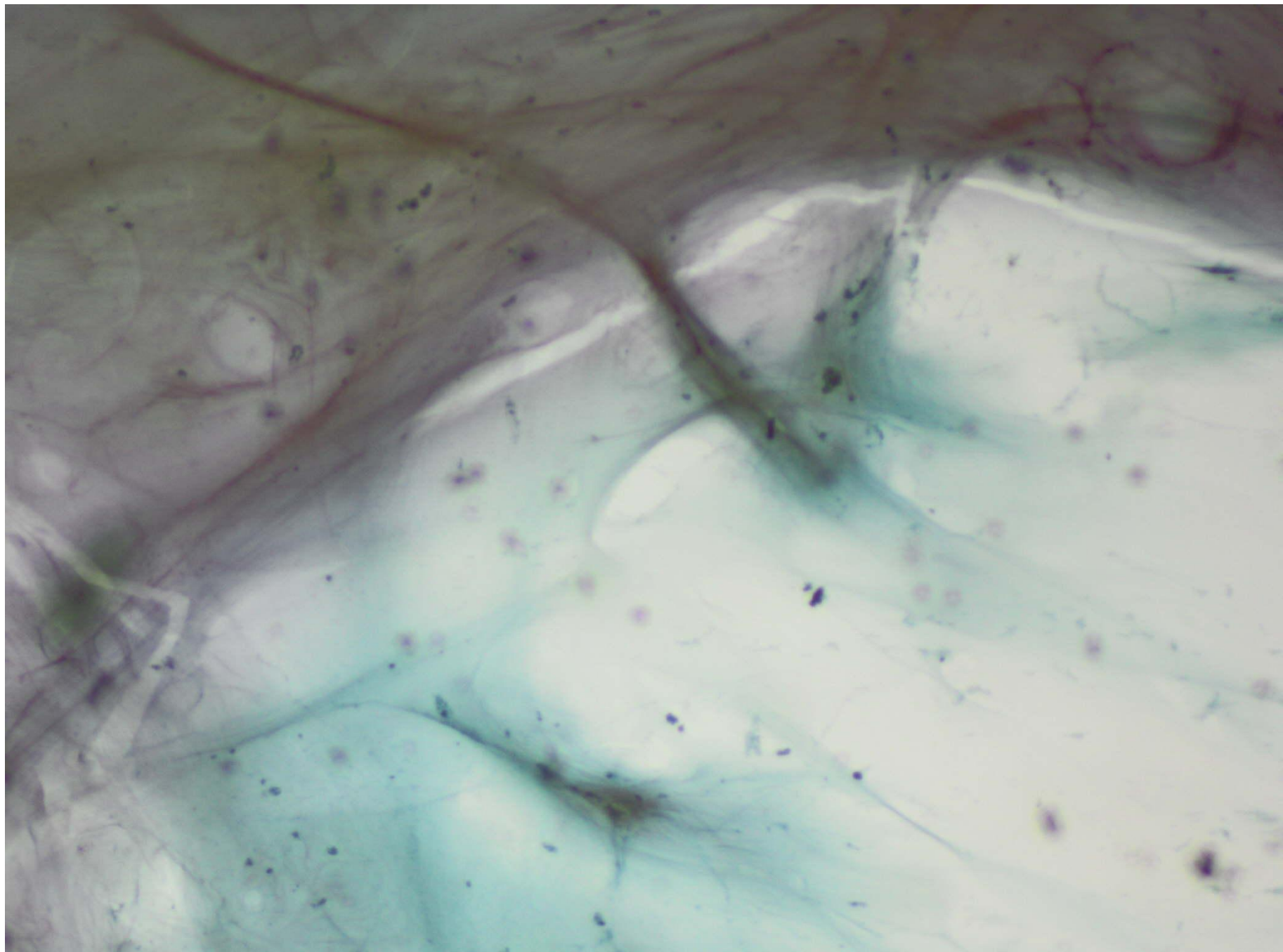


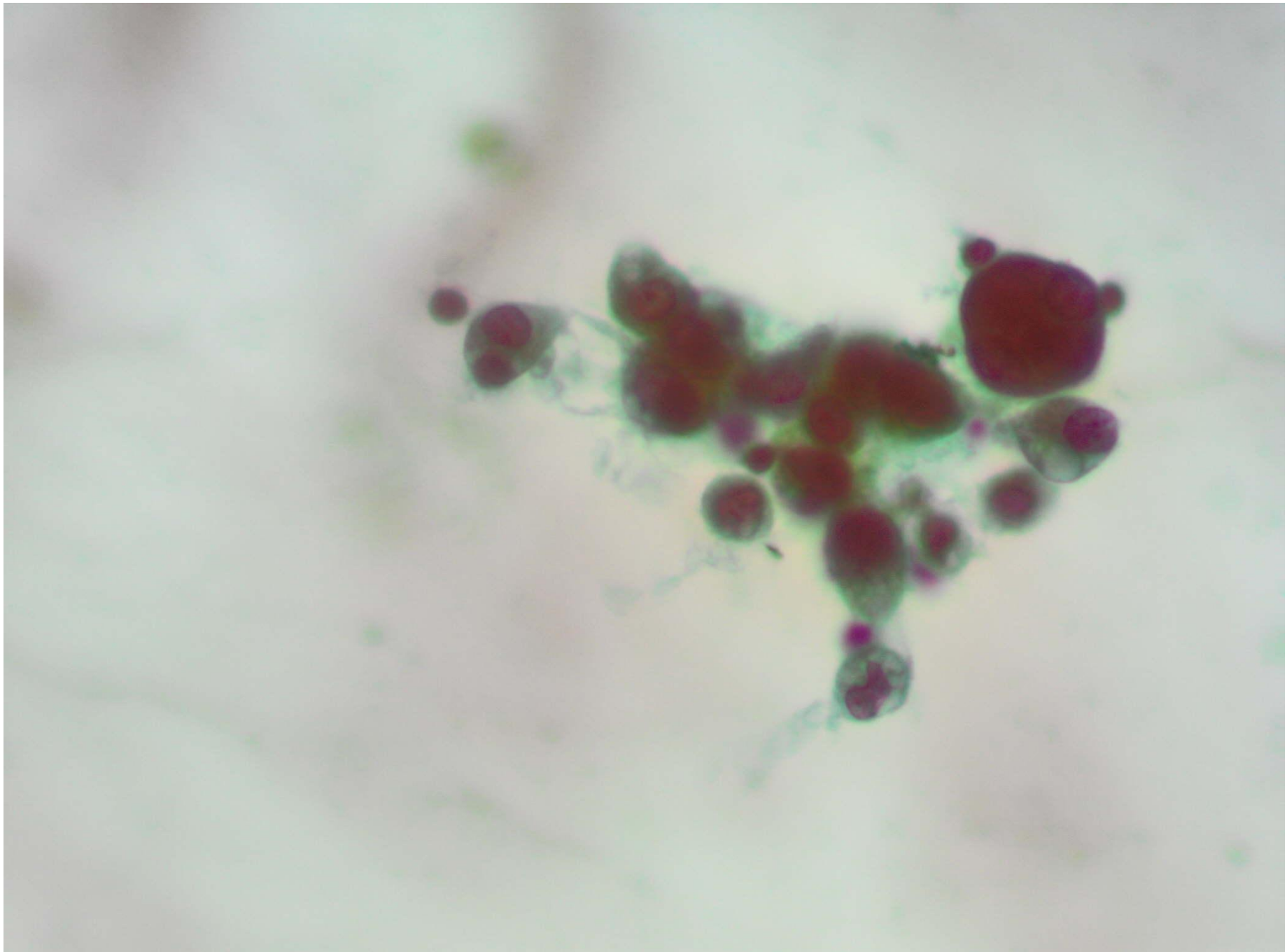
Case 11

Female 30. Ascites.



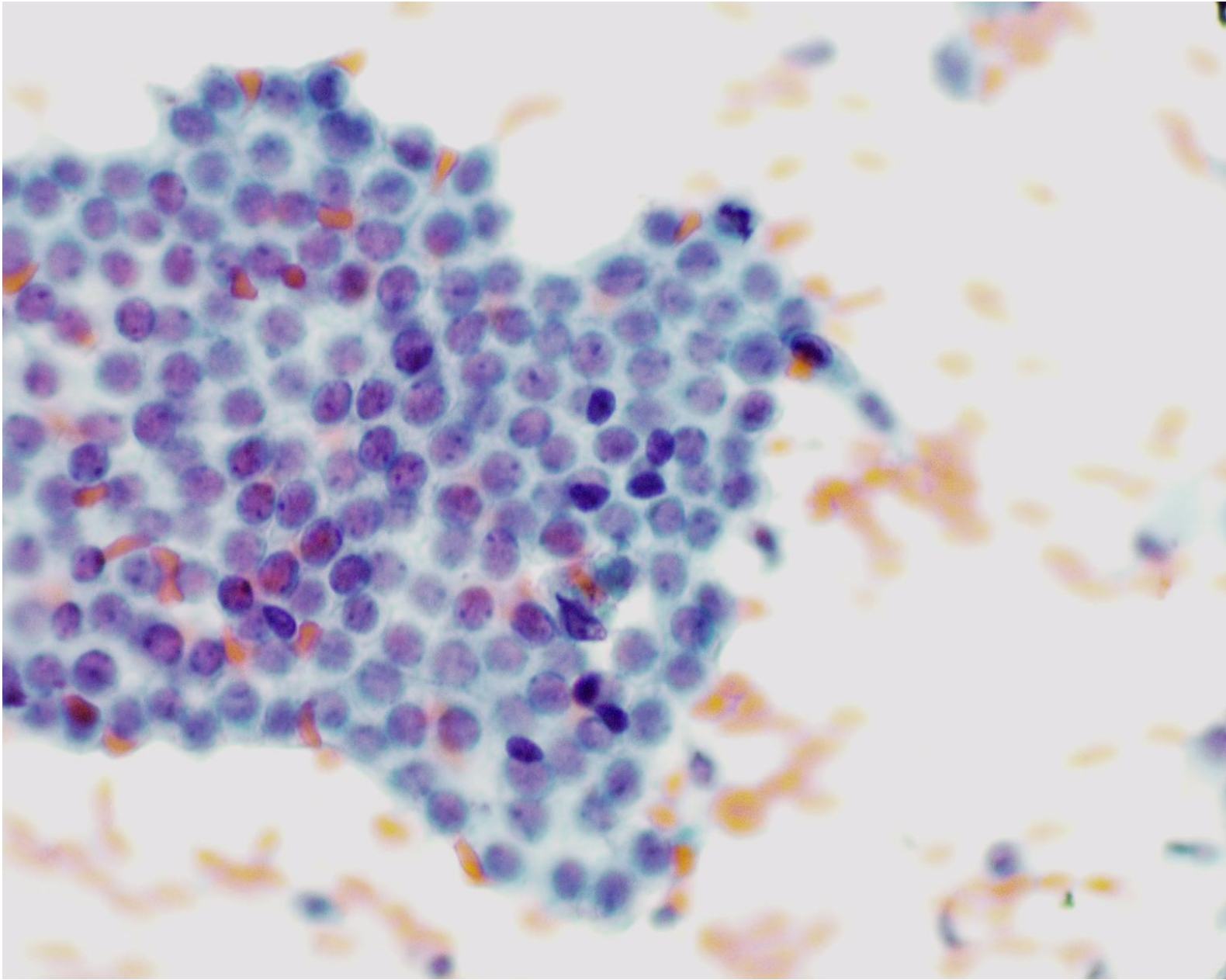


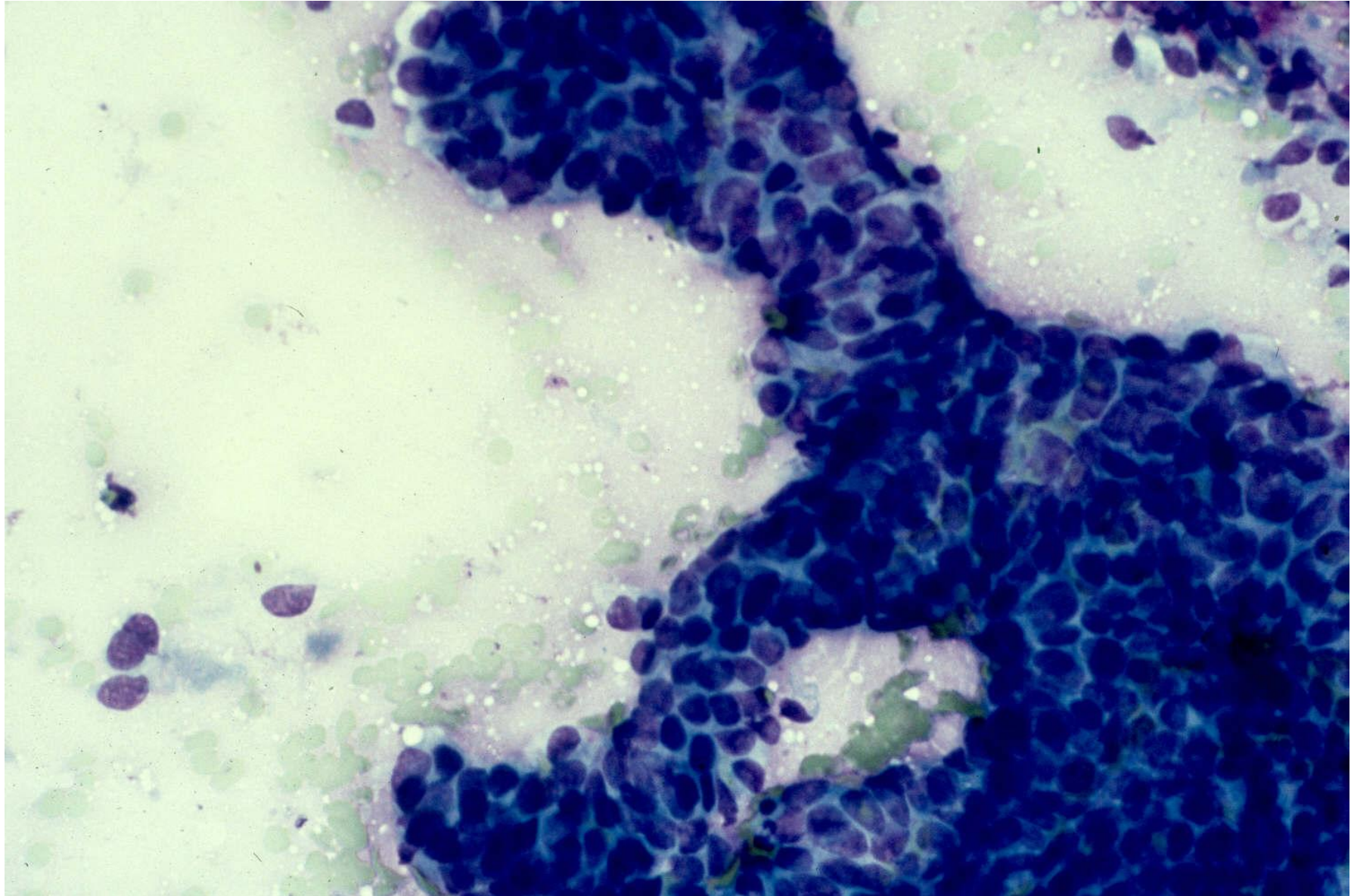


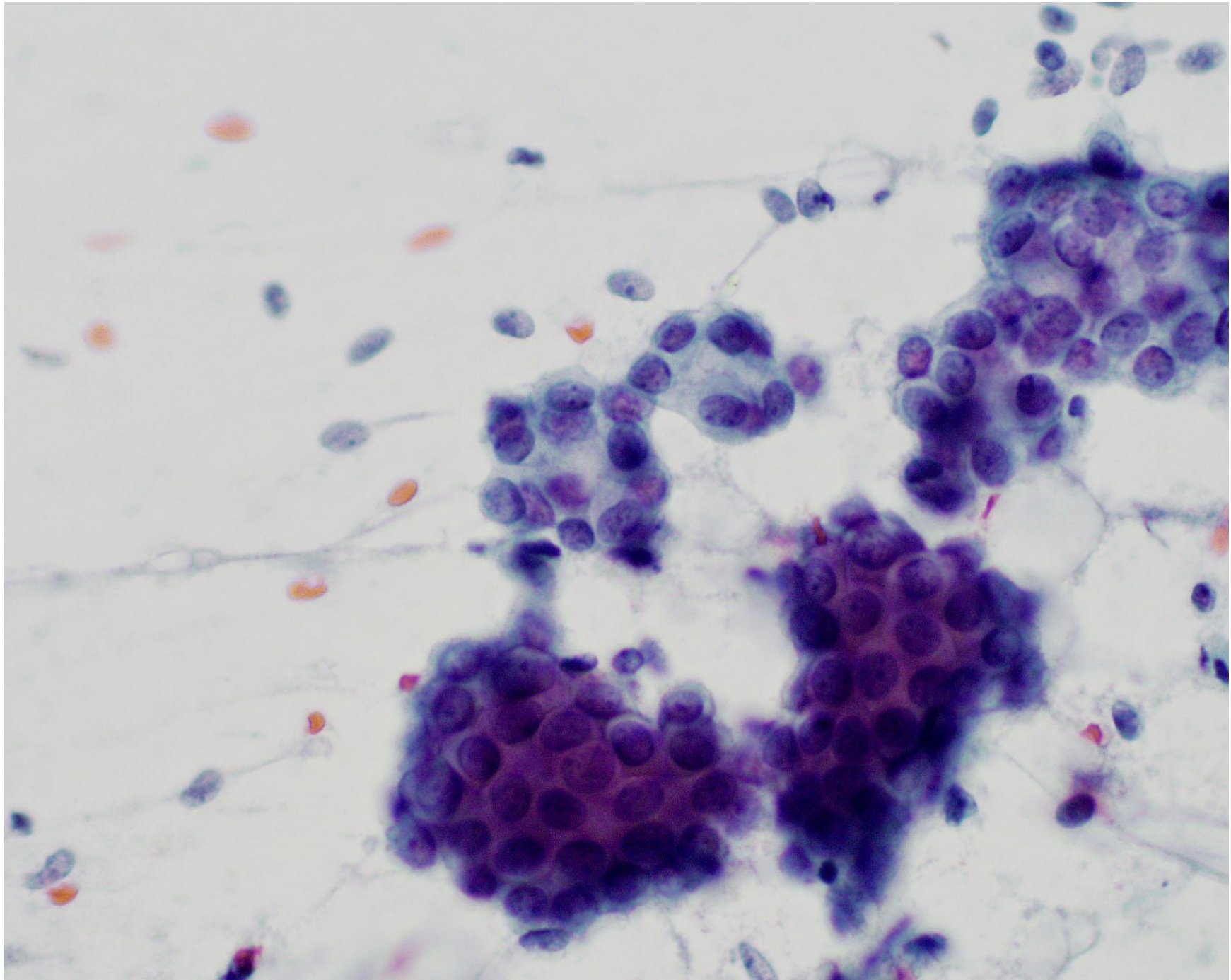


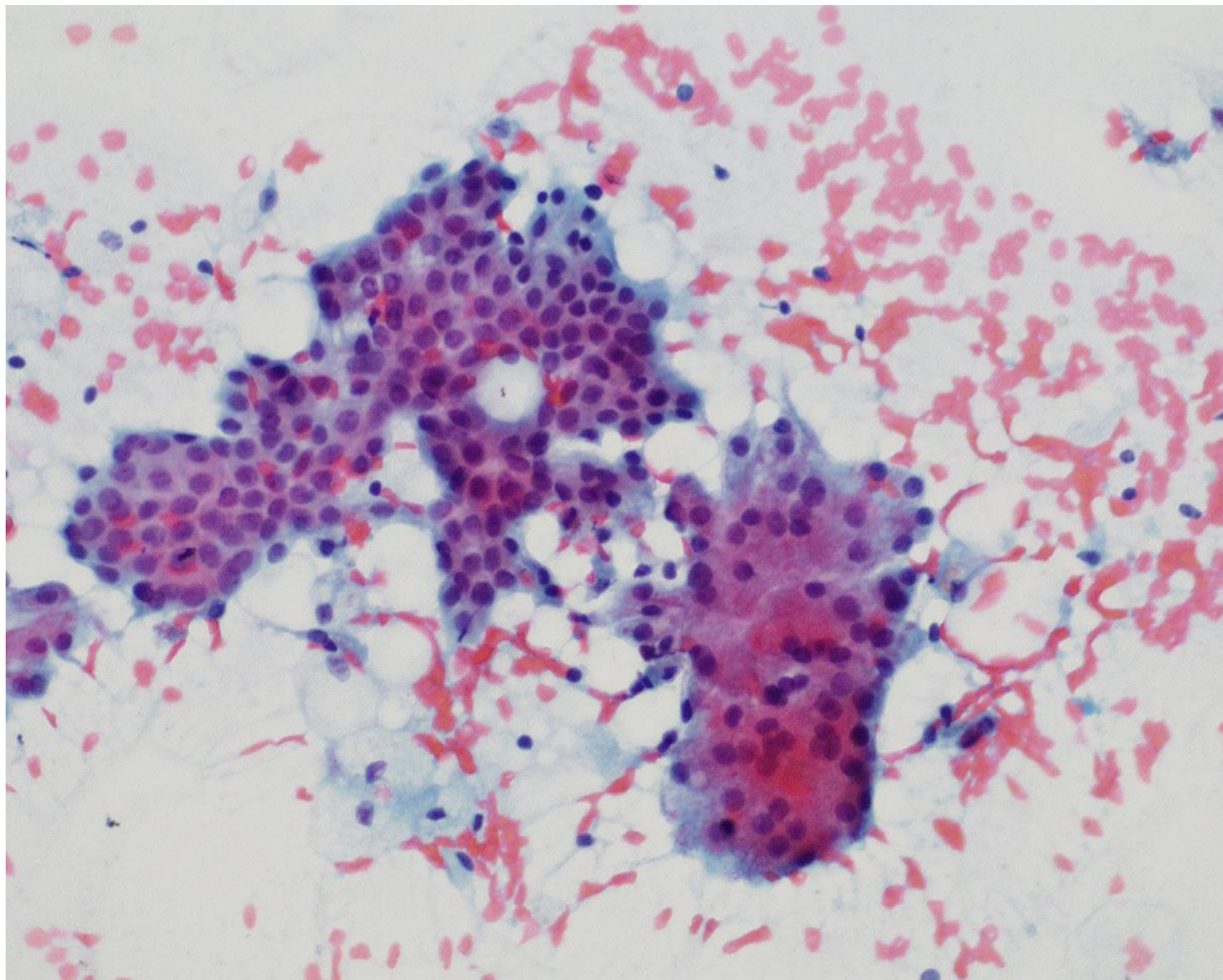
Case 12

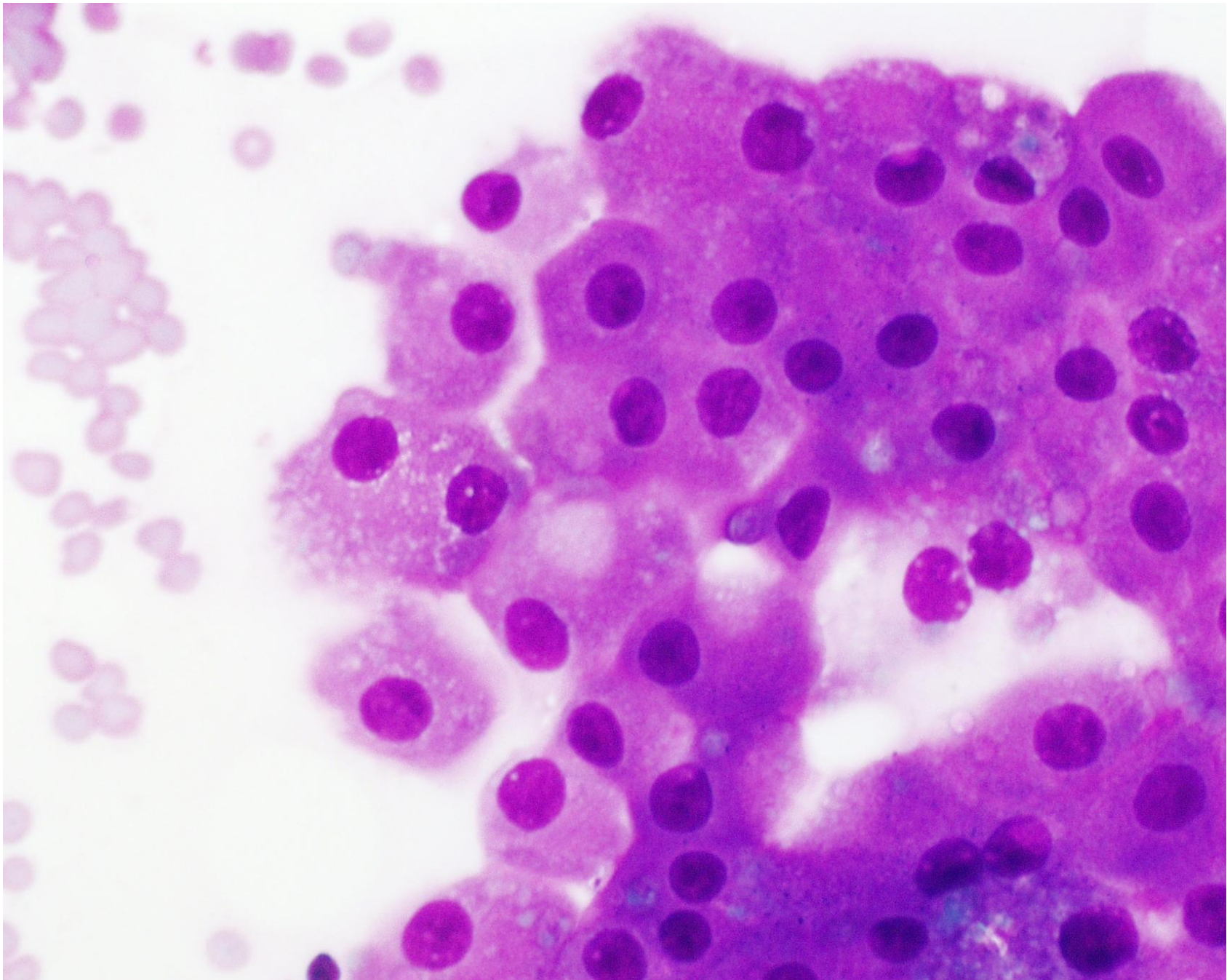
F40. Tender, vague mass left breast.





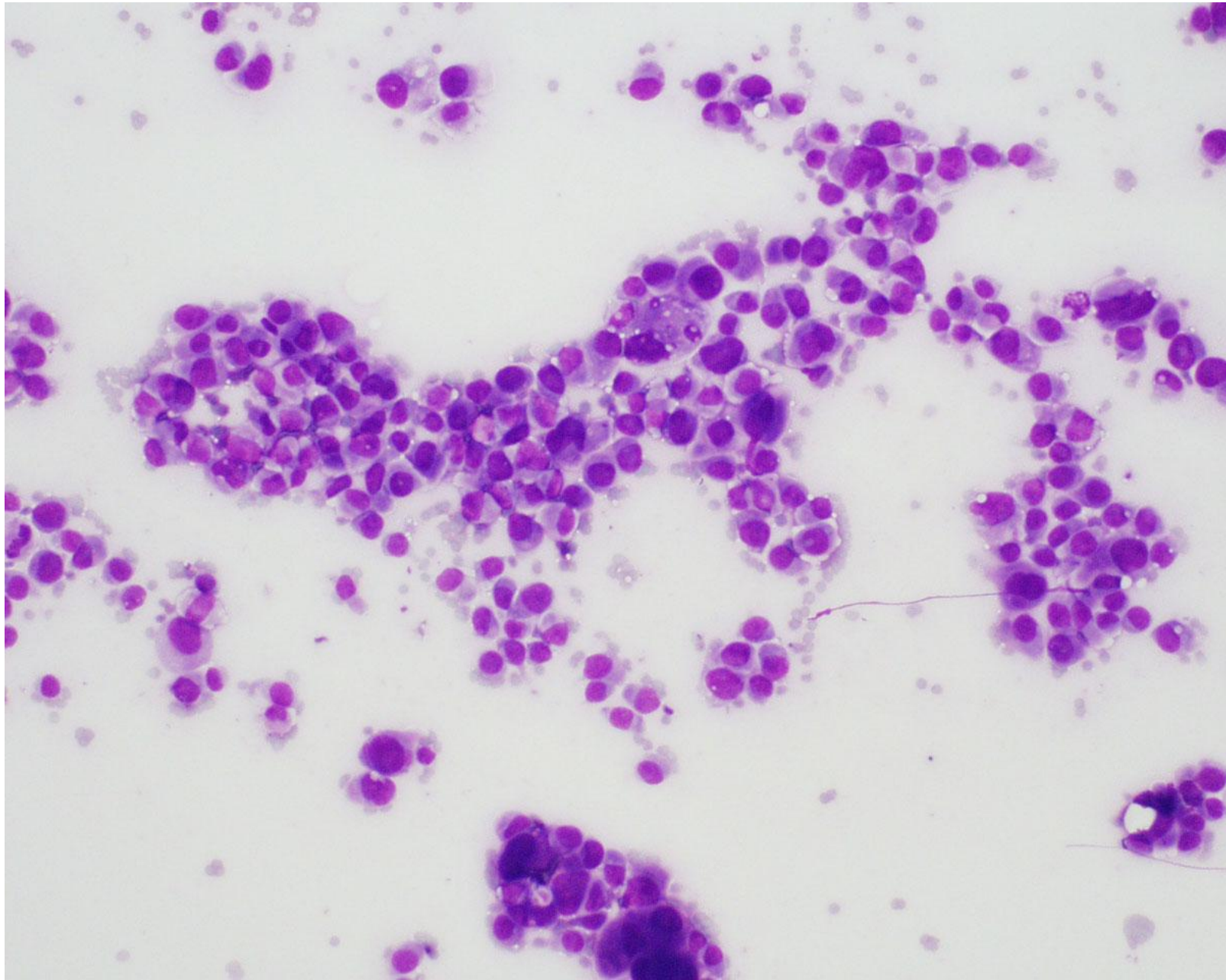


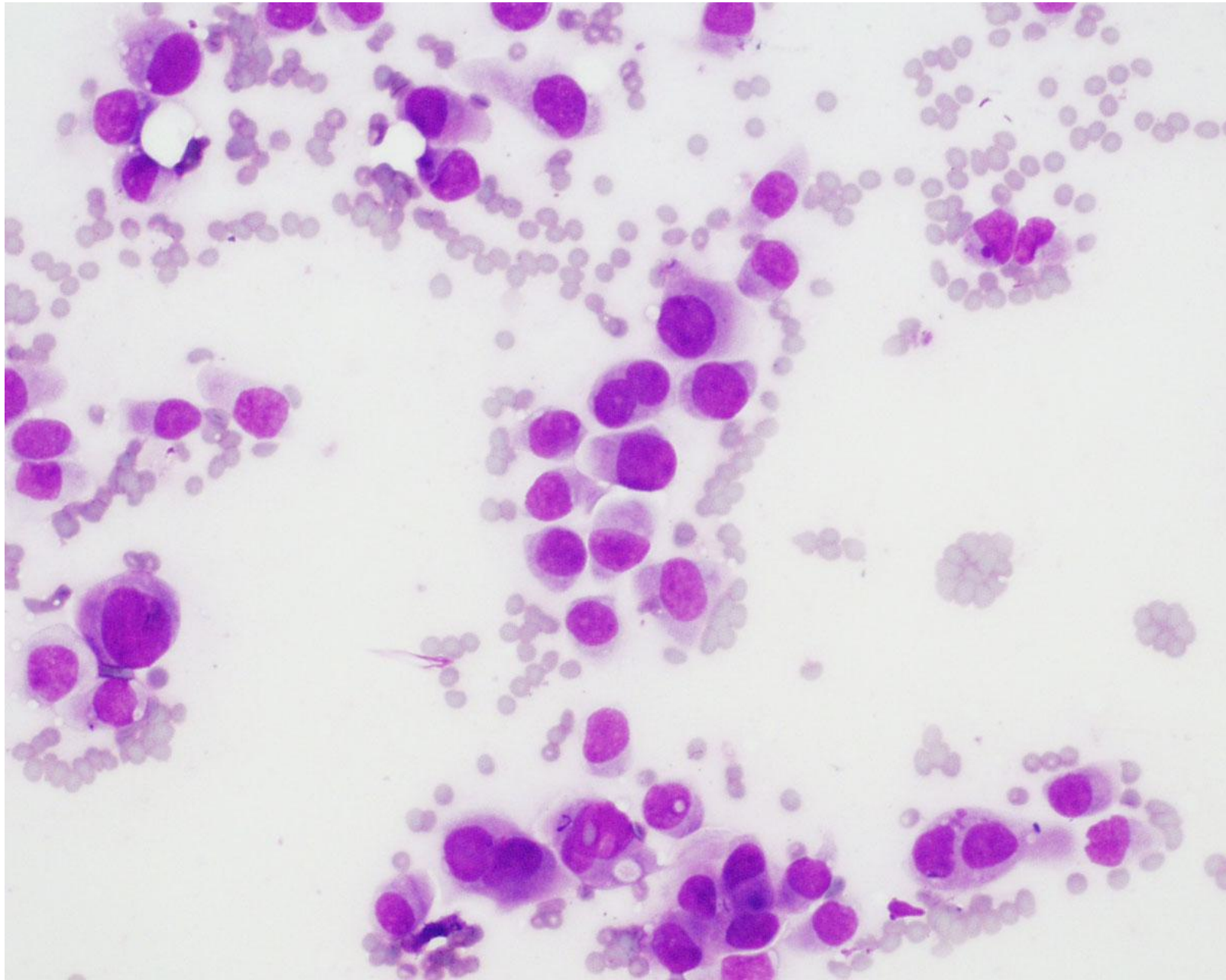


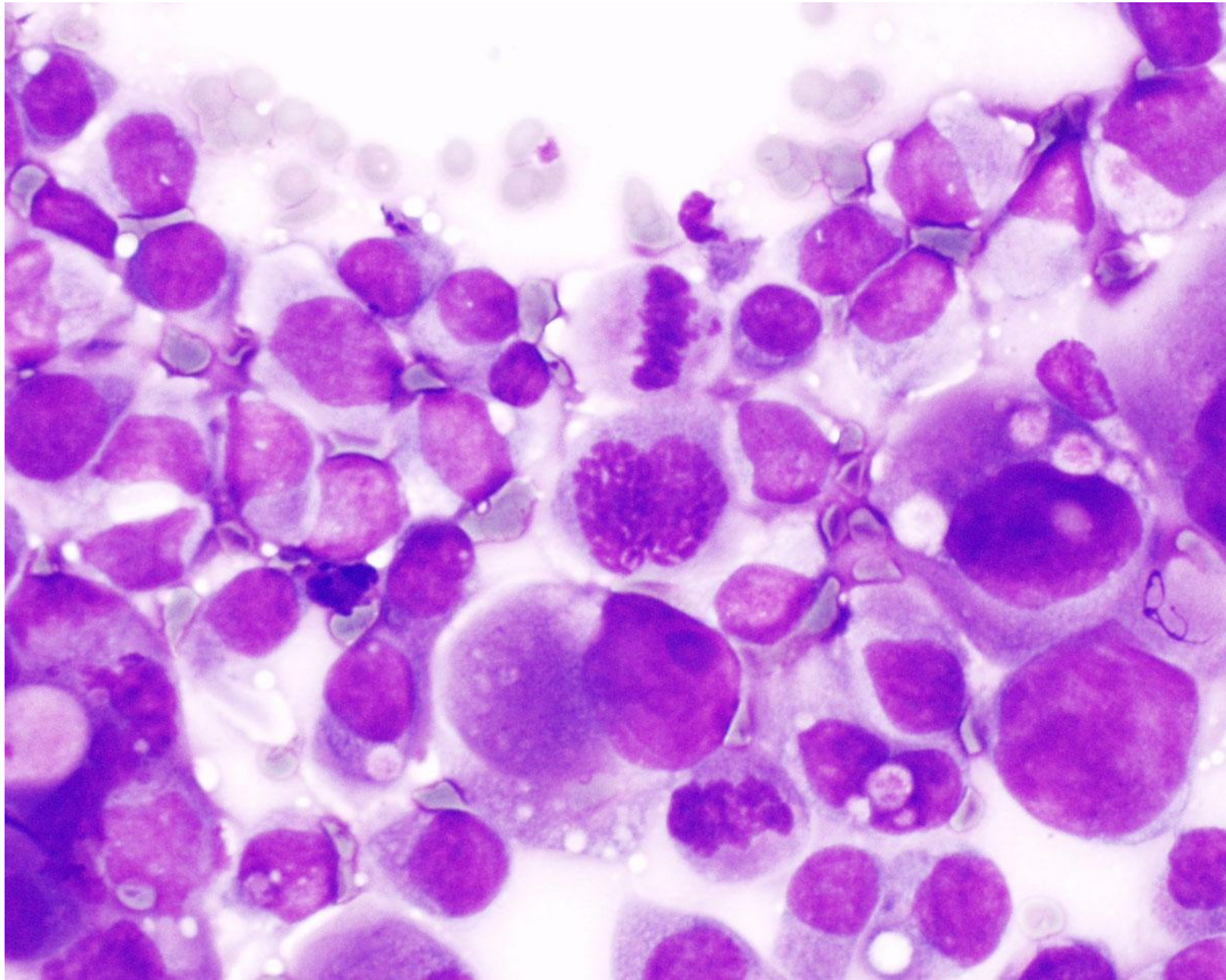


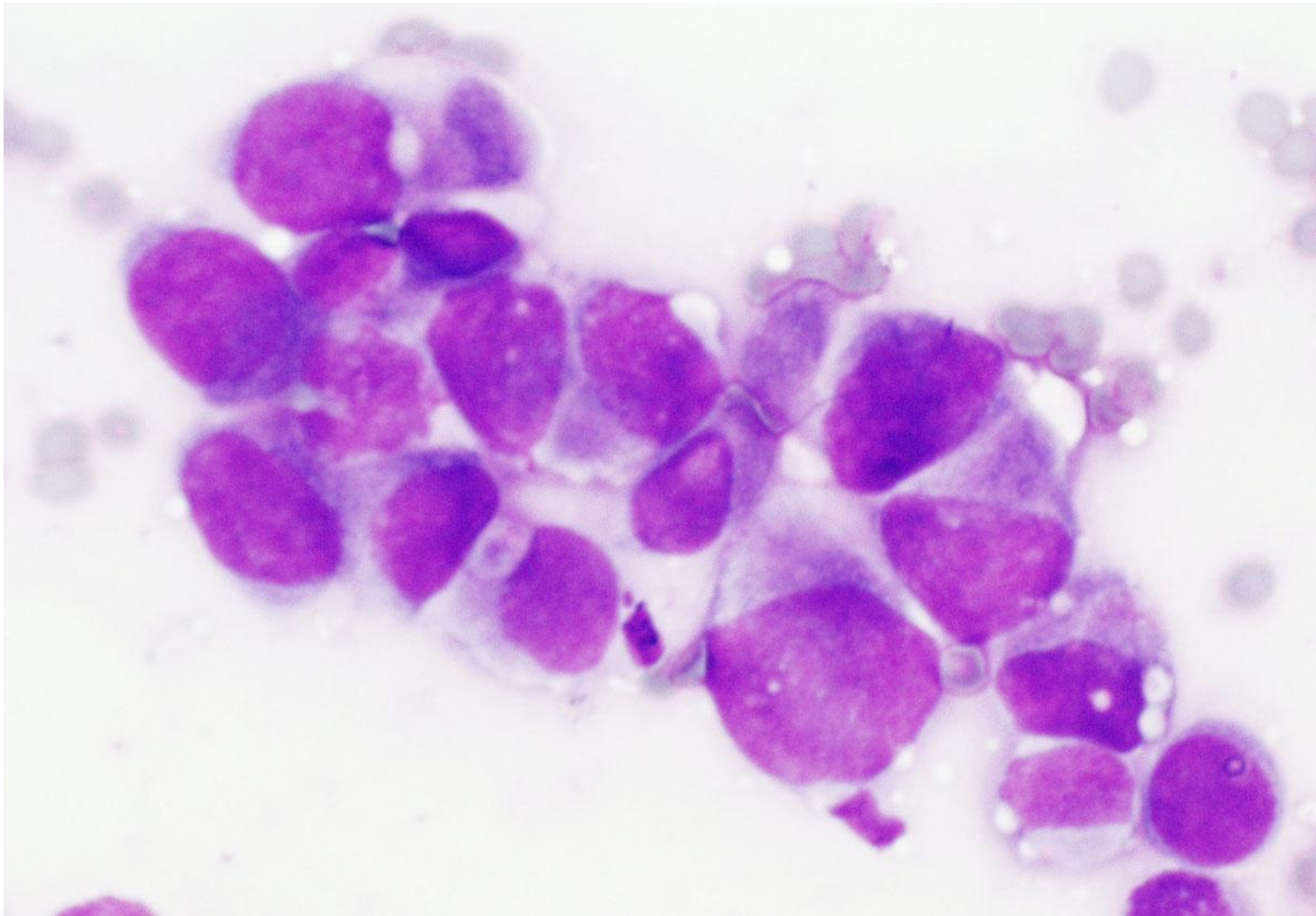
Case 13

F42. Self detected nodule in breast. FNA right breast.



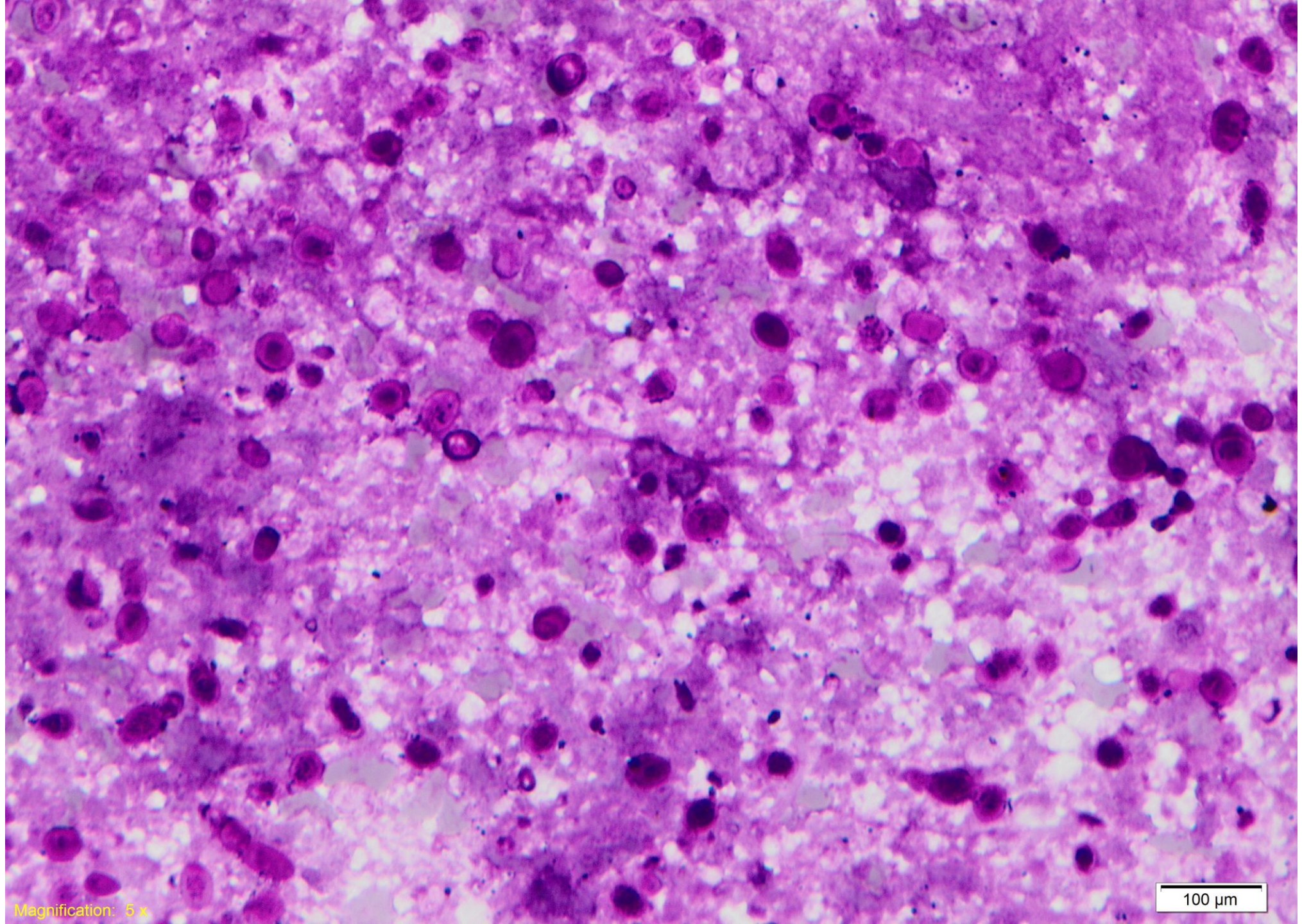






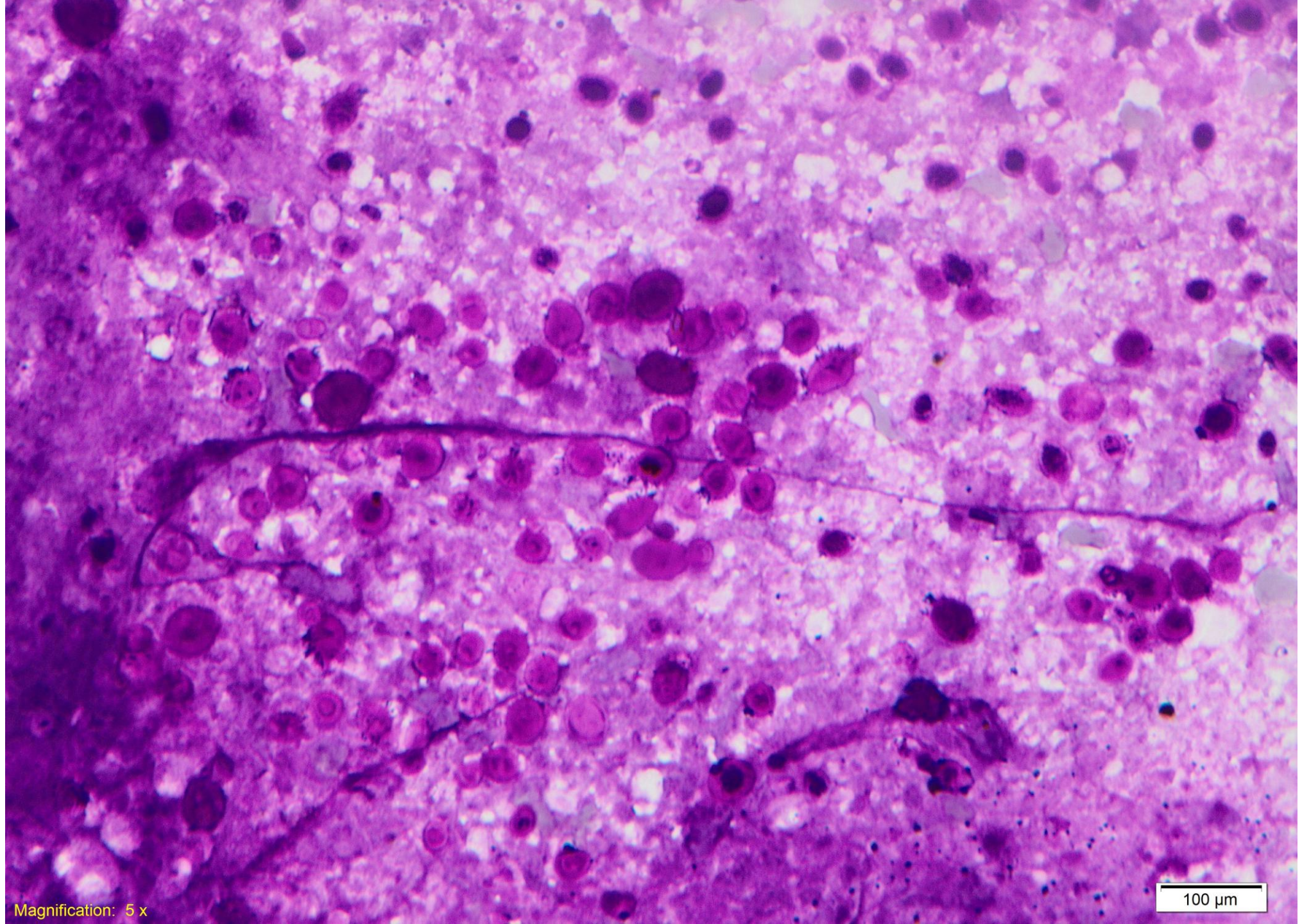
Case 14

Renal transplant patient. Consolidation RUL. FNA.



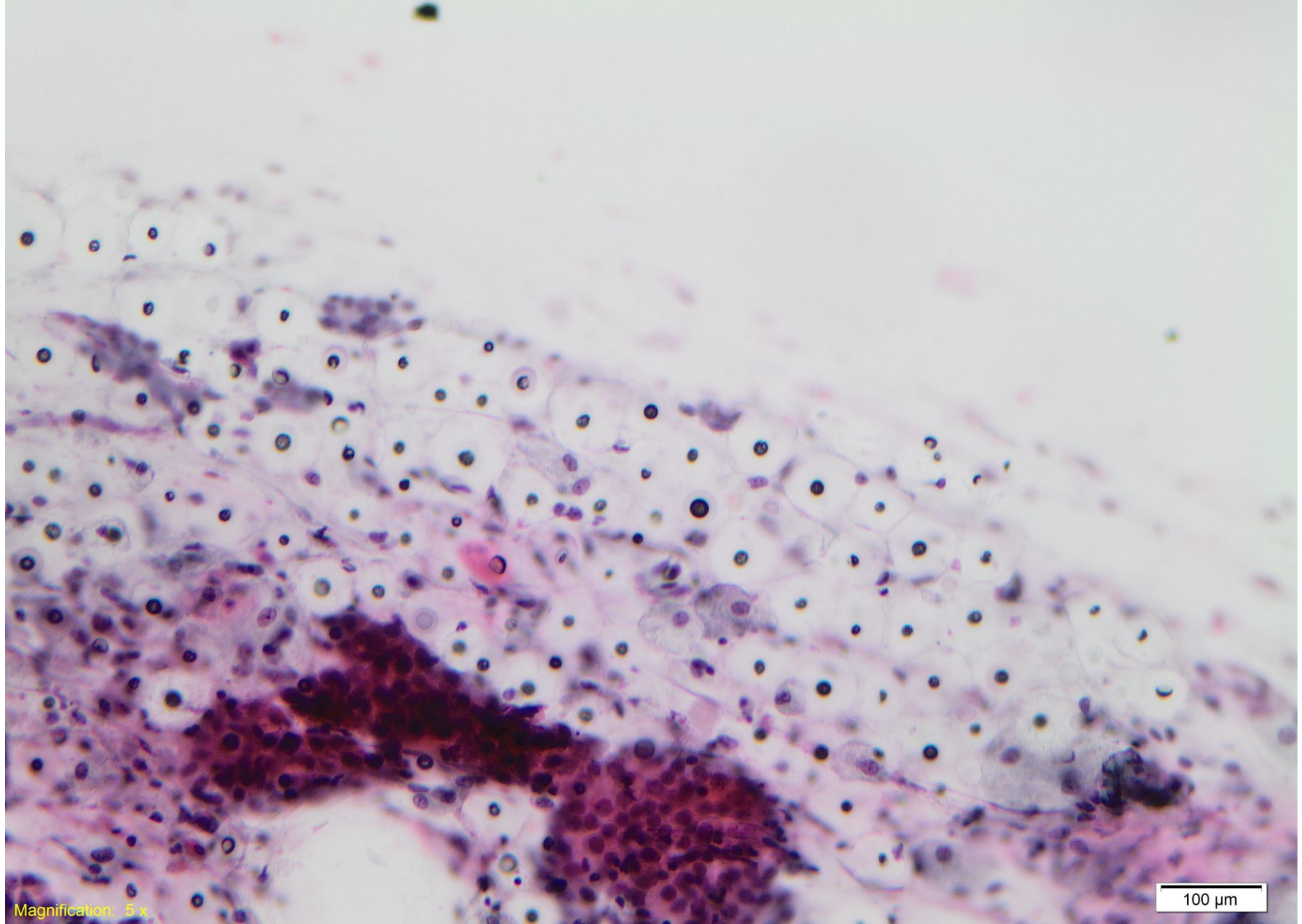
Magnification: 5 x

100 μ m



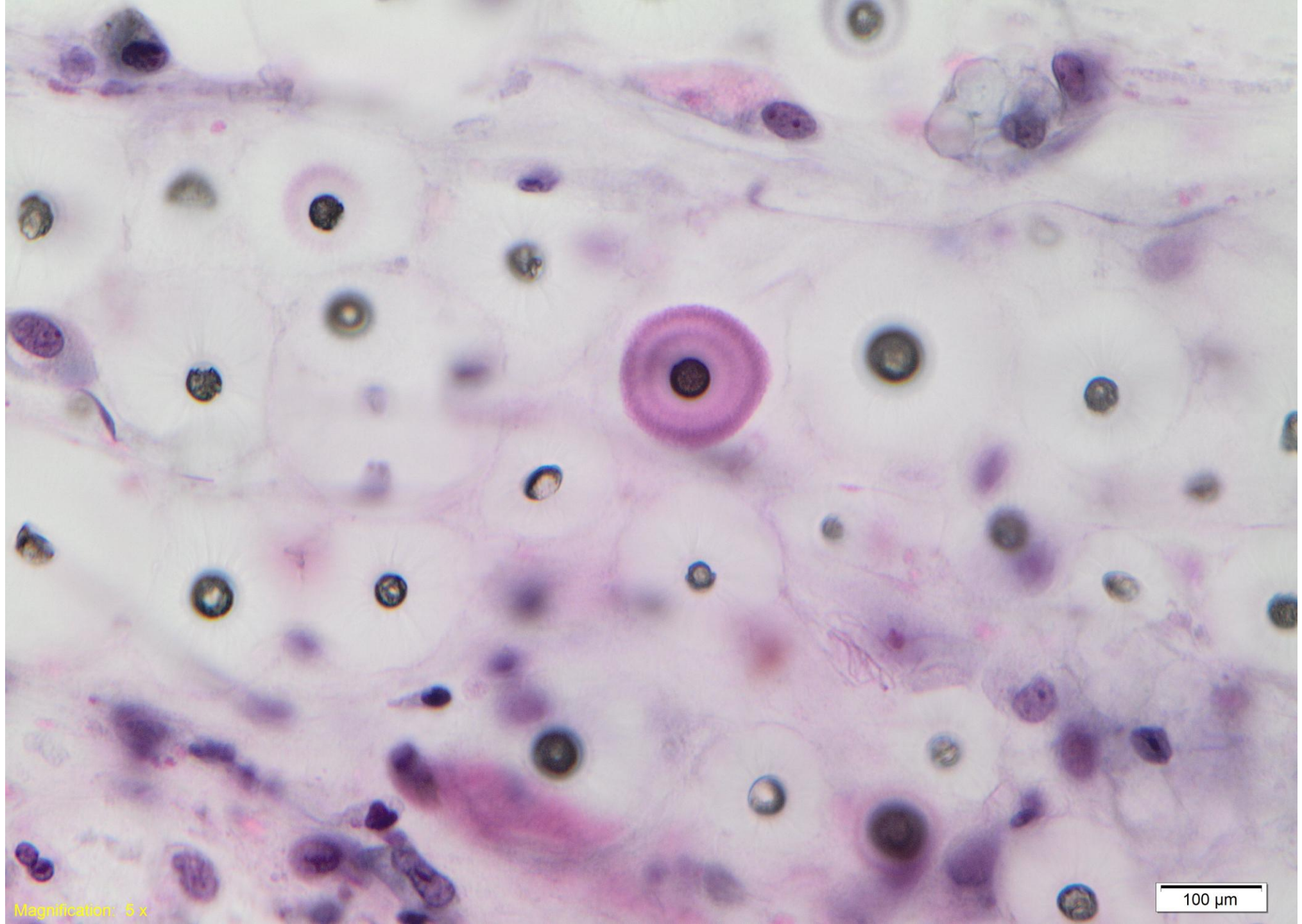
Magnification: 5 x

100 μ m



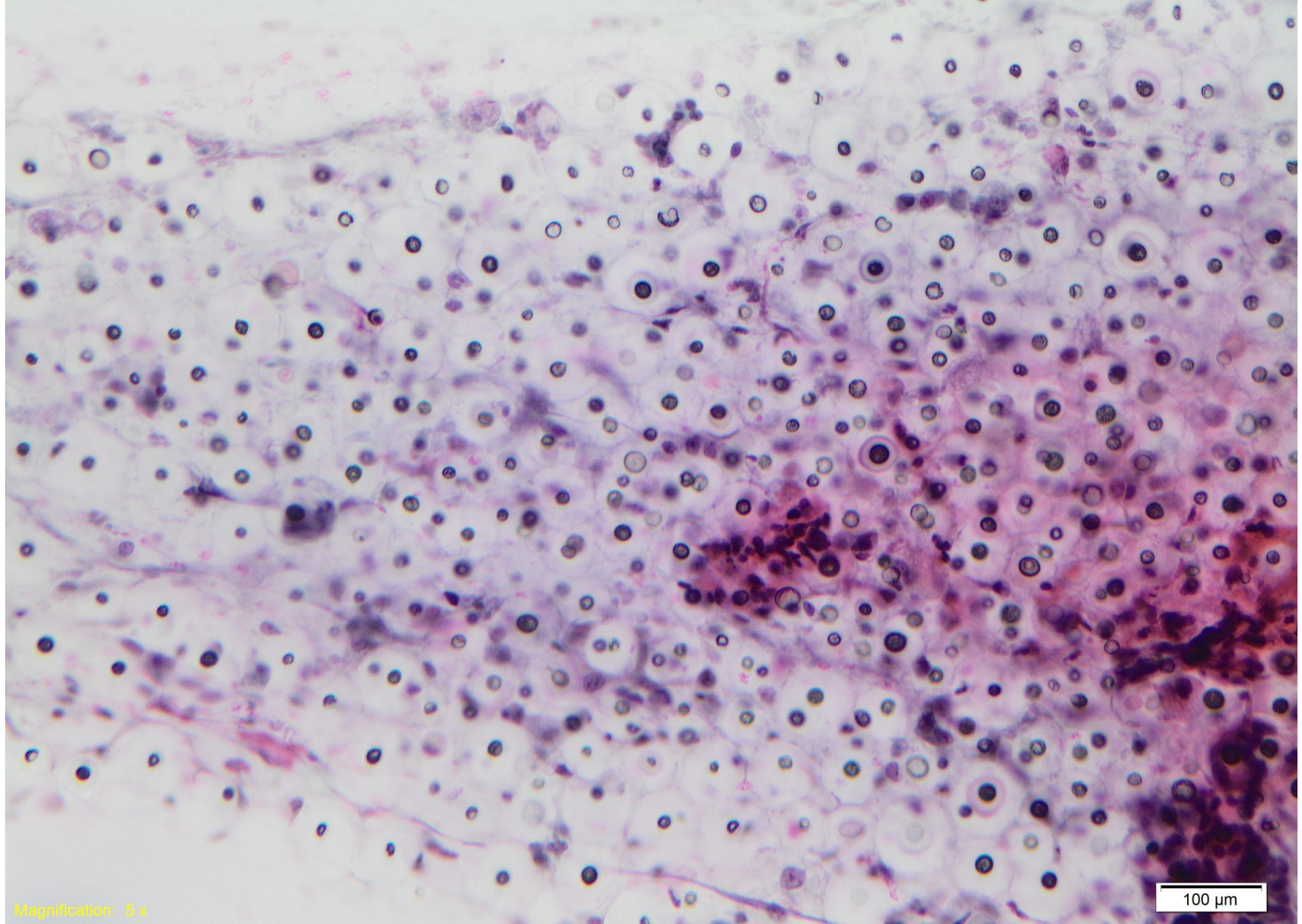
Magnification: 5 x

100 μ m



Magnification: 5 x

100 μ m



Magnification: 5 x

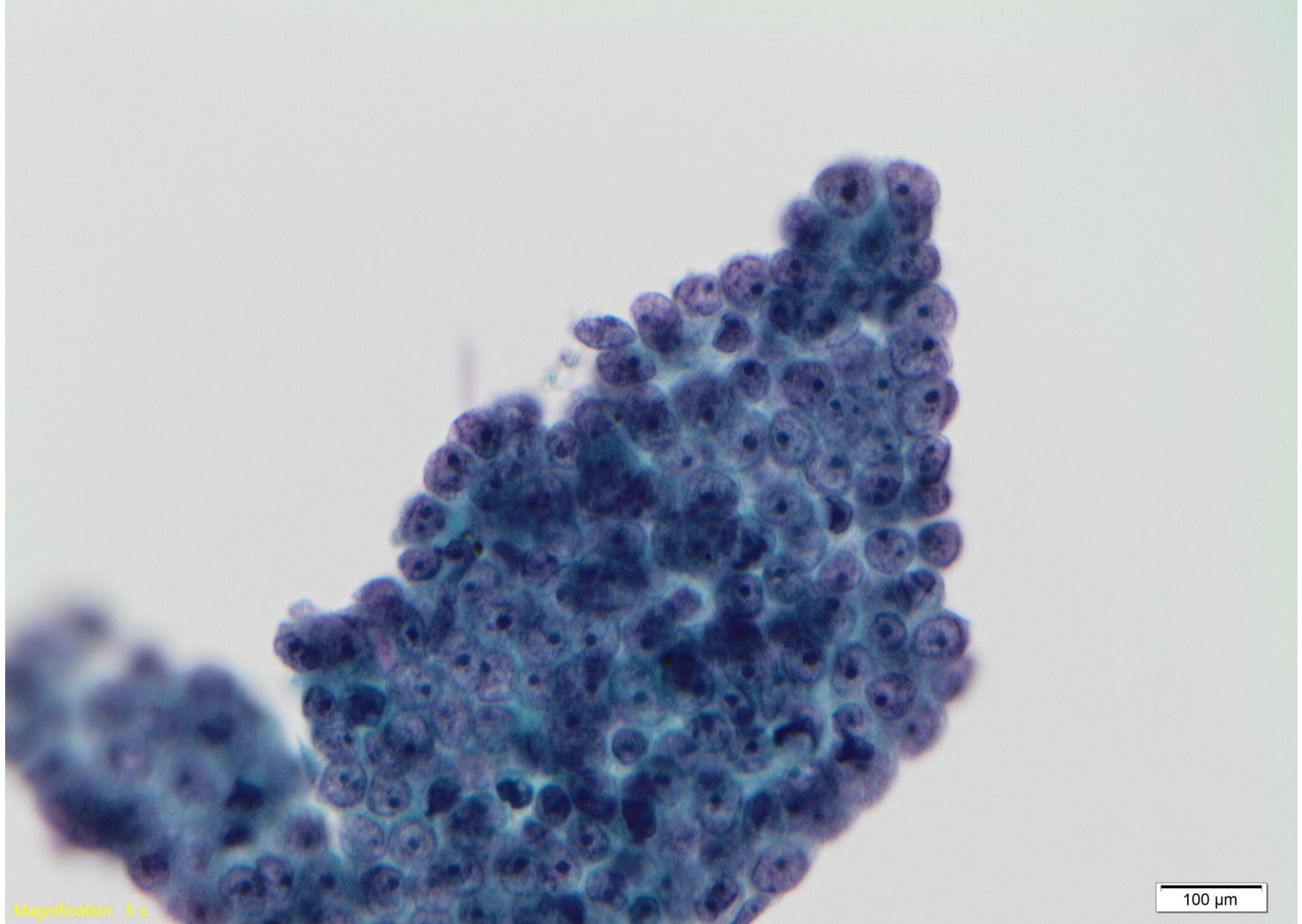
100 μ m

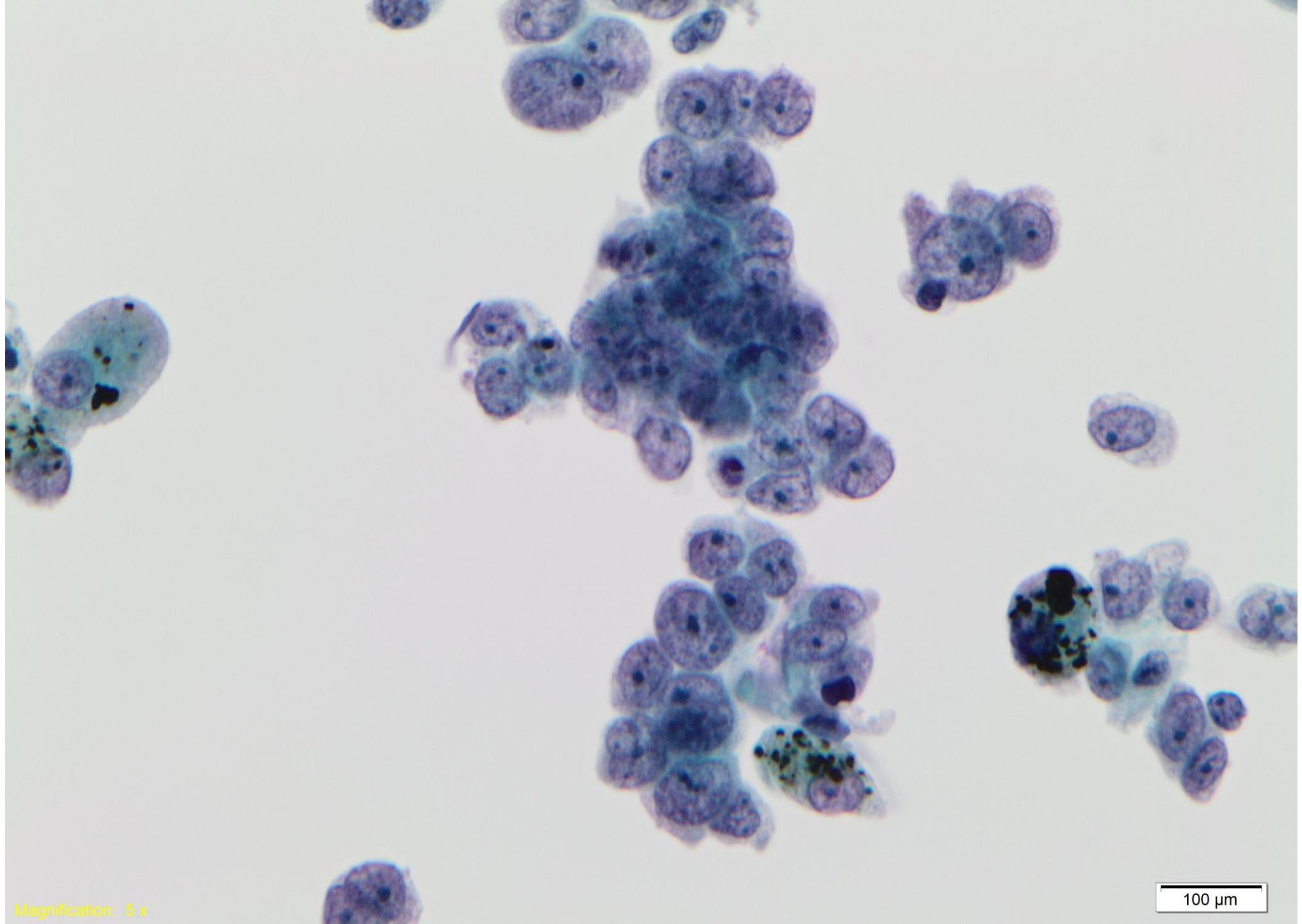
Case 15

F65. Bronchial brushings

Magnification: 5 x

100 μ m



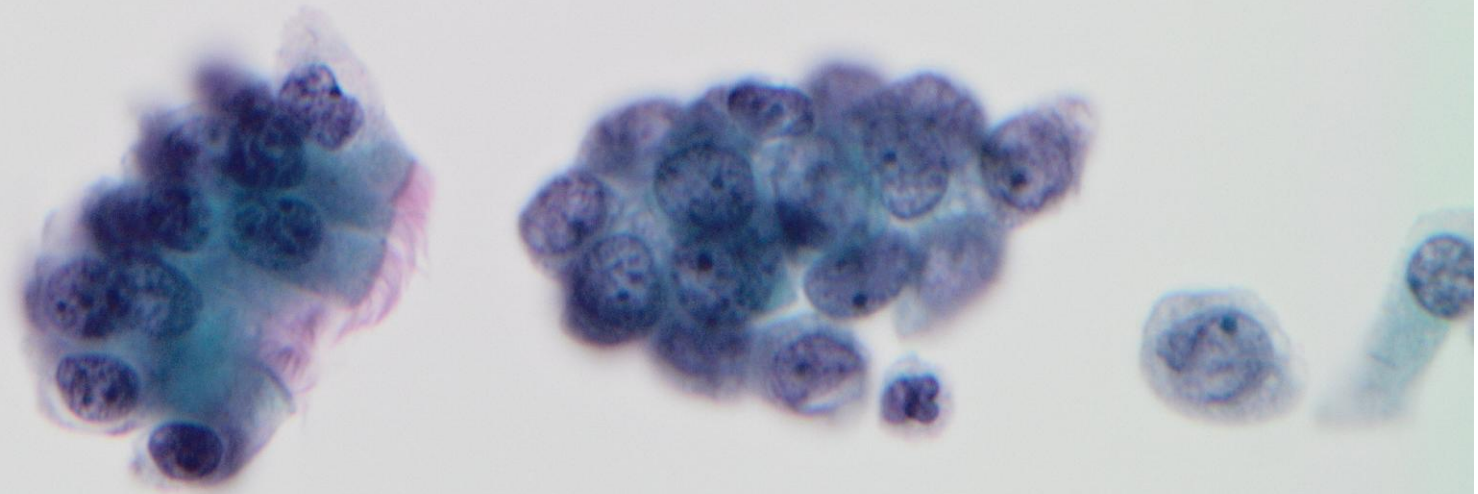


Magnification: 5 x

100 μm

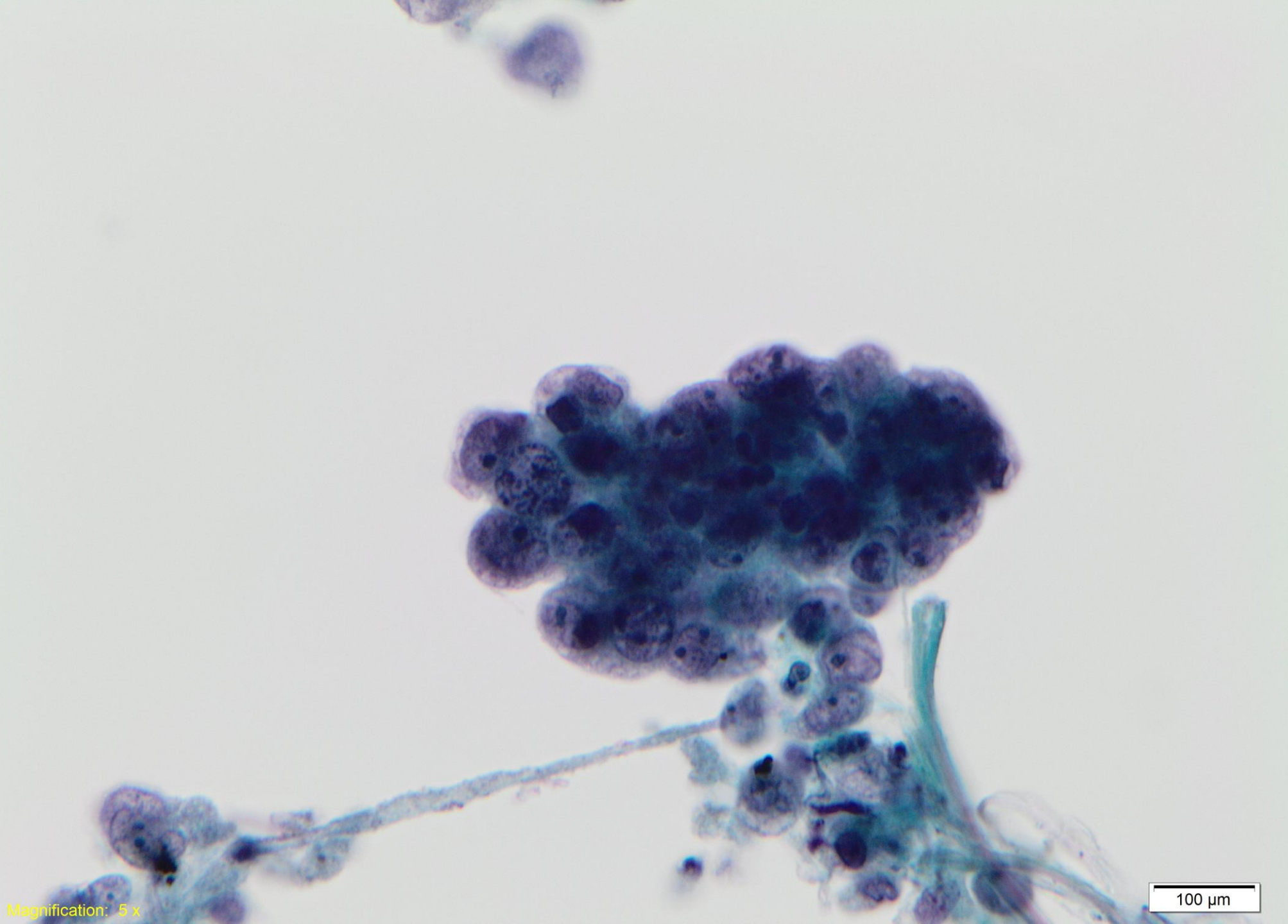
Magnification: 5 x

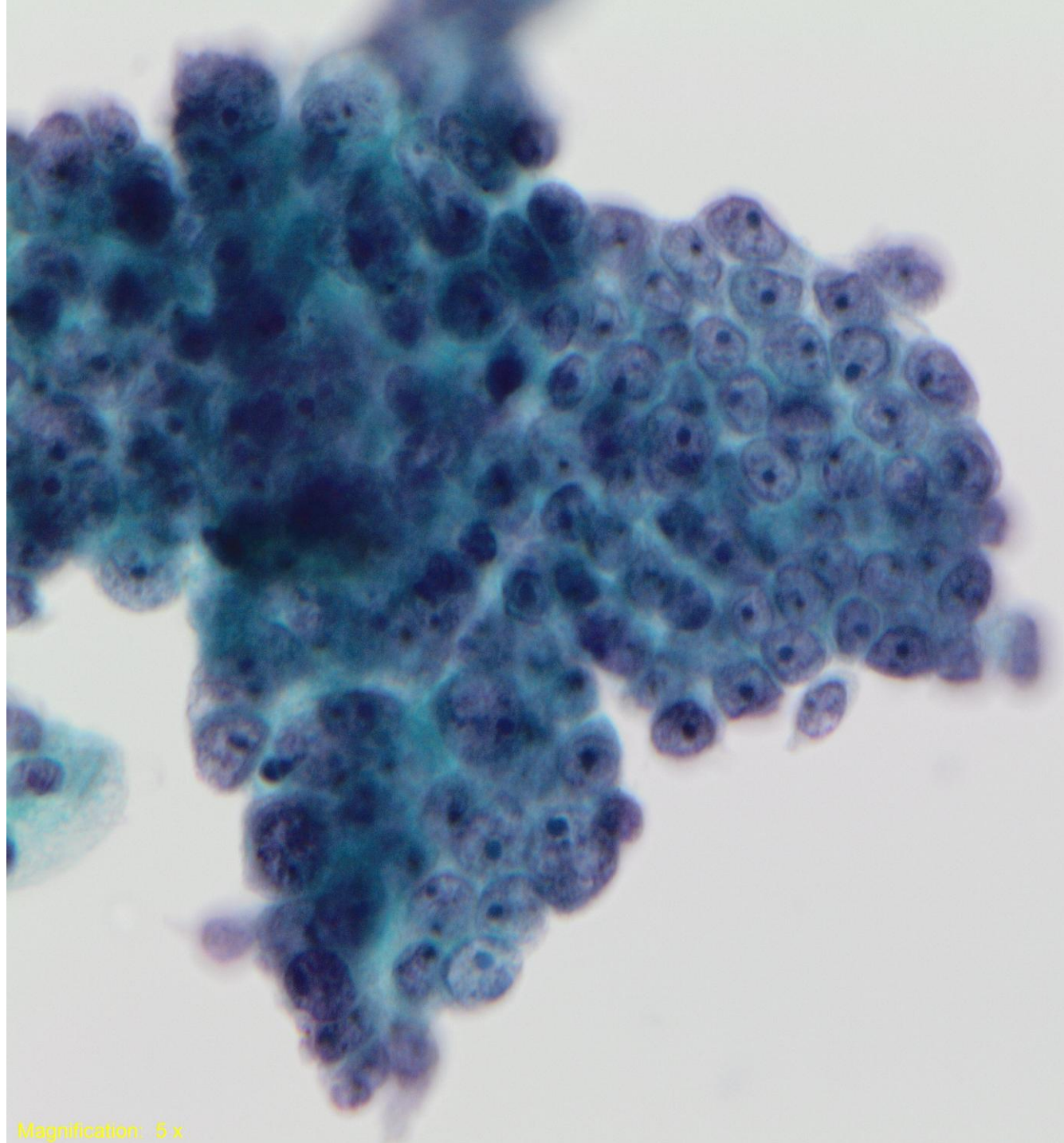
100 μ m



Magnification: 5 x

100 μ m



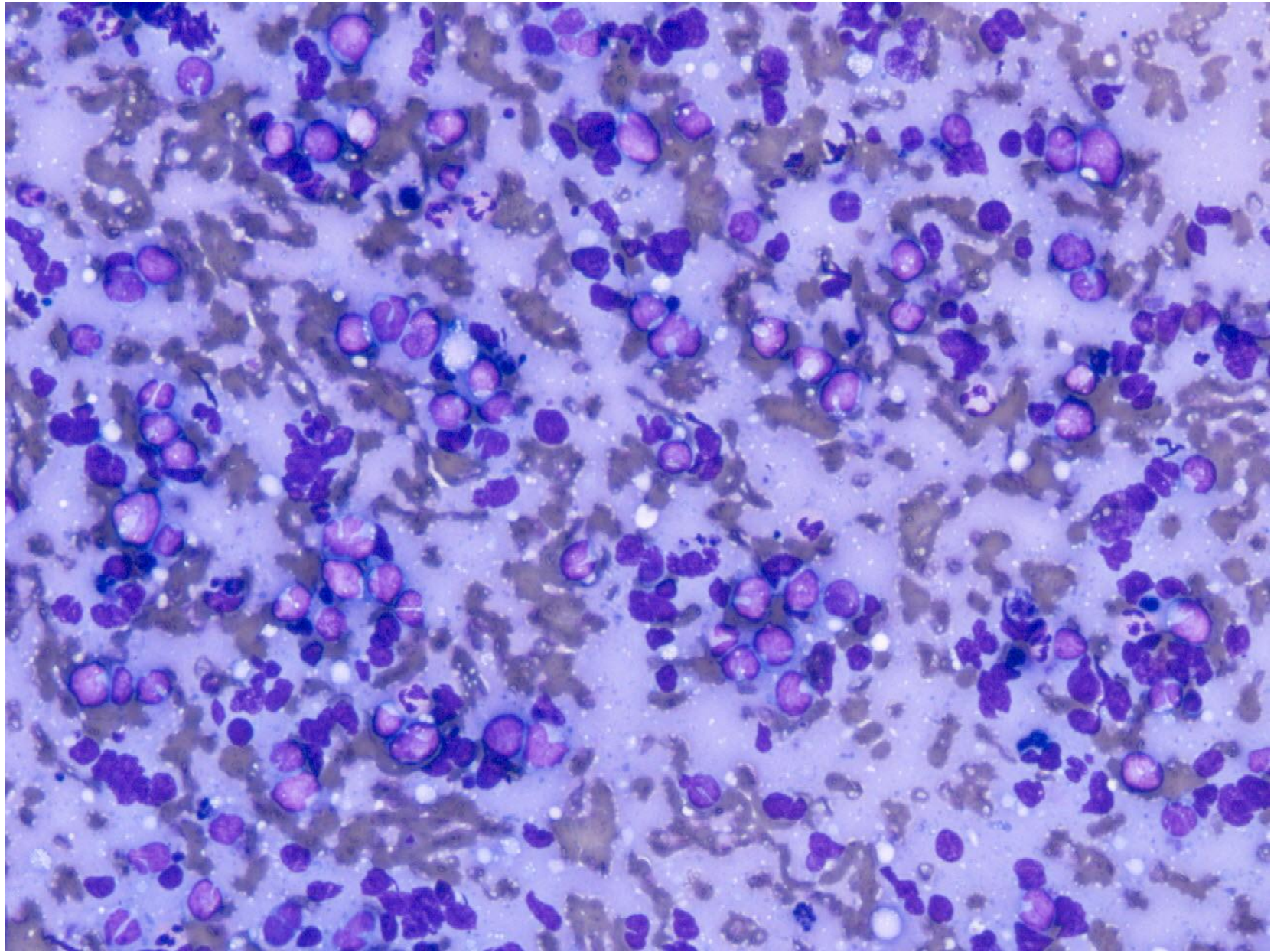


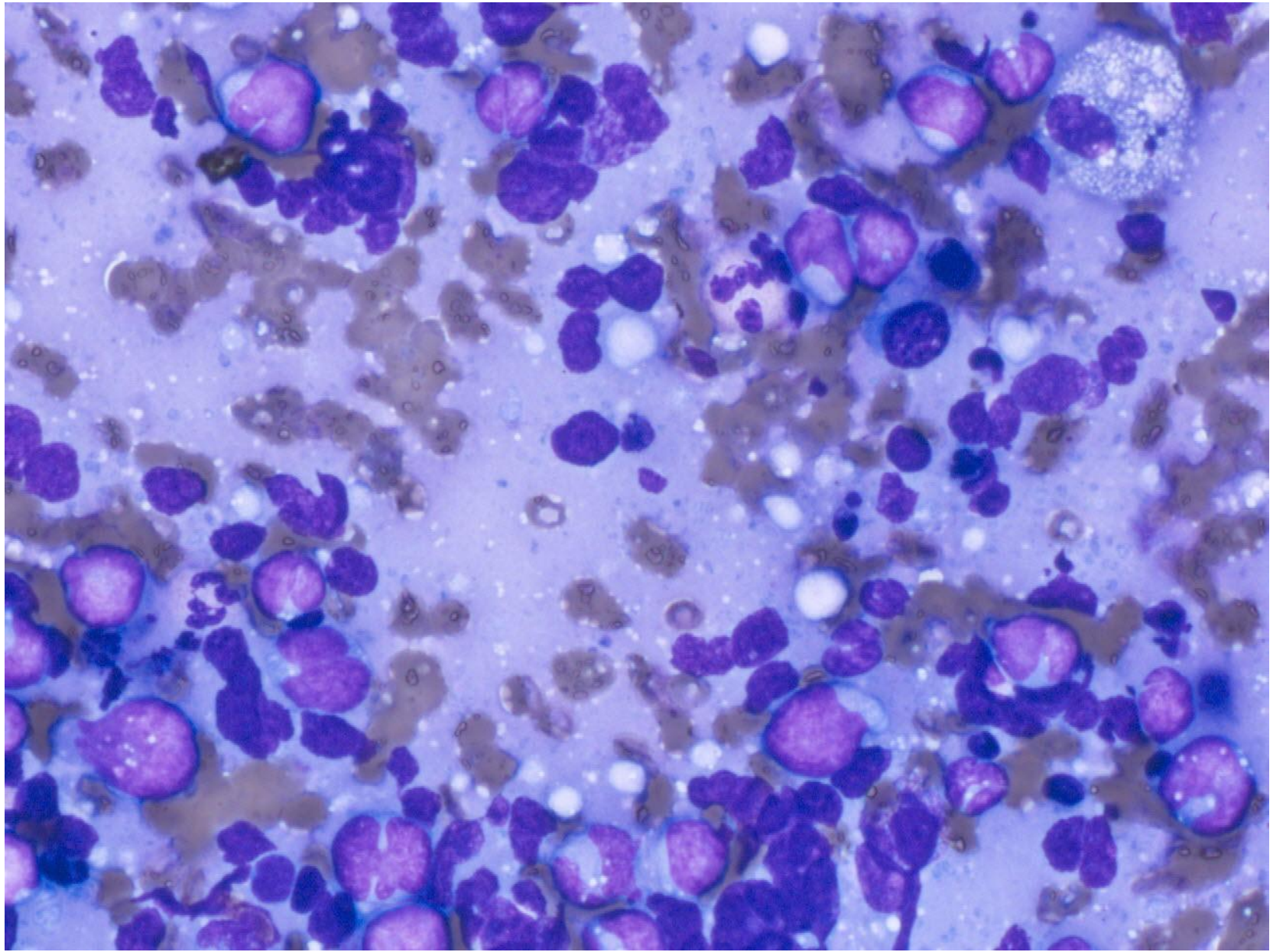
Magnification: 5 x

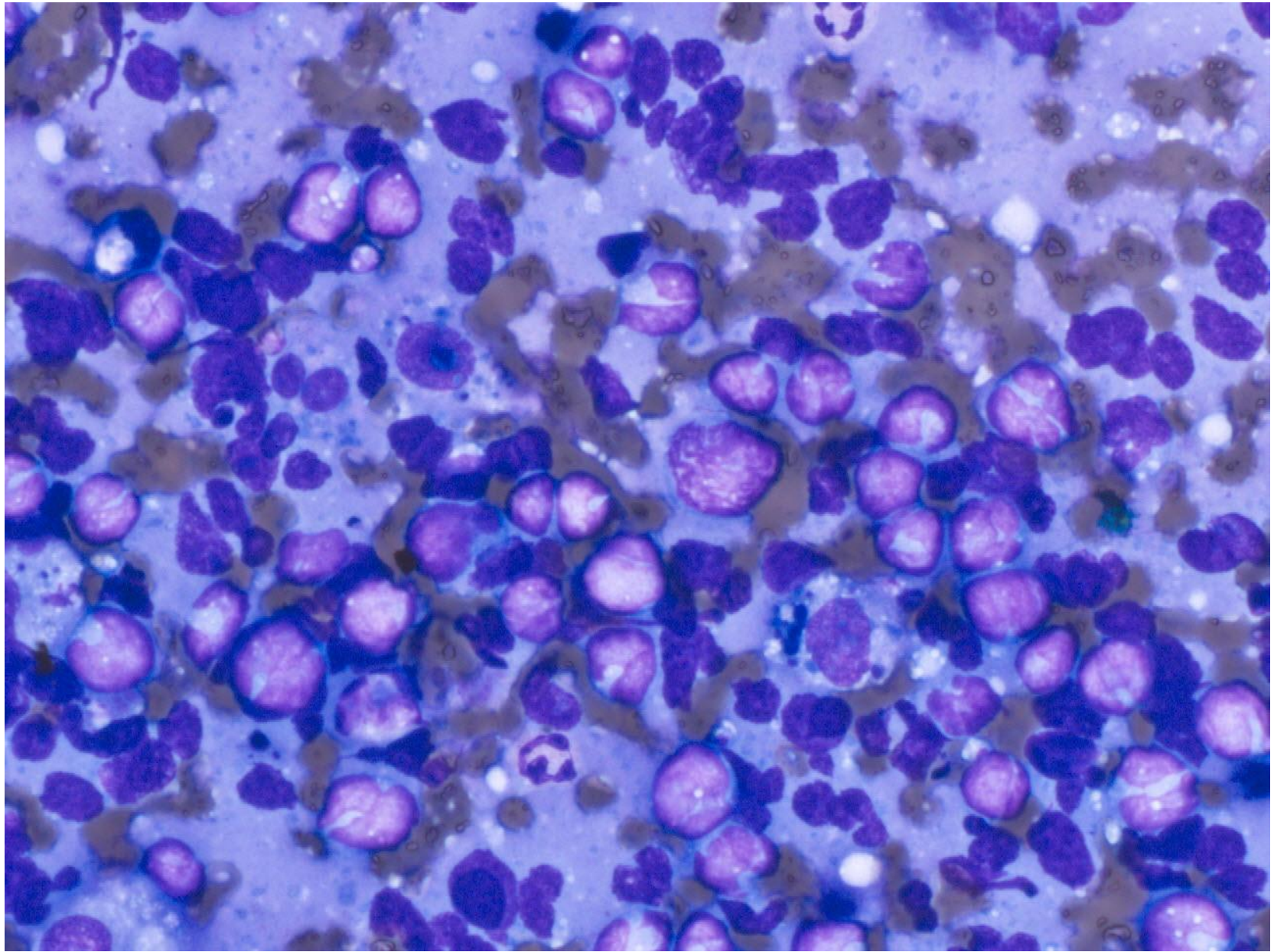
100 μ m

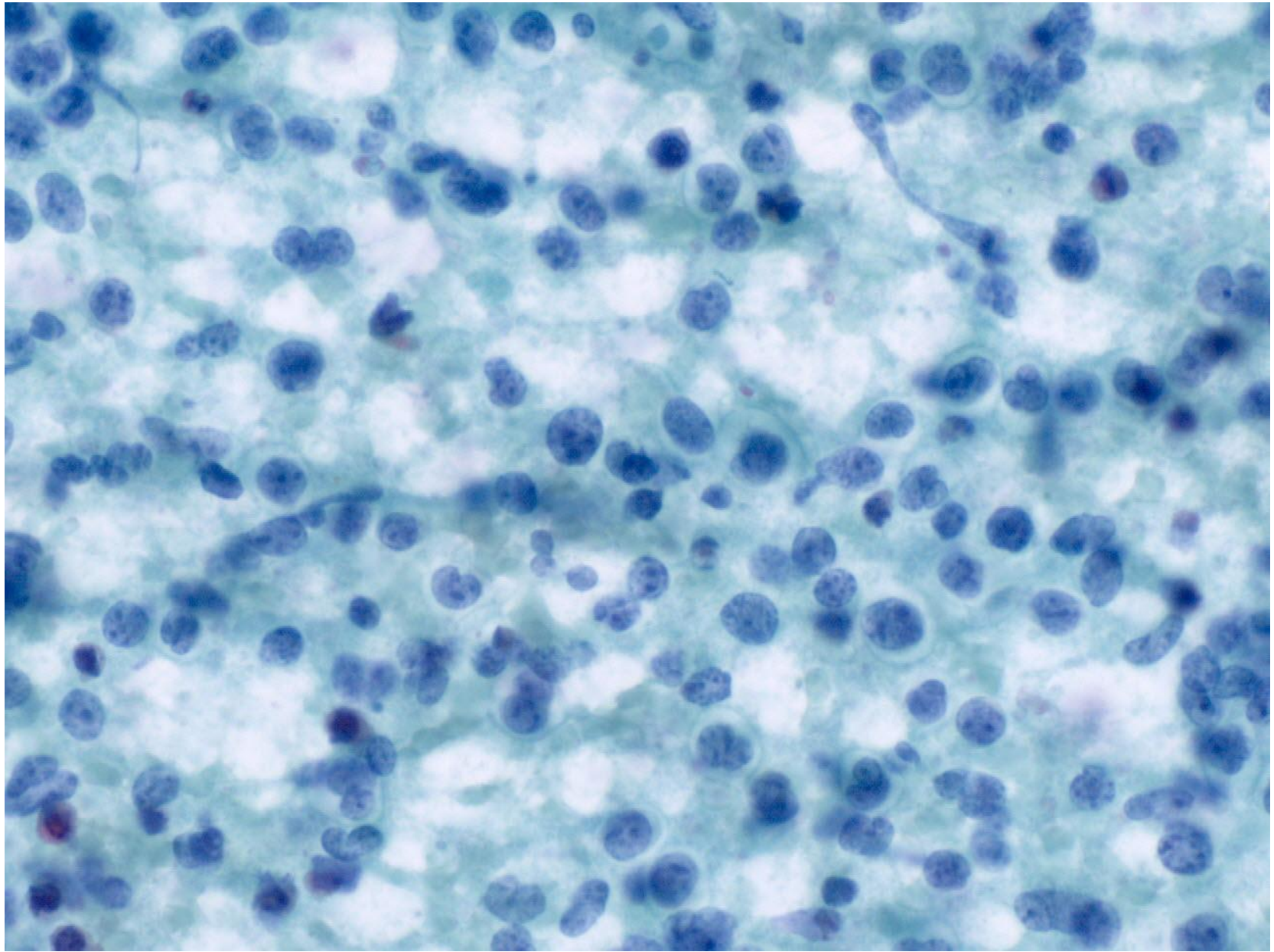
Case 16

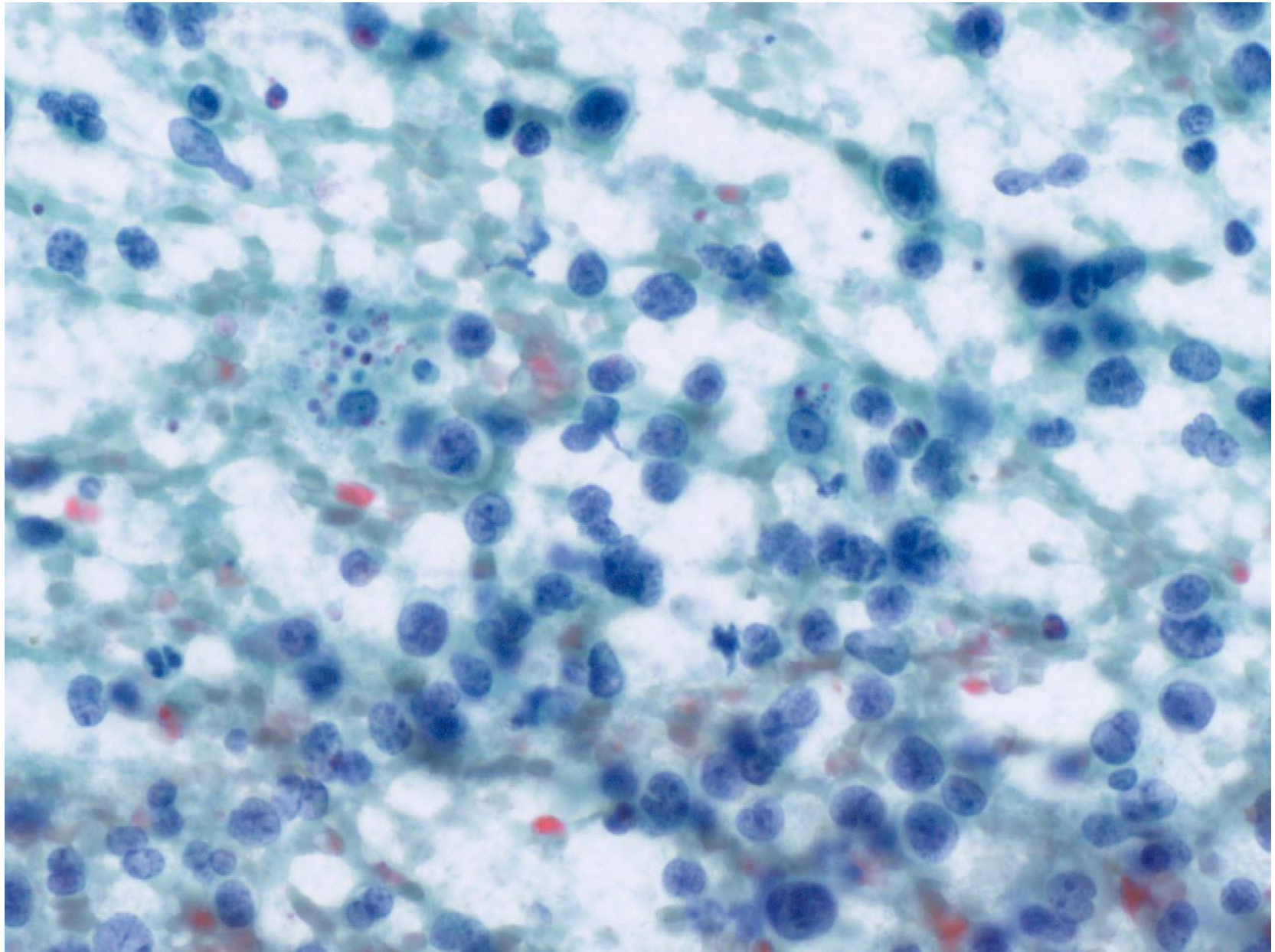
M62. FNA para-aortic LN.





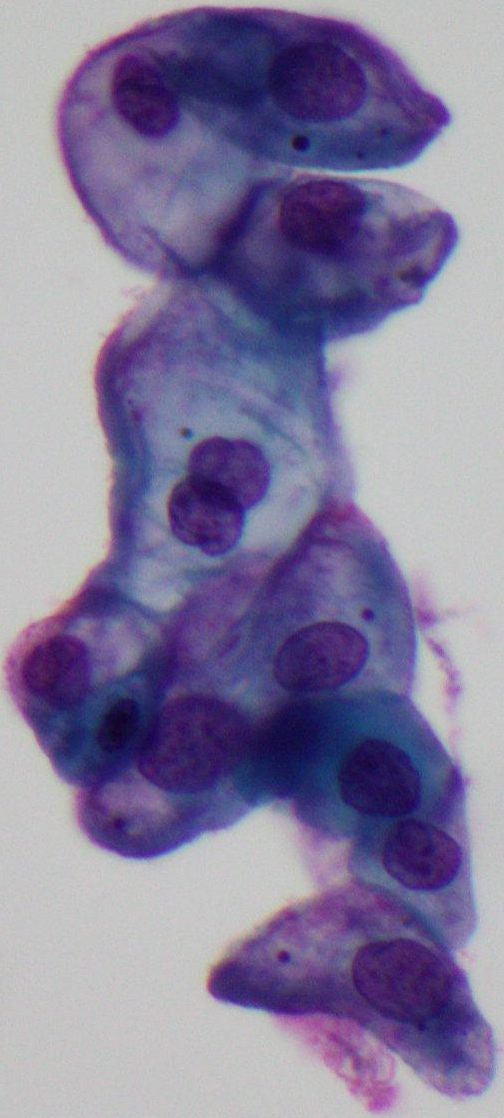


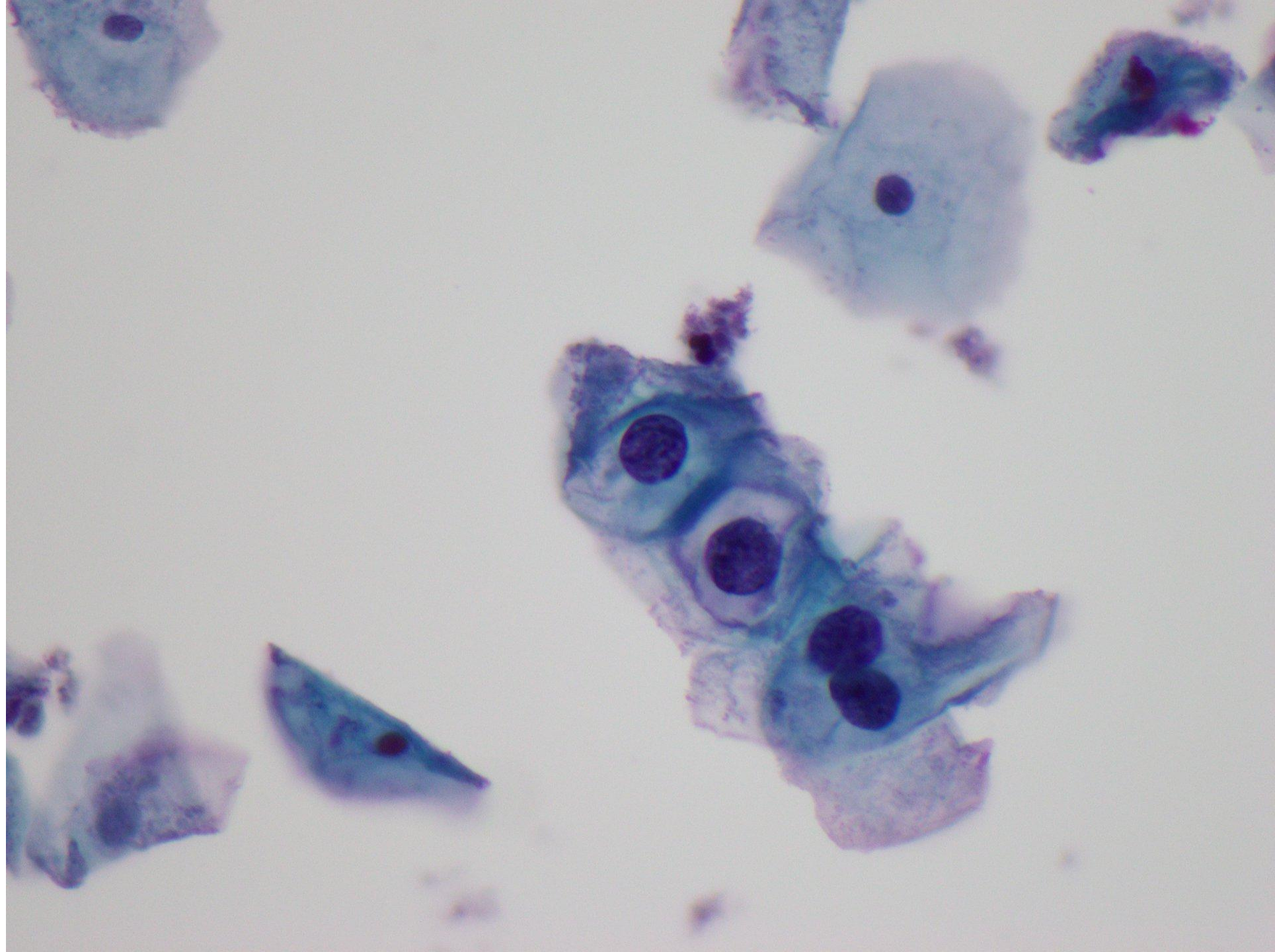


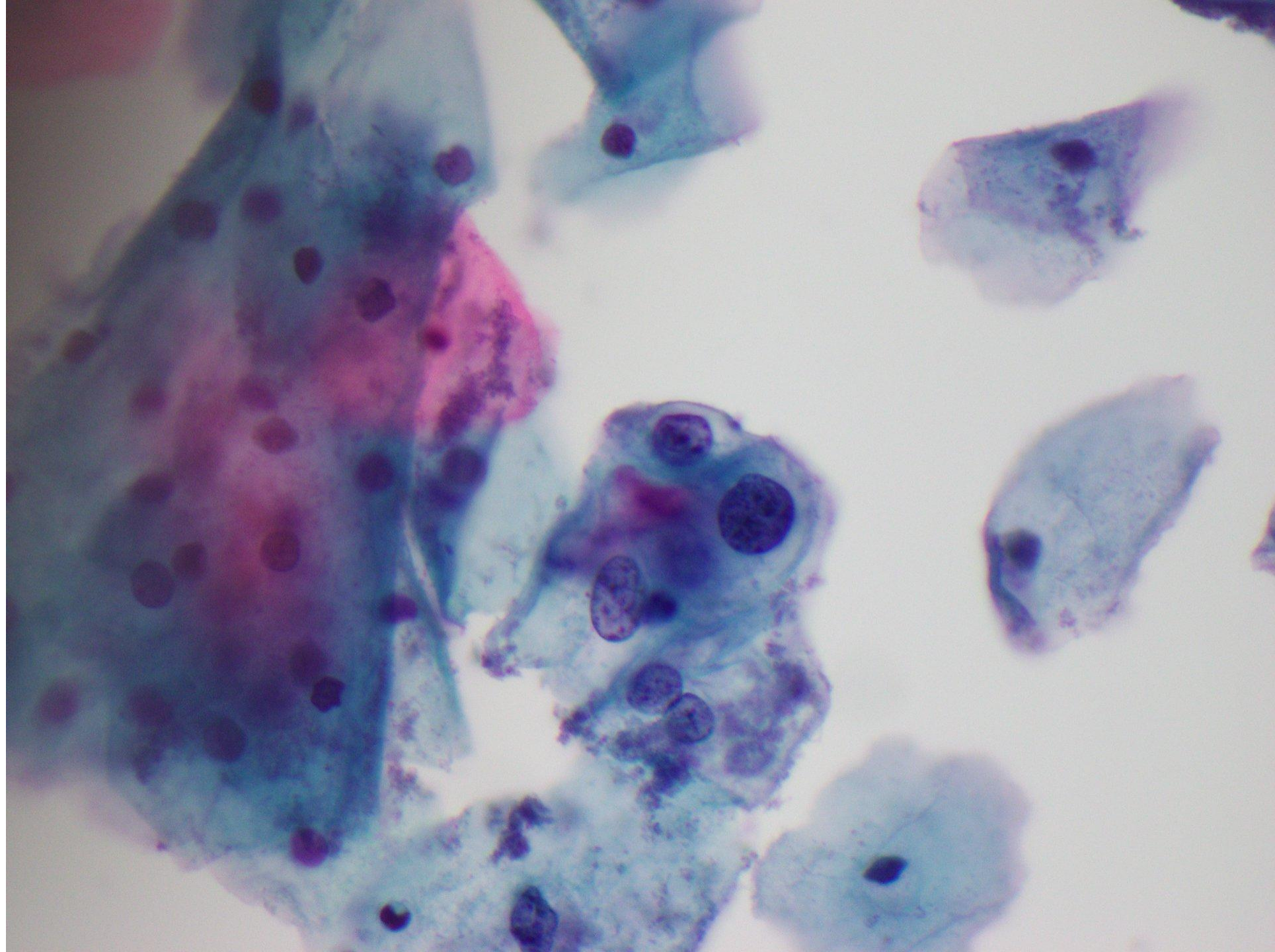


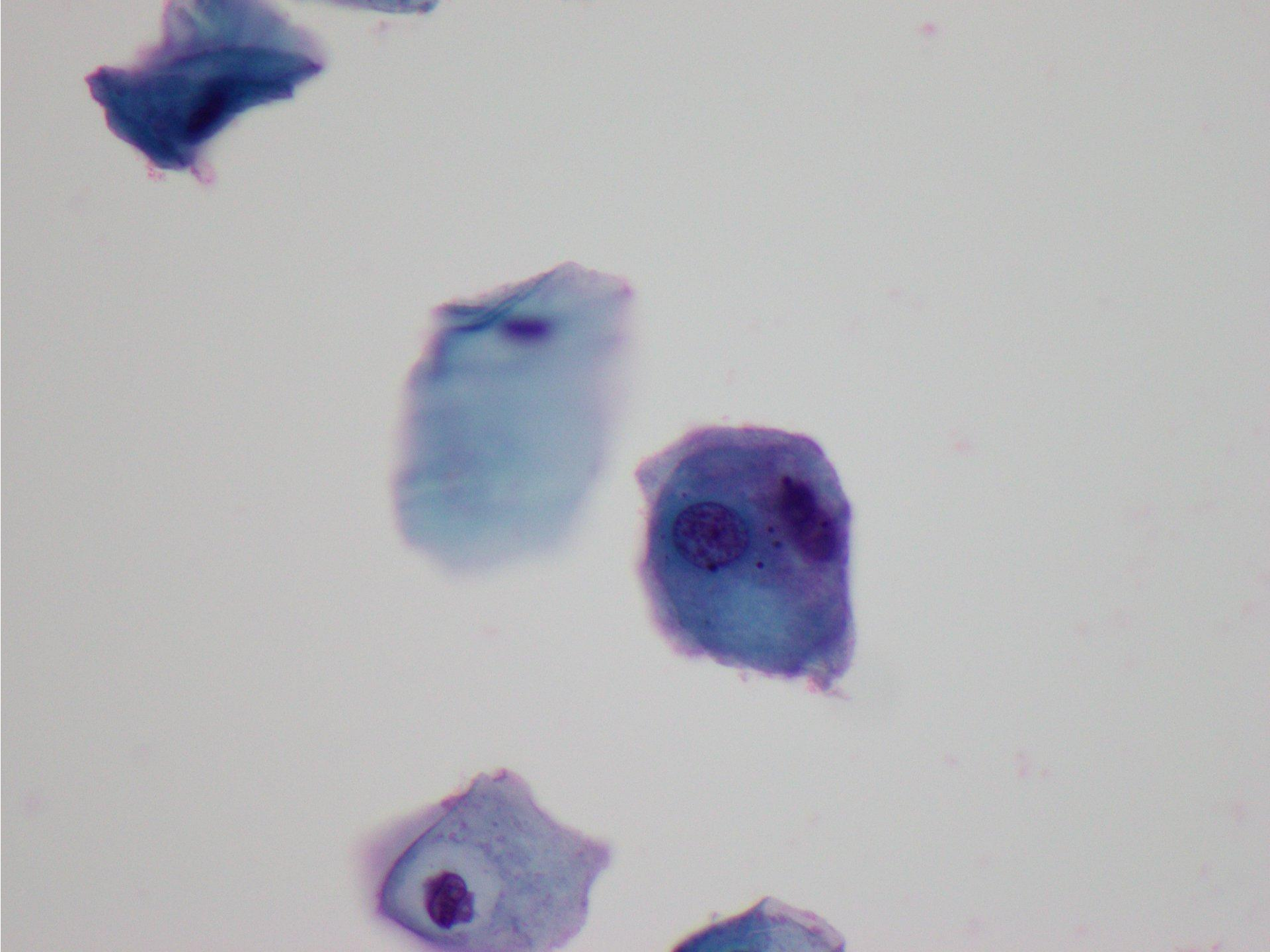
Case 17

F38. Routine cervical screening. LBC



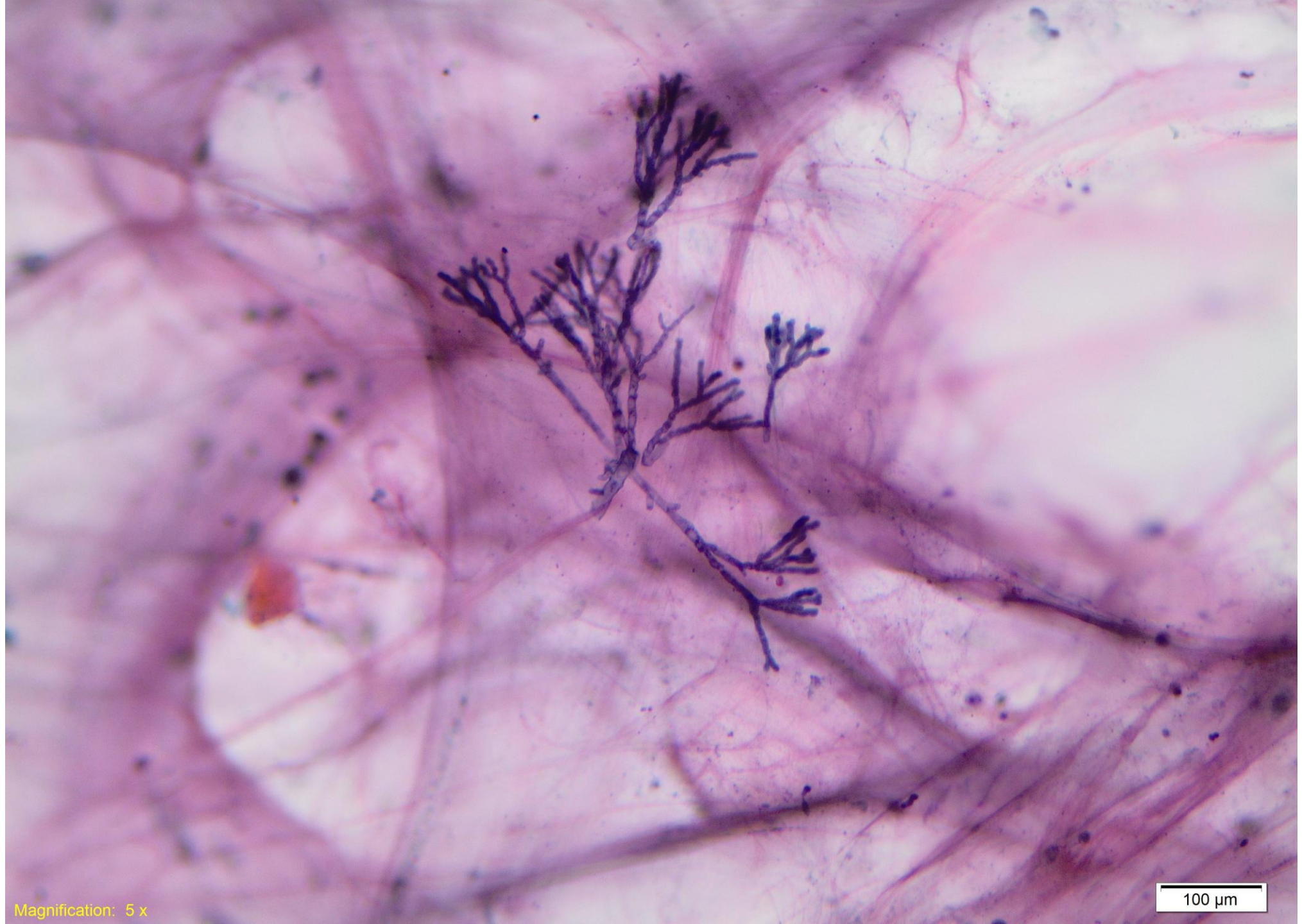






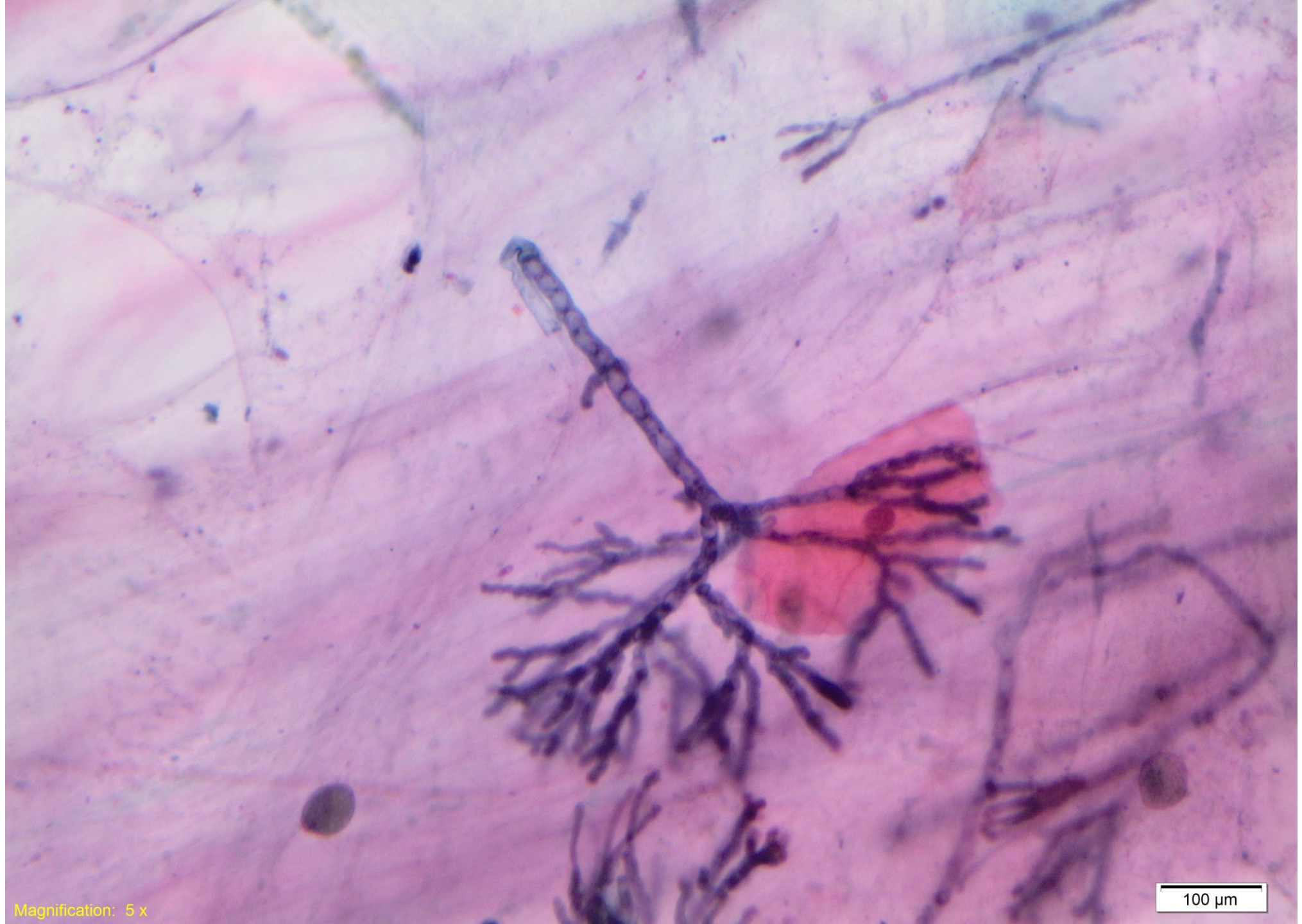Case 18

M80. Chronic cough. Sputum.



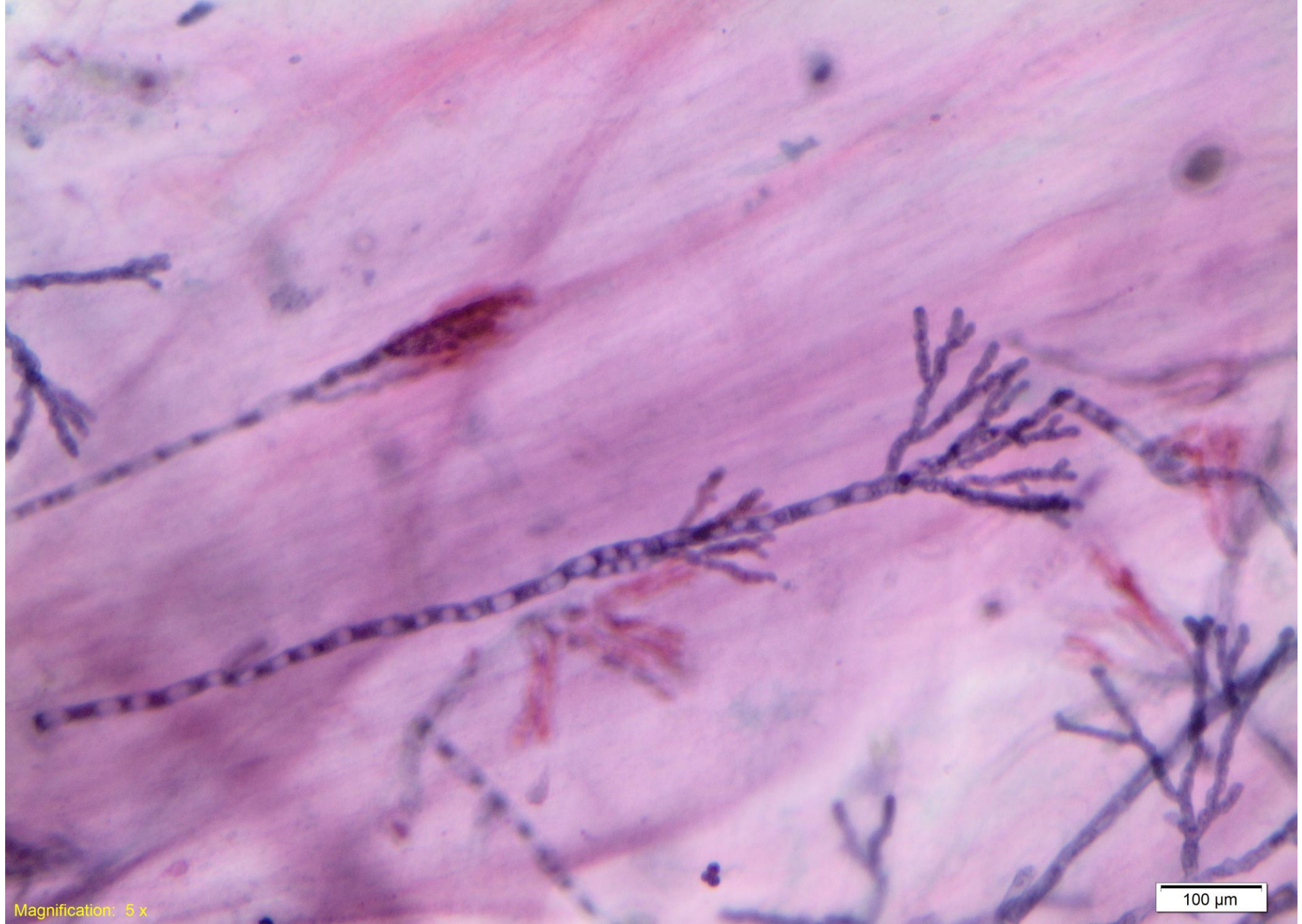
Magnification: 5 x

100 μm



Magnification: 5 x

100 μ m

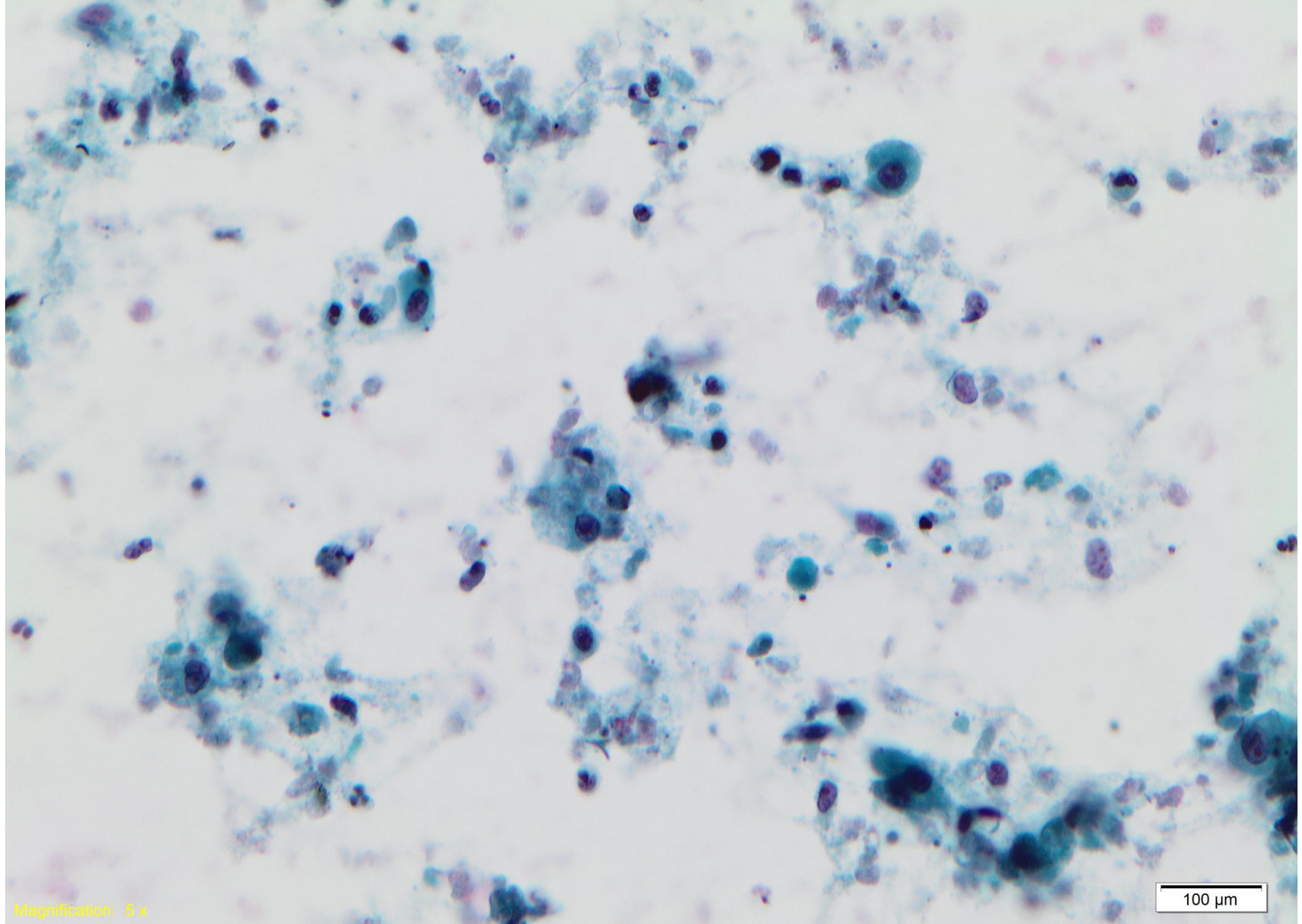


Magnification: 5 x

100 μm

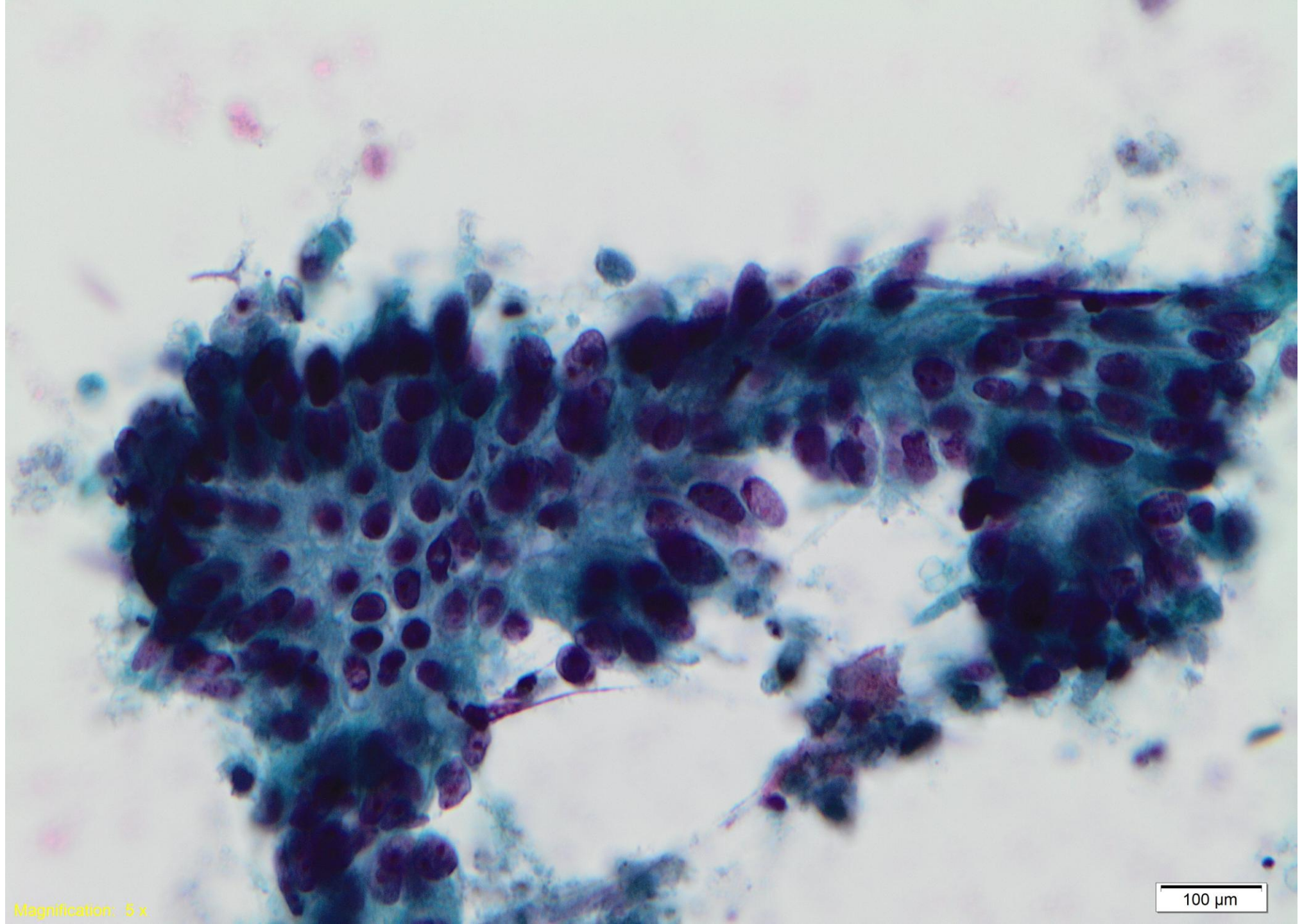
Case 19

M65. FNA Lung mass. Multiple lung nodules.



Magnification: 5 x

100 μ m

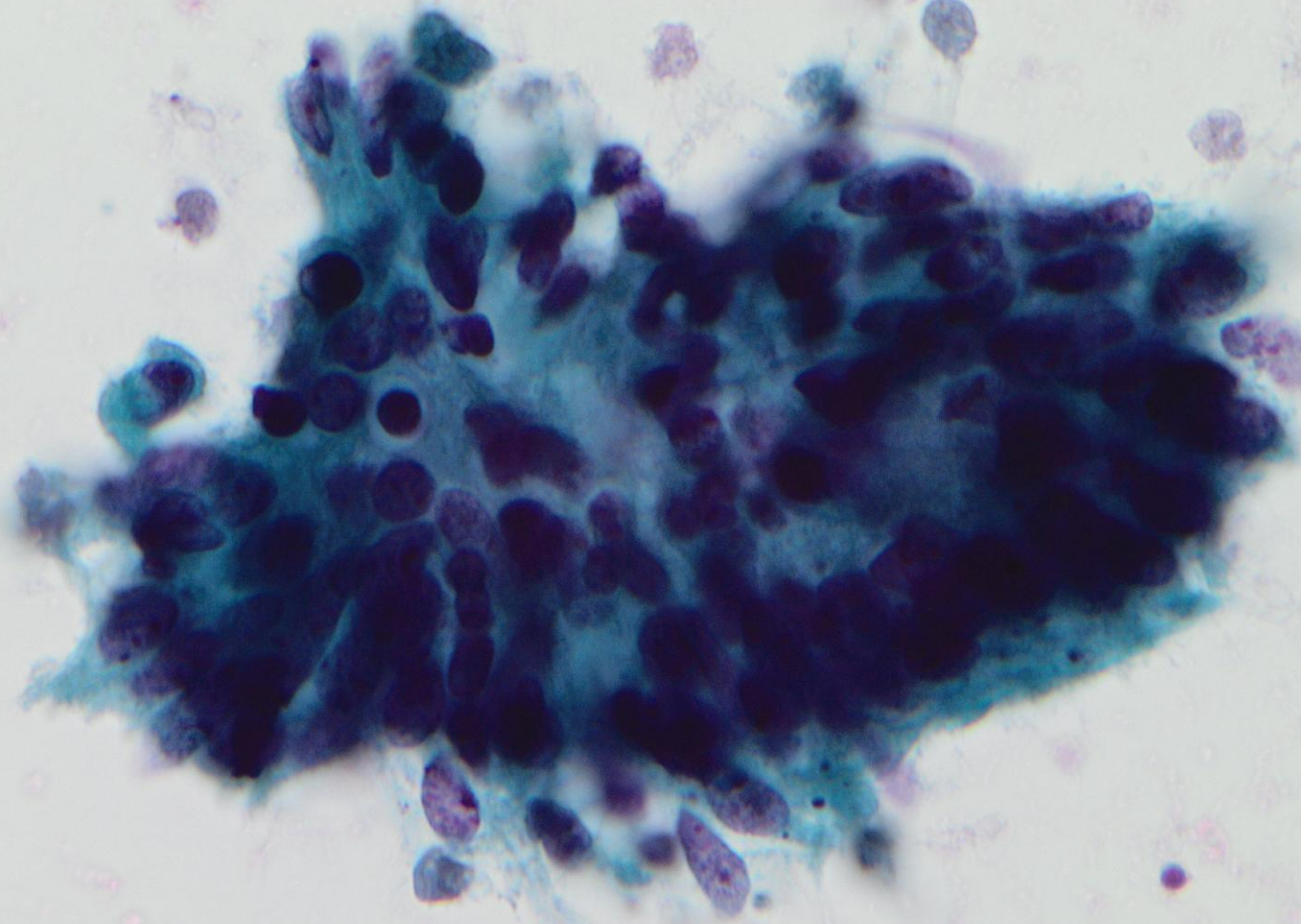


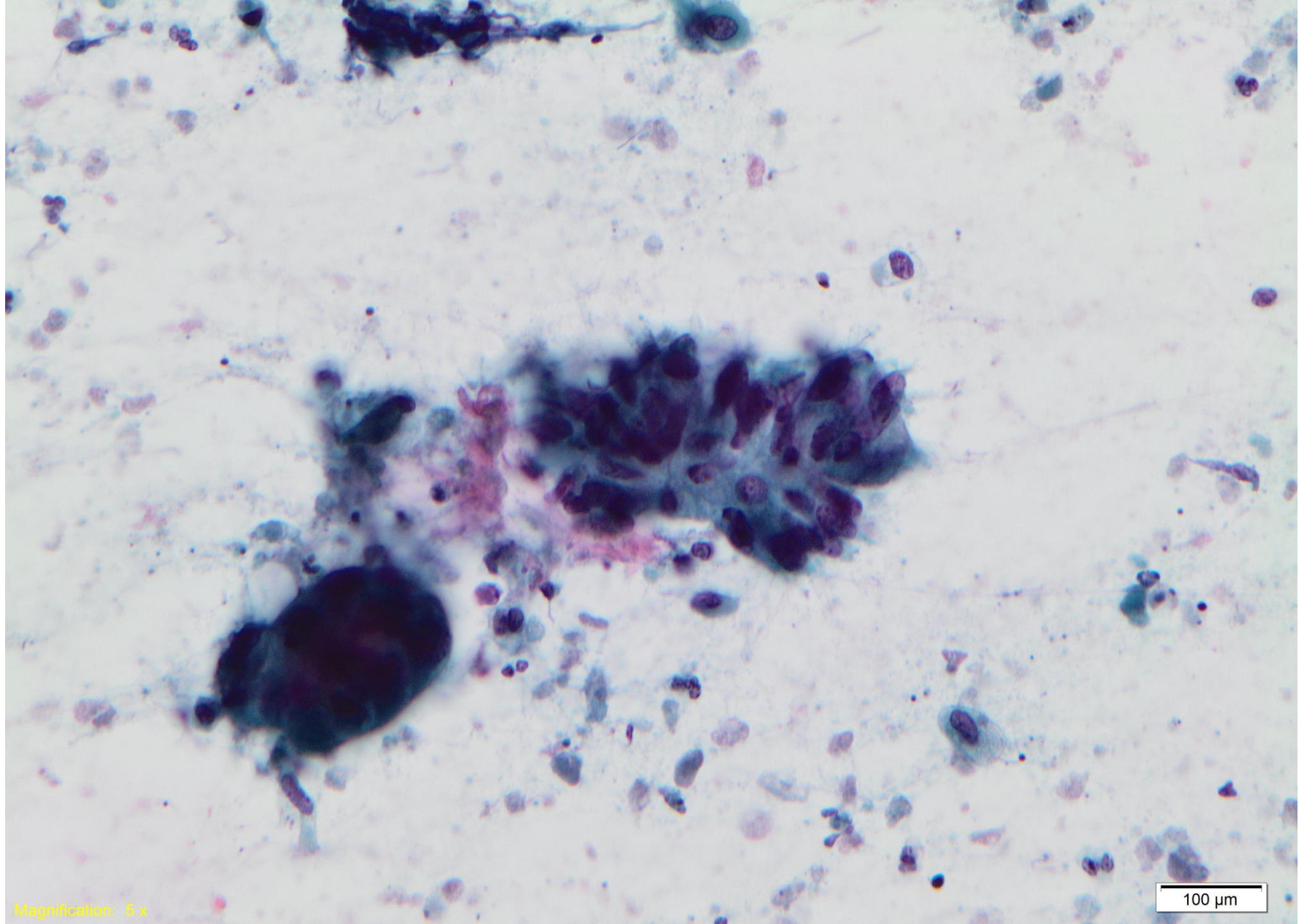
Magnification: 5 x

100 μm

Magnification: 5 x

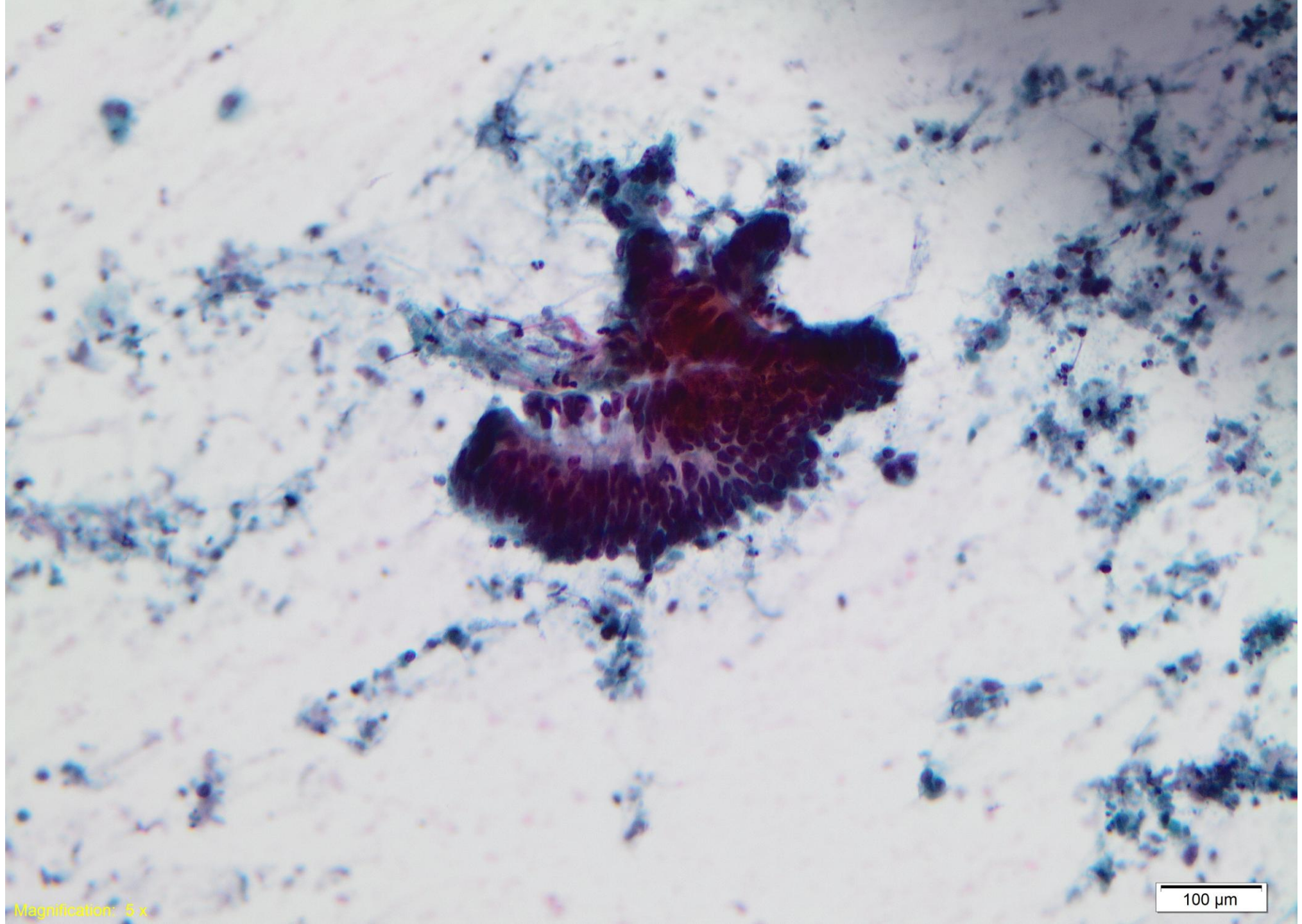
100 μ m





Magnification: 5 x

100 μ m

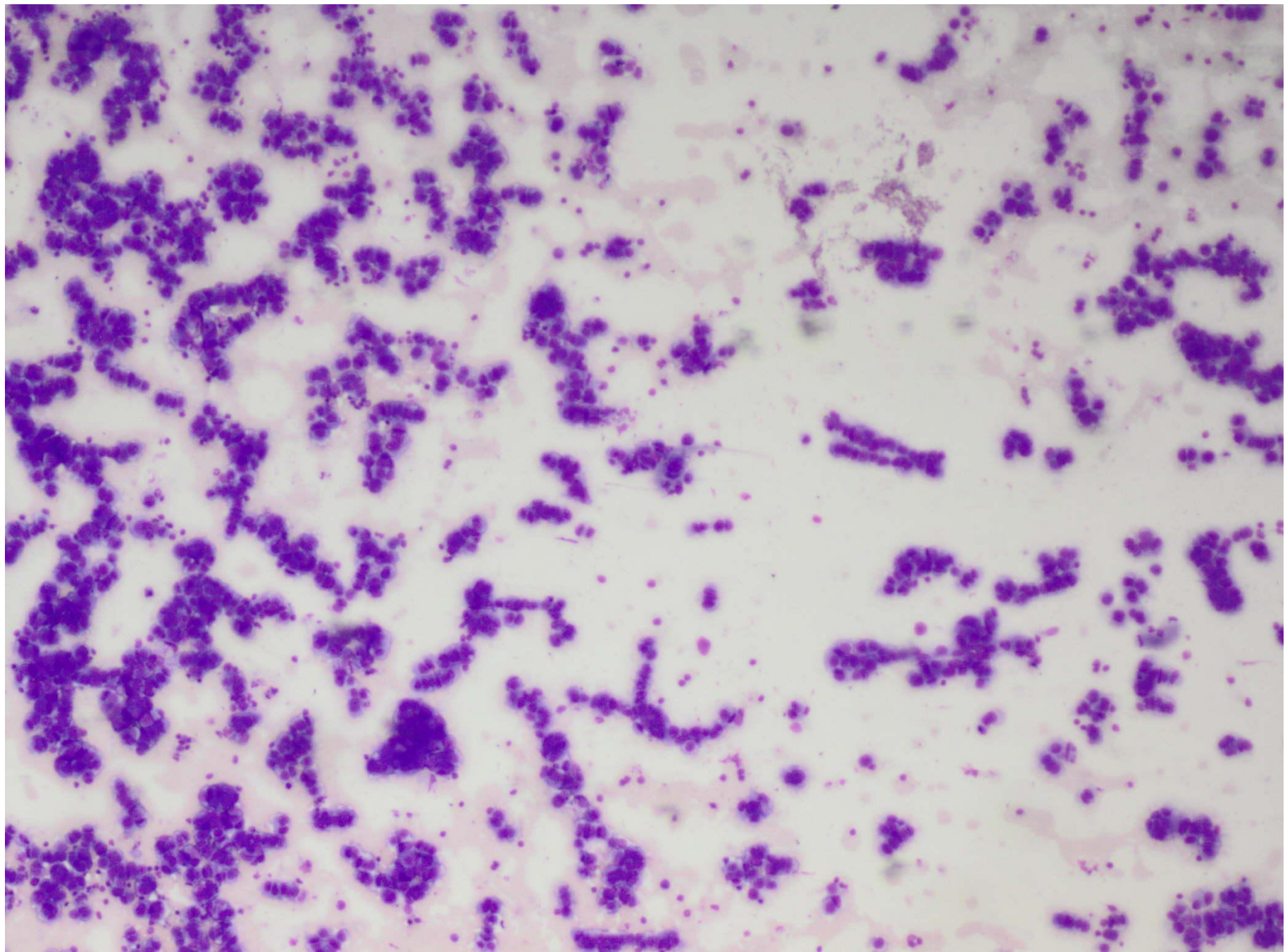


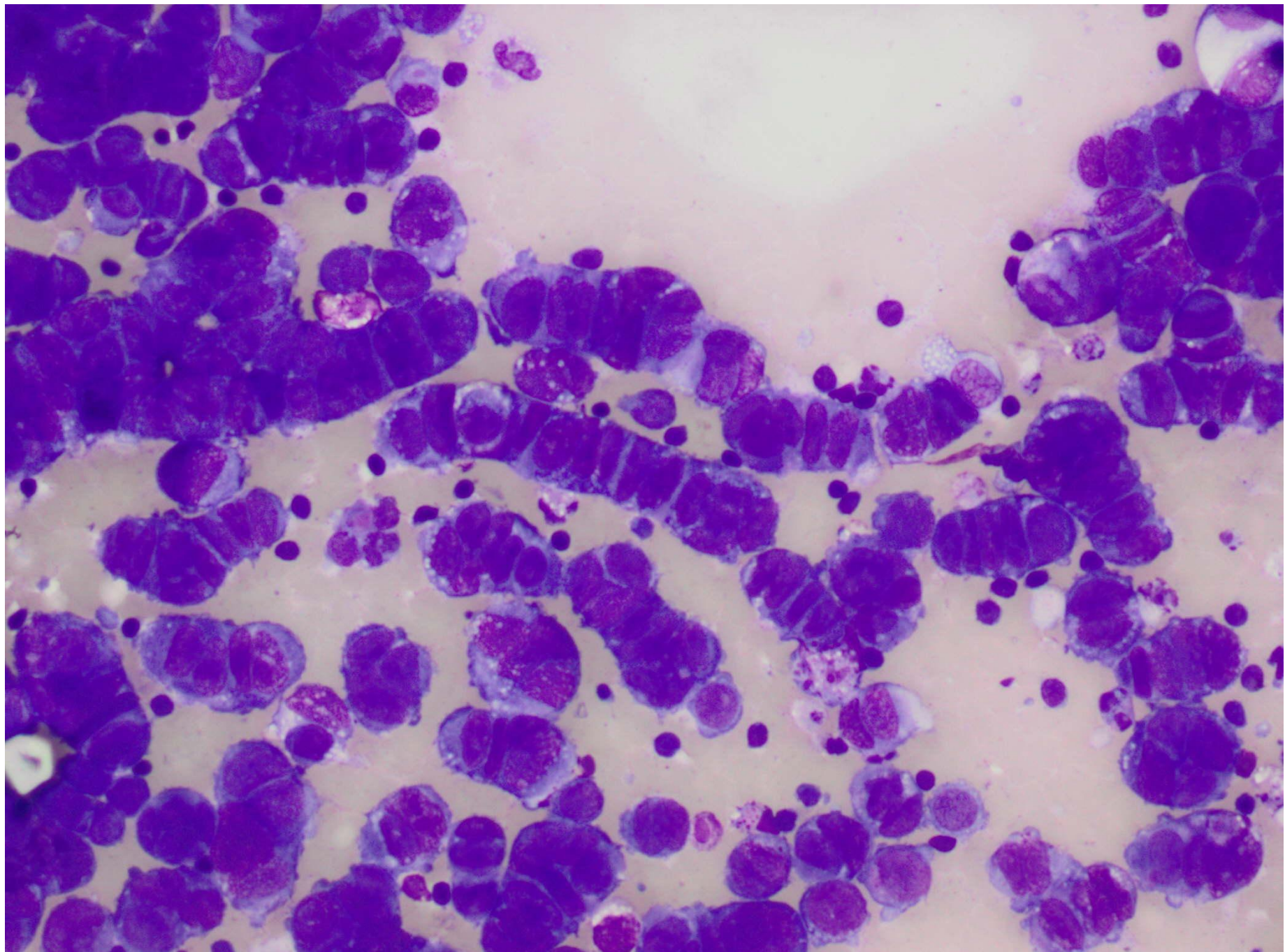
Magnification: 5 x

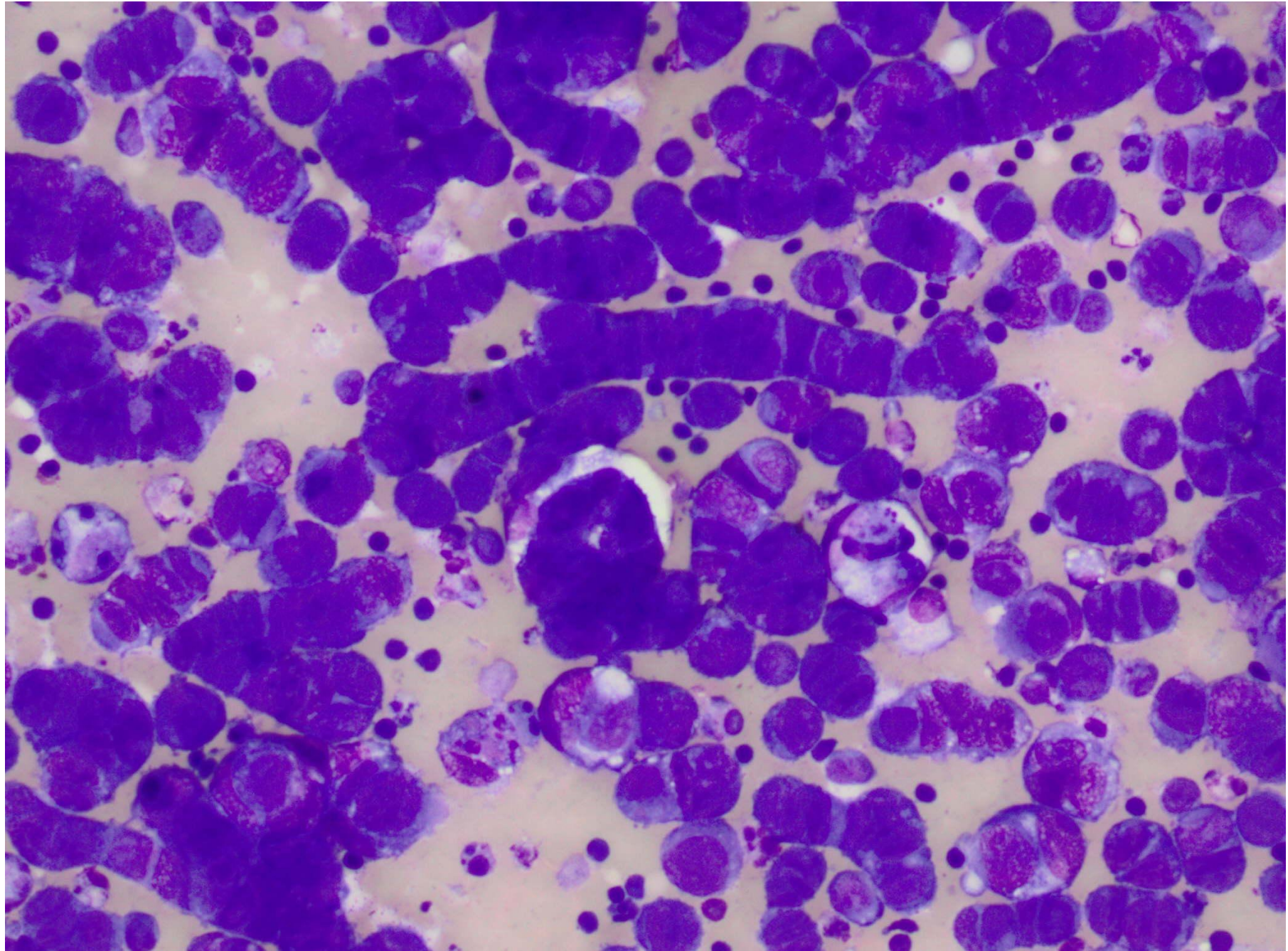
100 μm

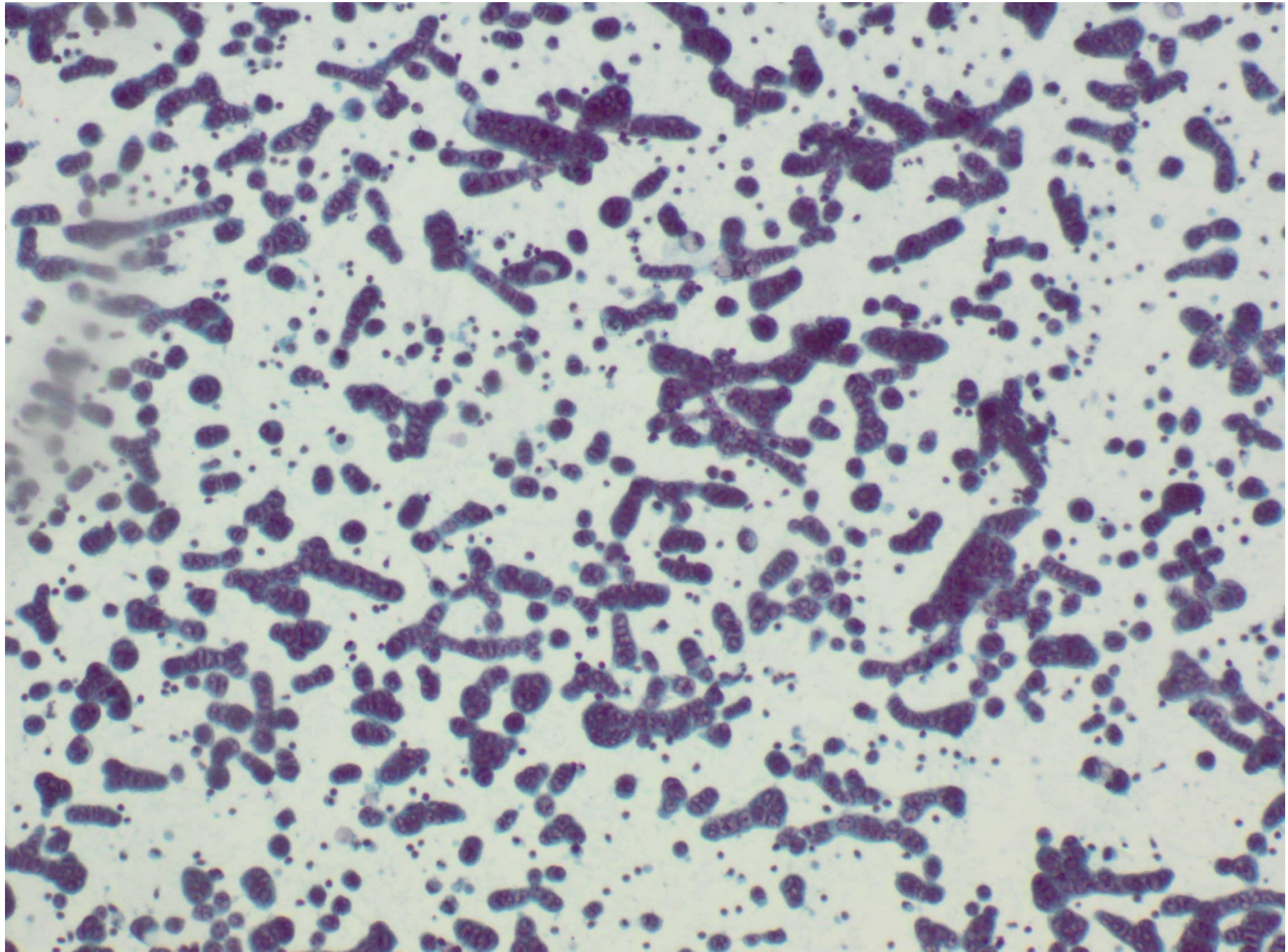
Case 20

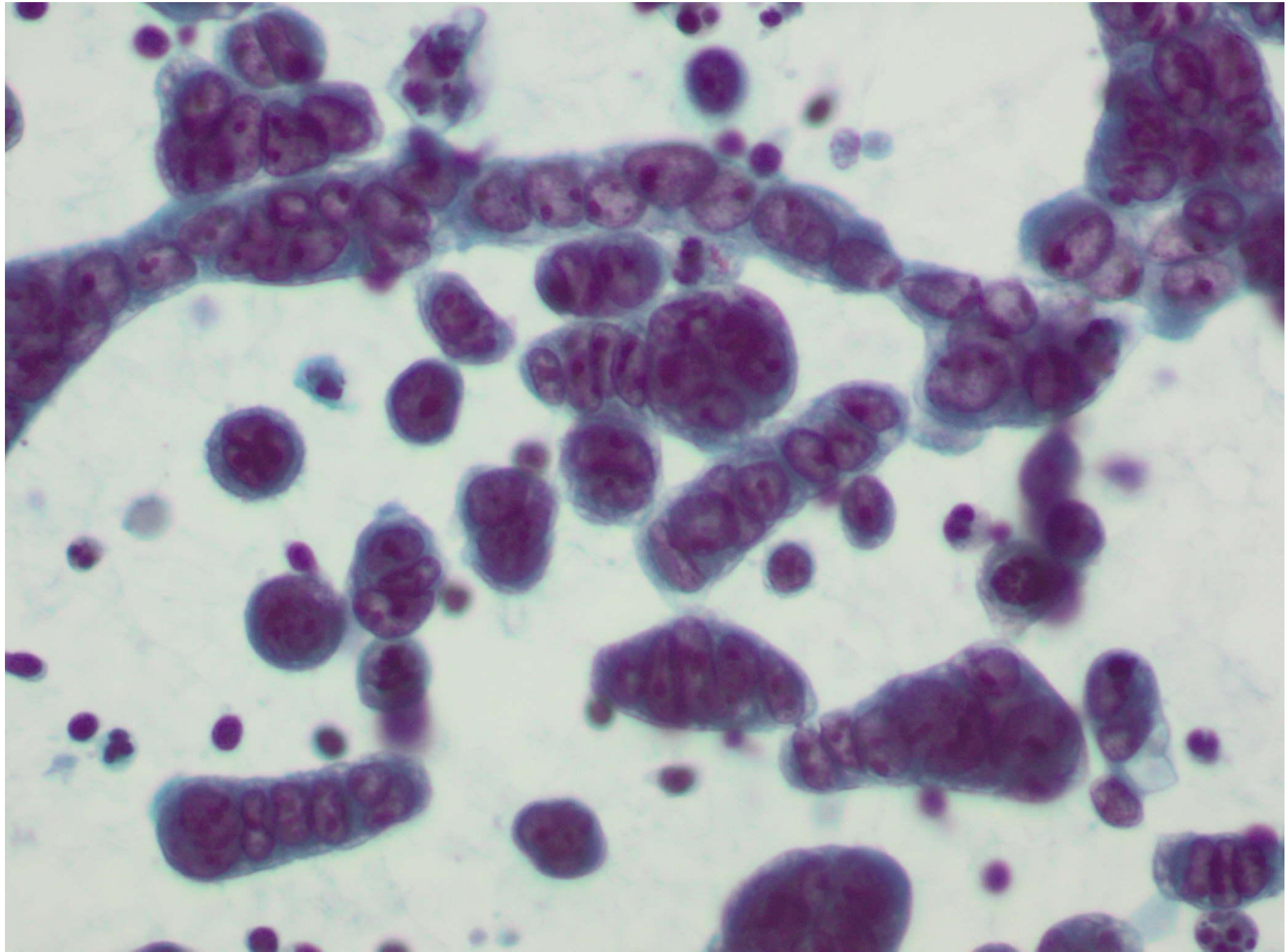
Female 55. Pleural fluid.

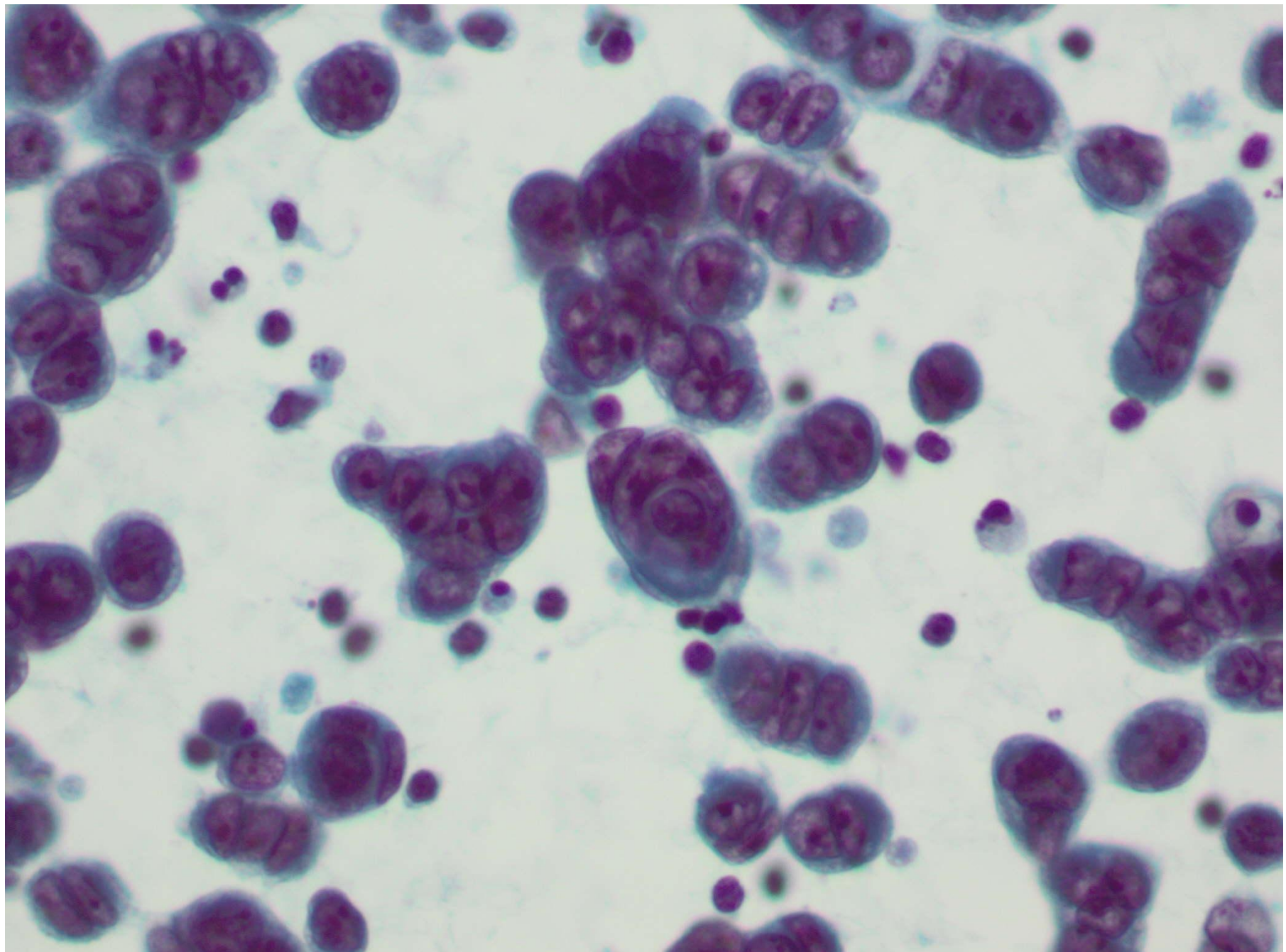






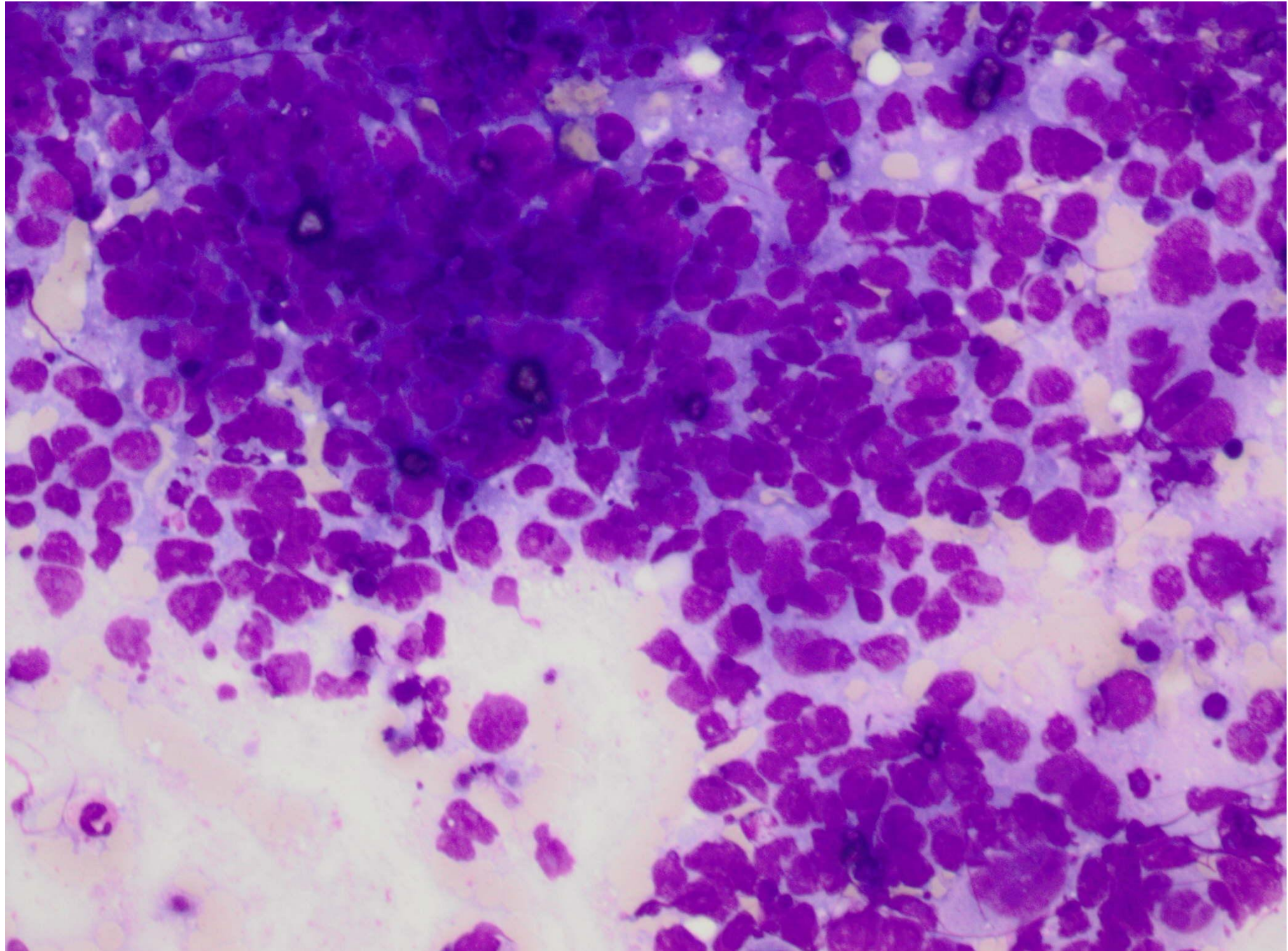


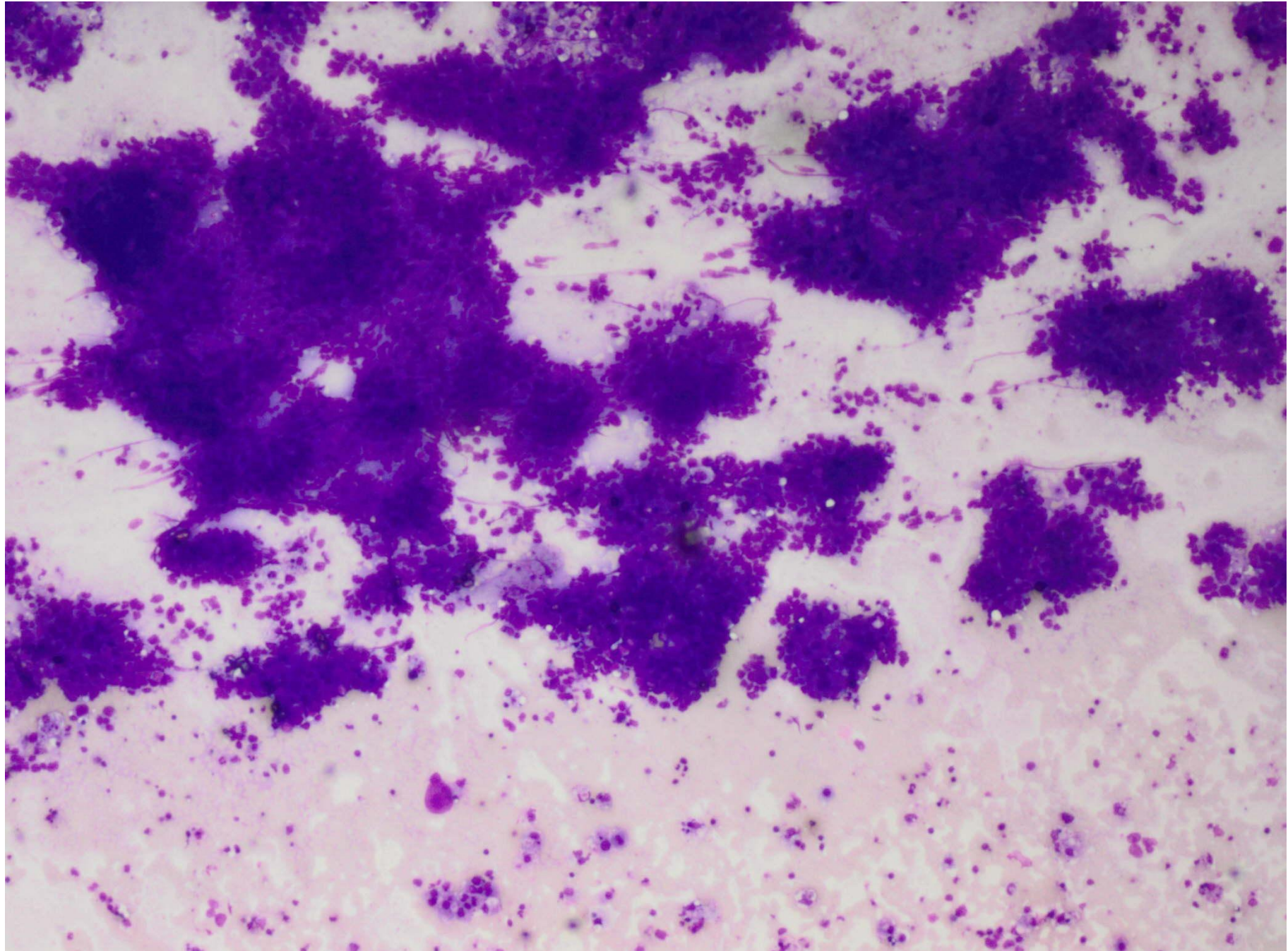


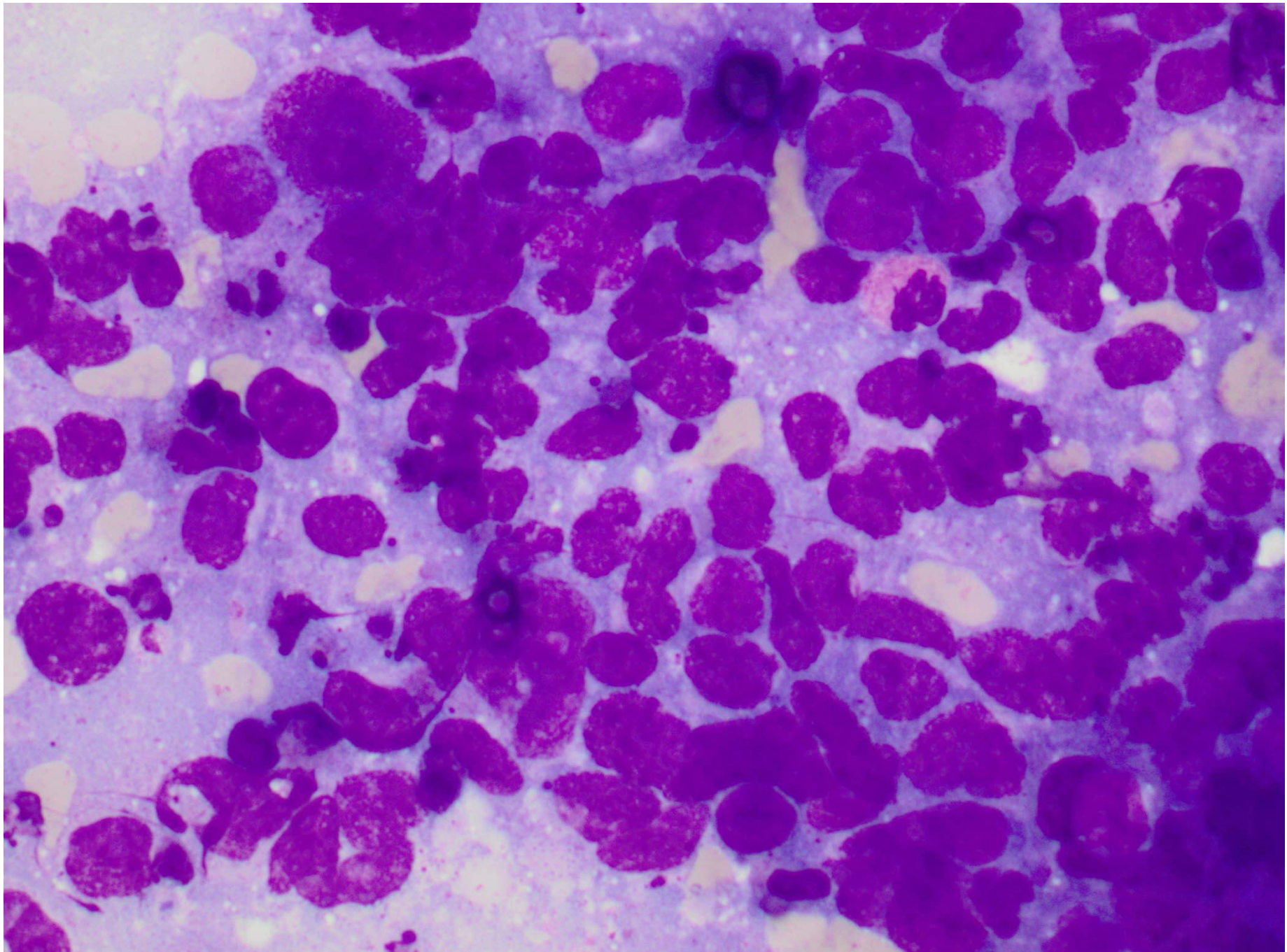


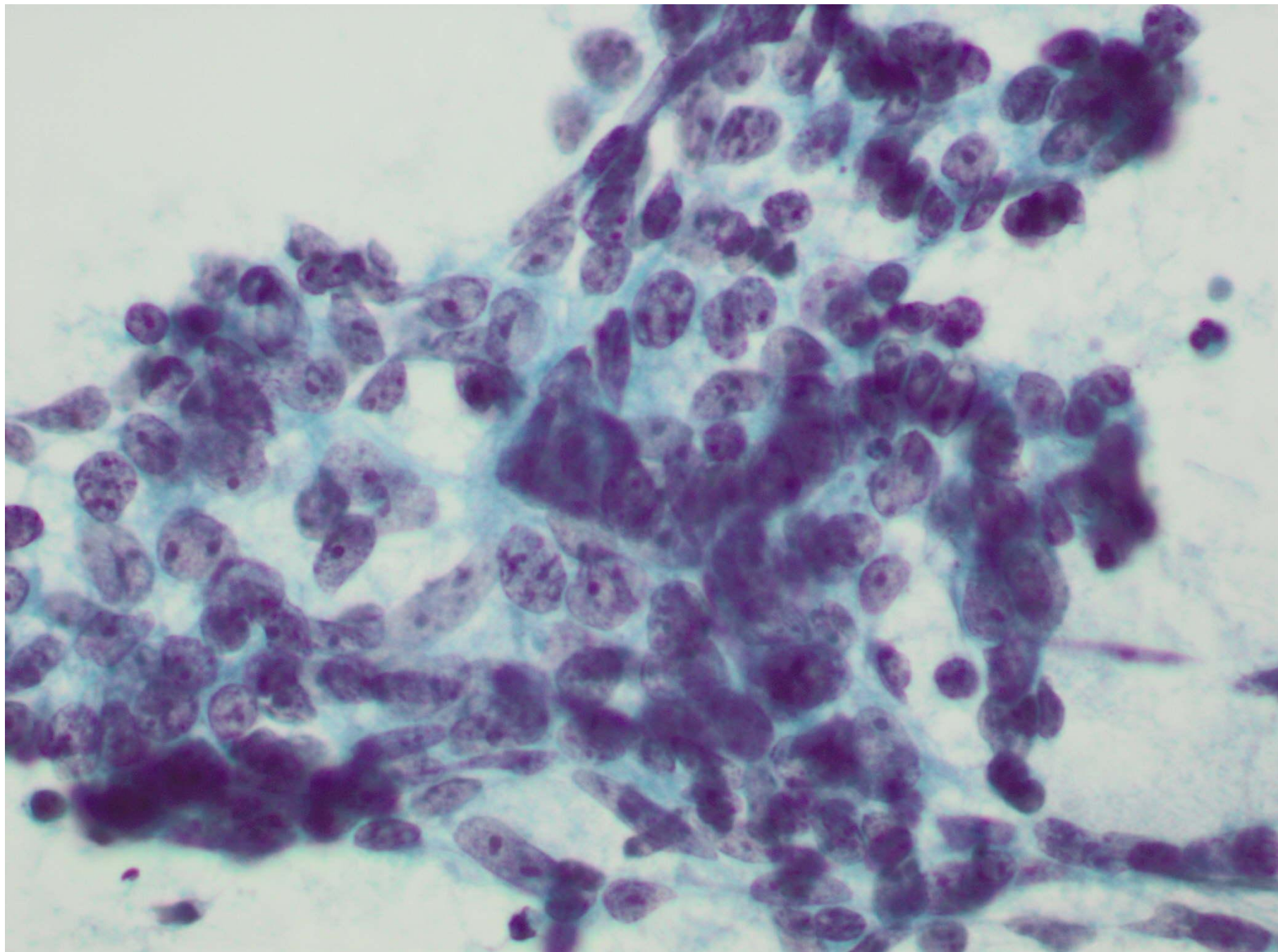
Case 21

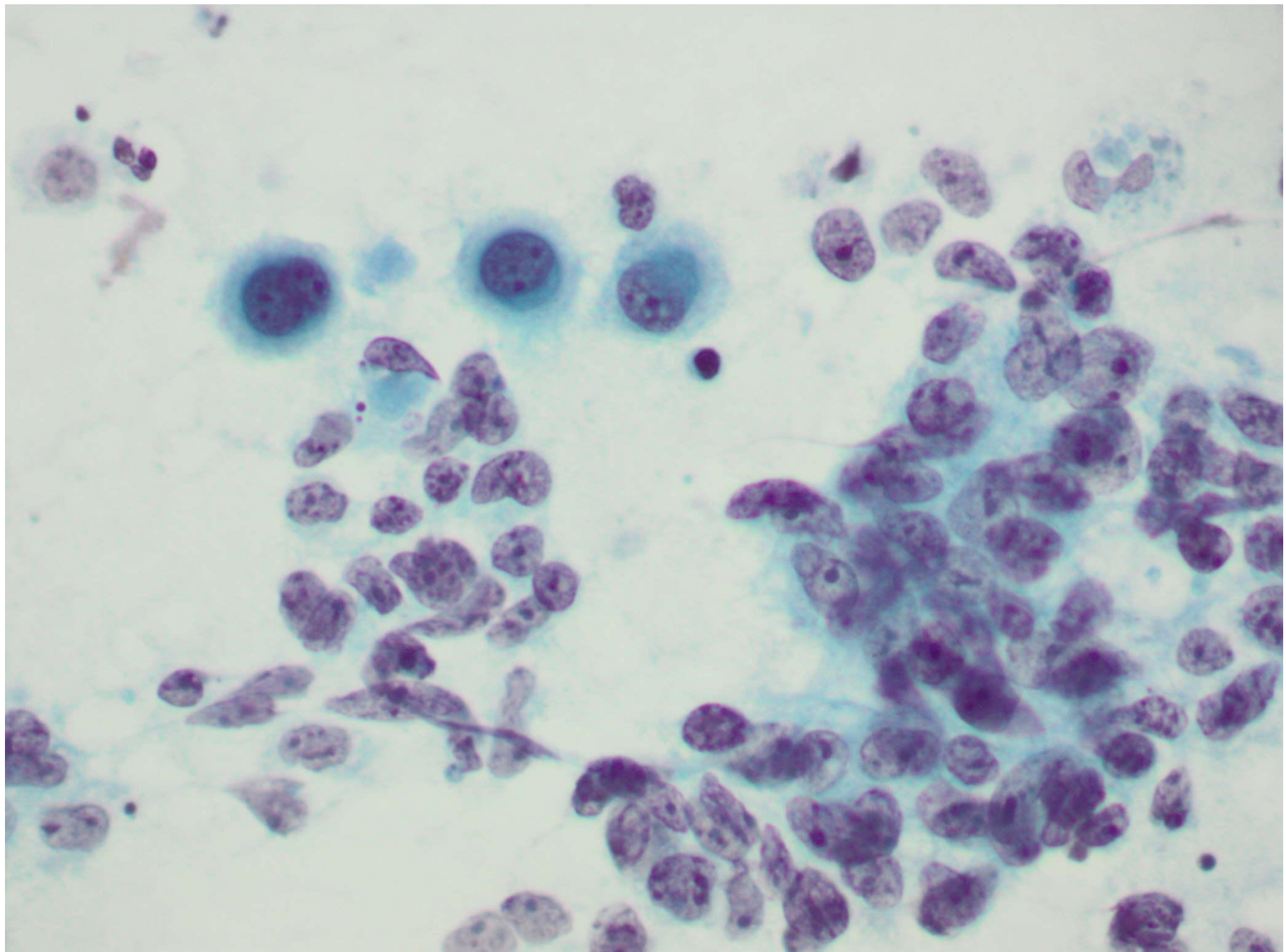
Male 70. Pleural fluid.





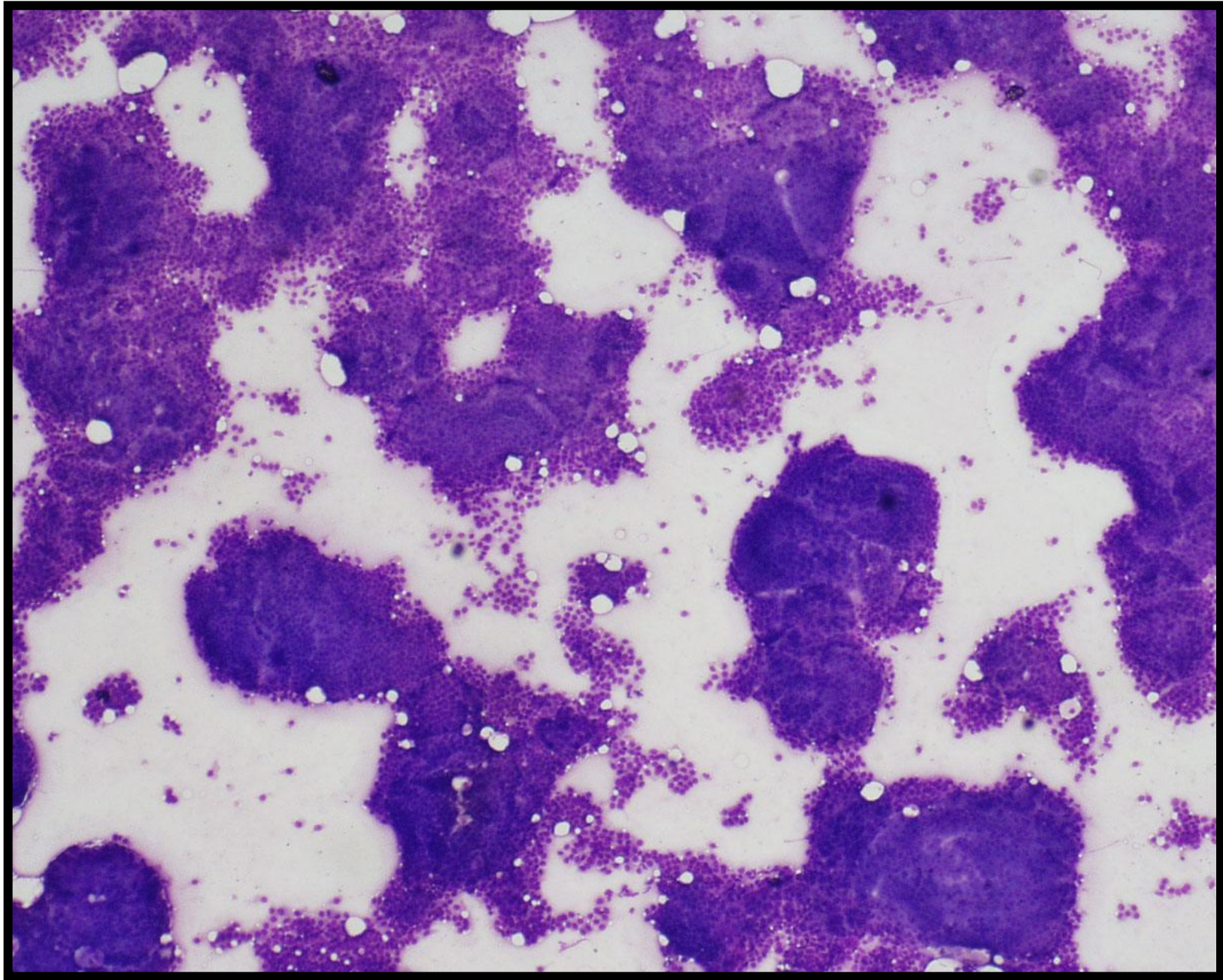


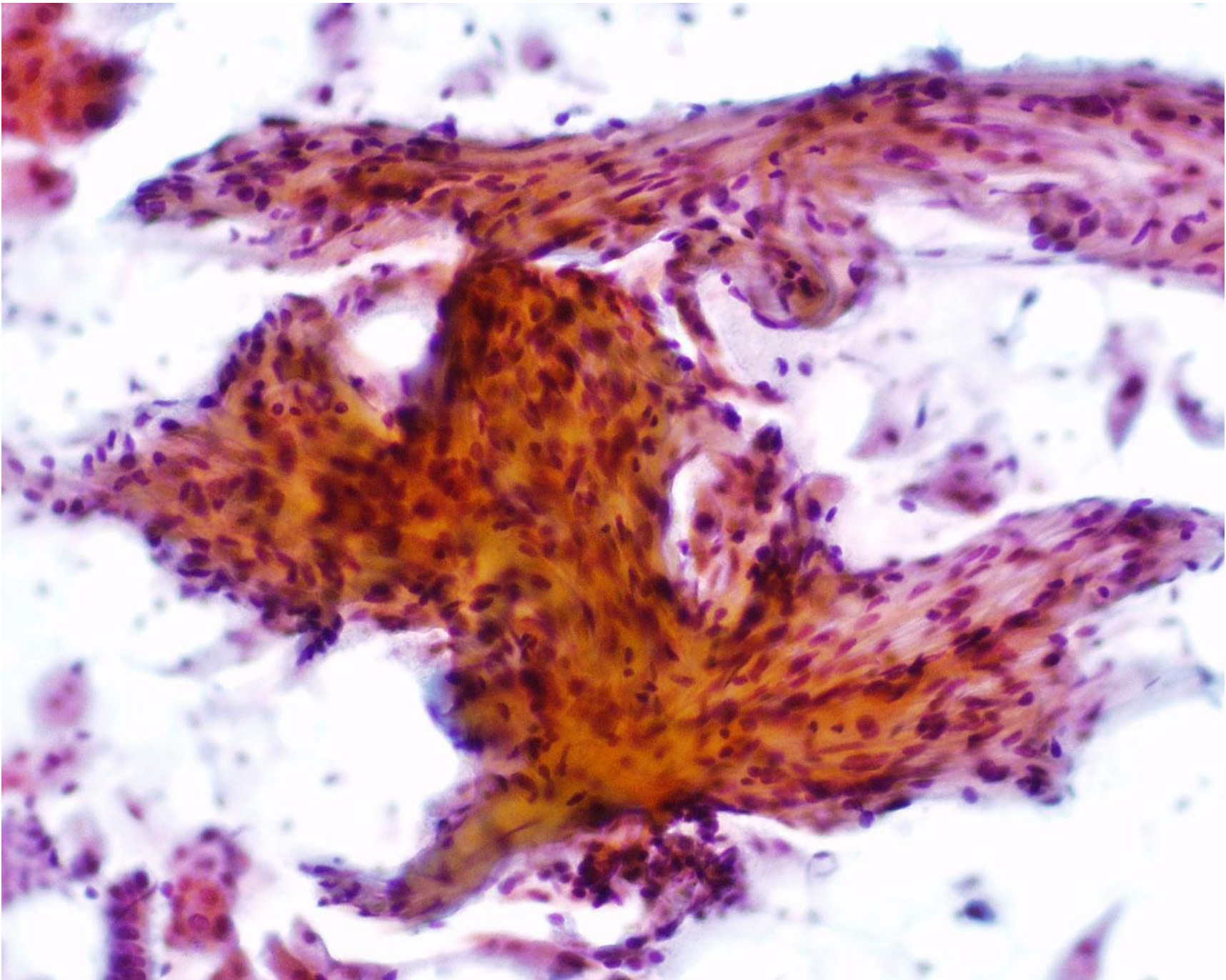


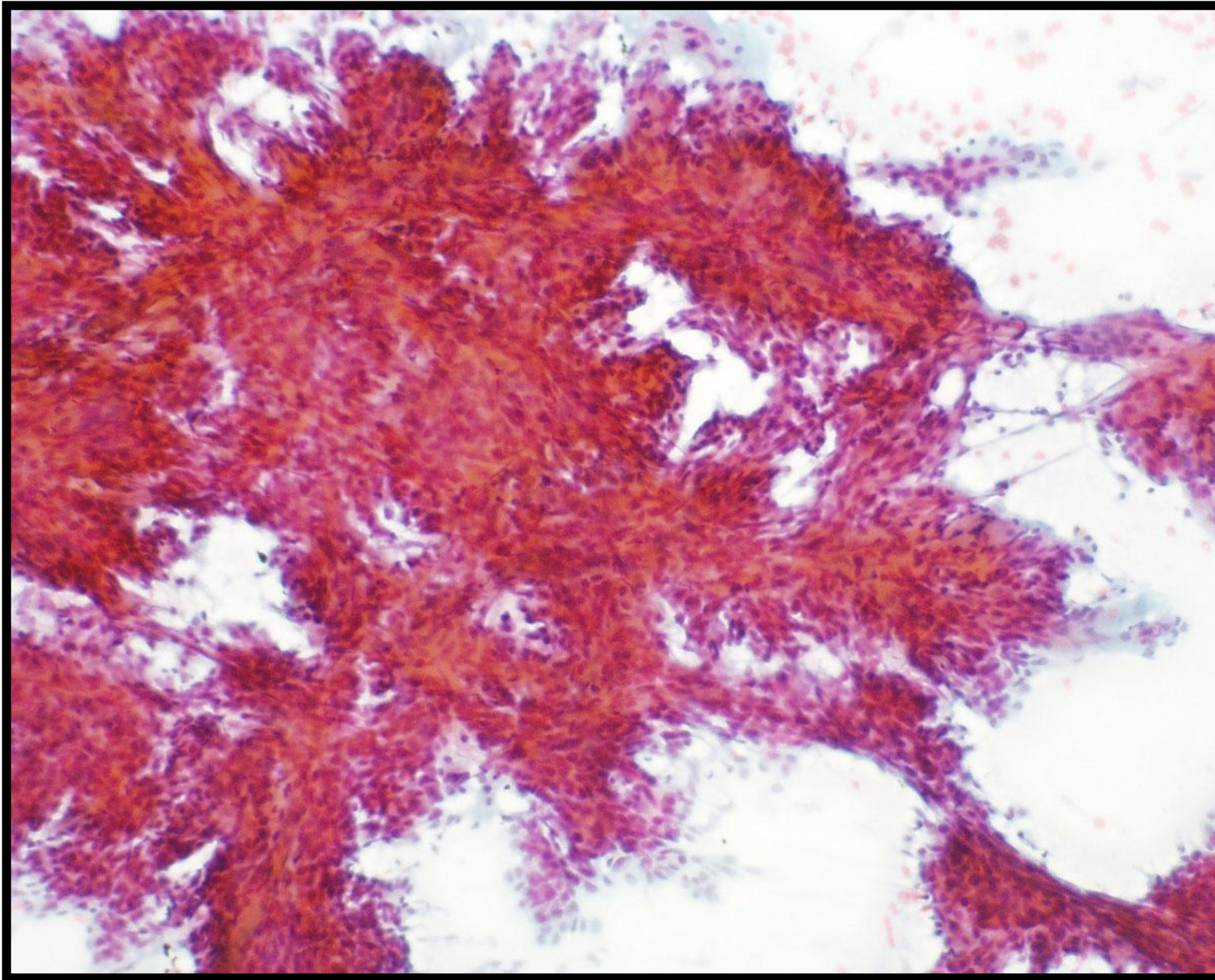


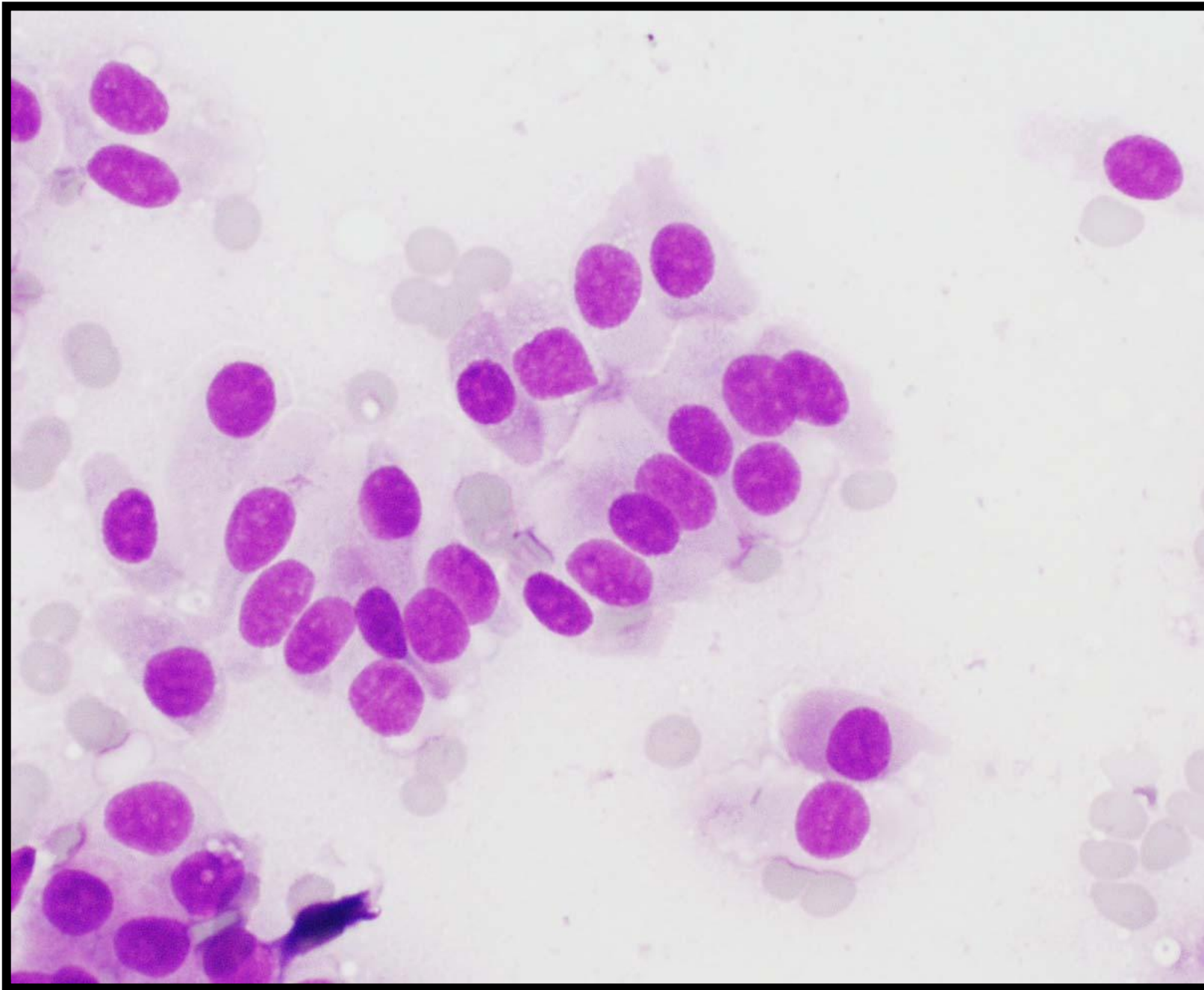
Case 22

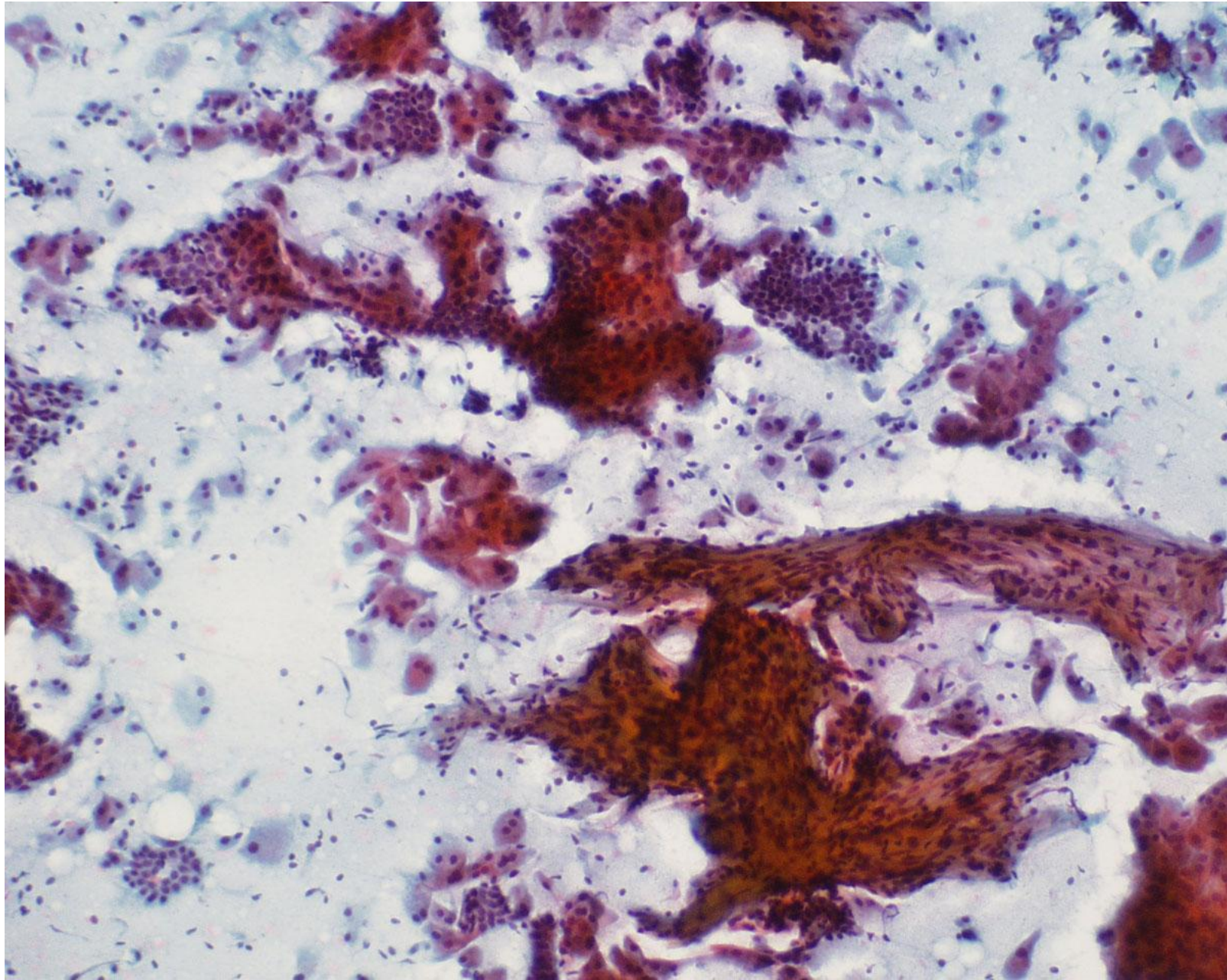
F65. Lesion detected at breast screening. FNA Right breast, 1 cm from nipple.

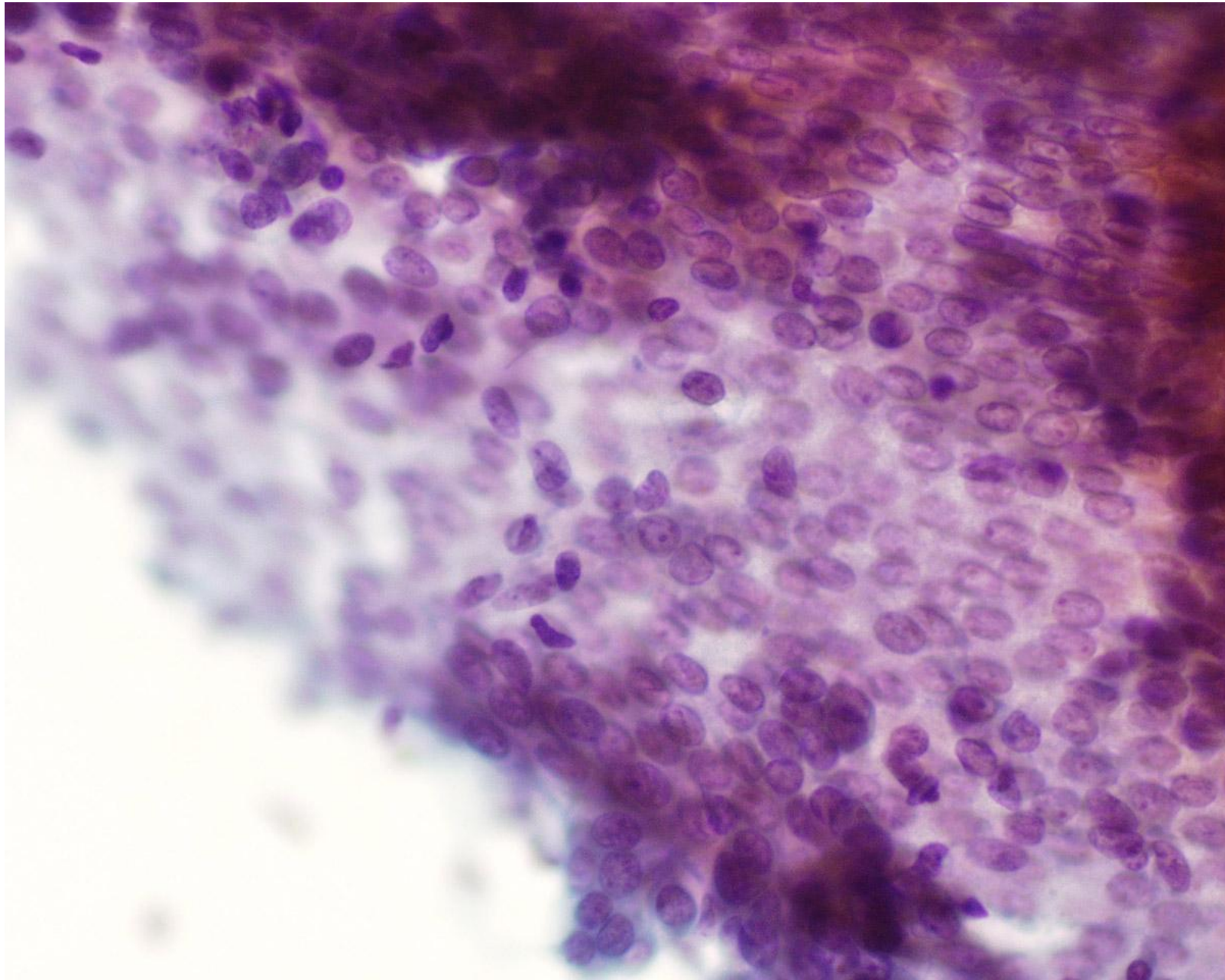


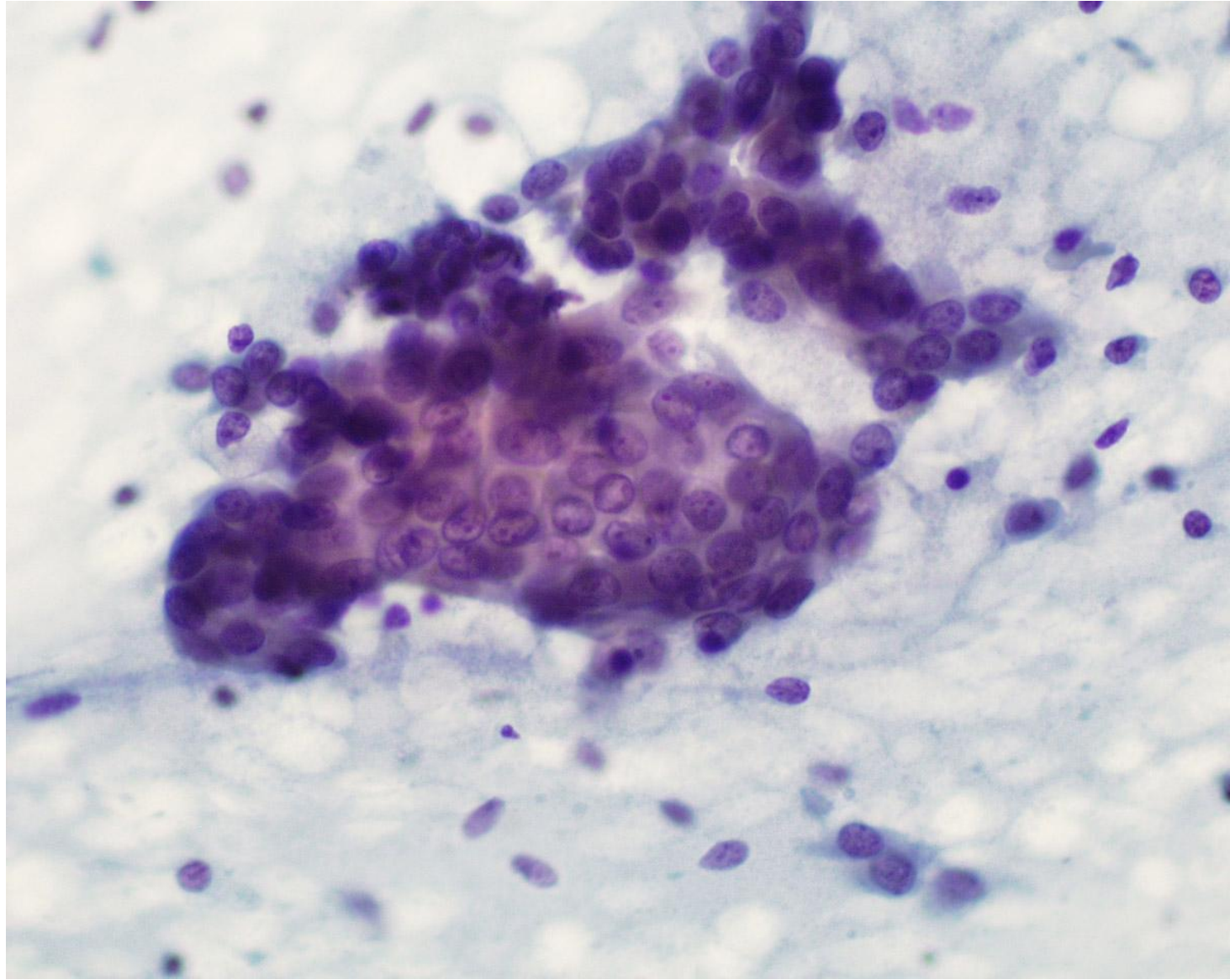






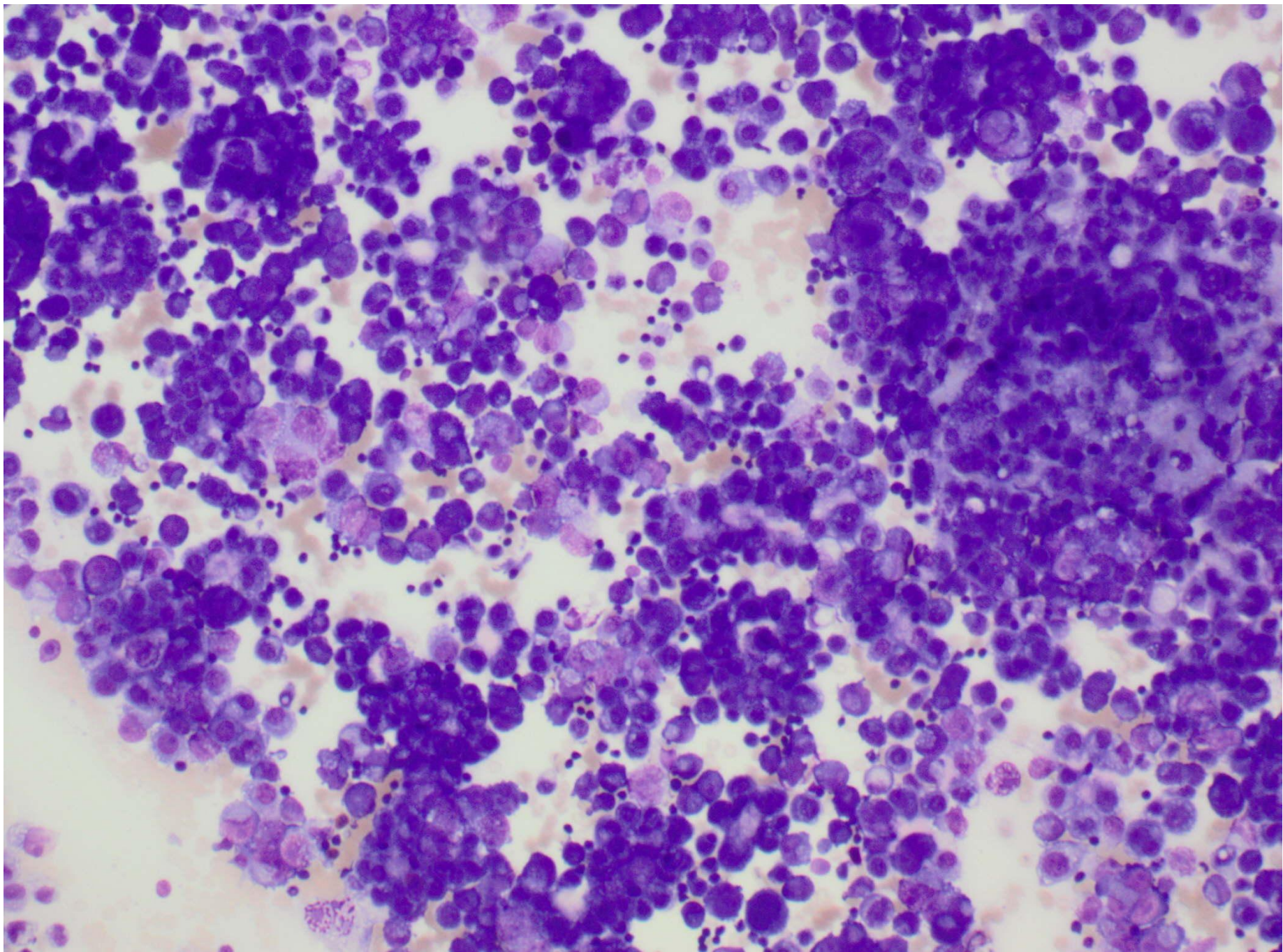


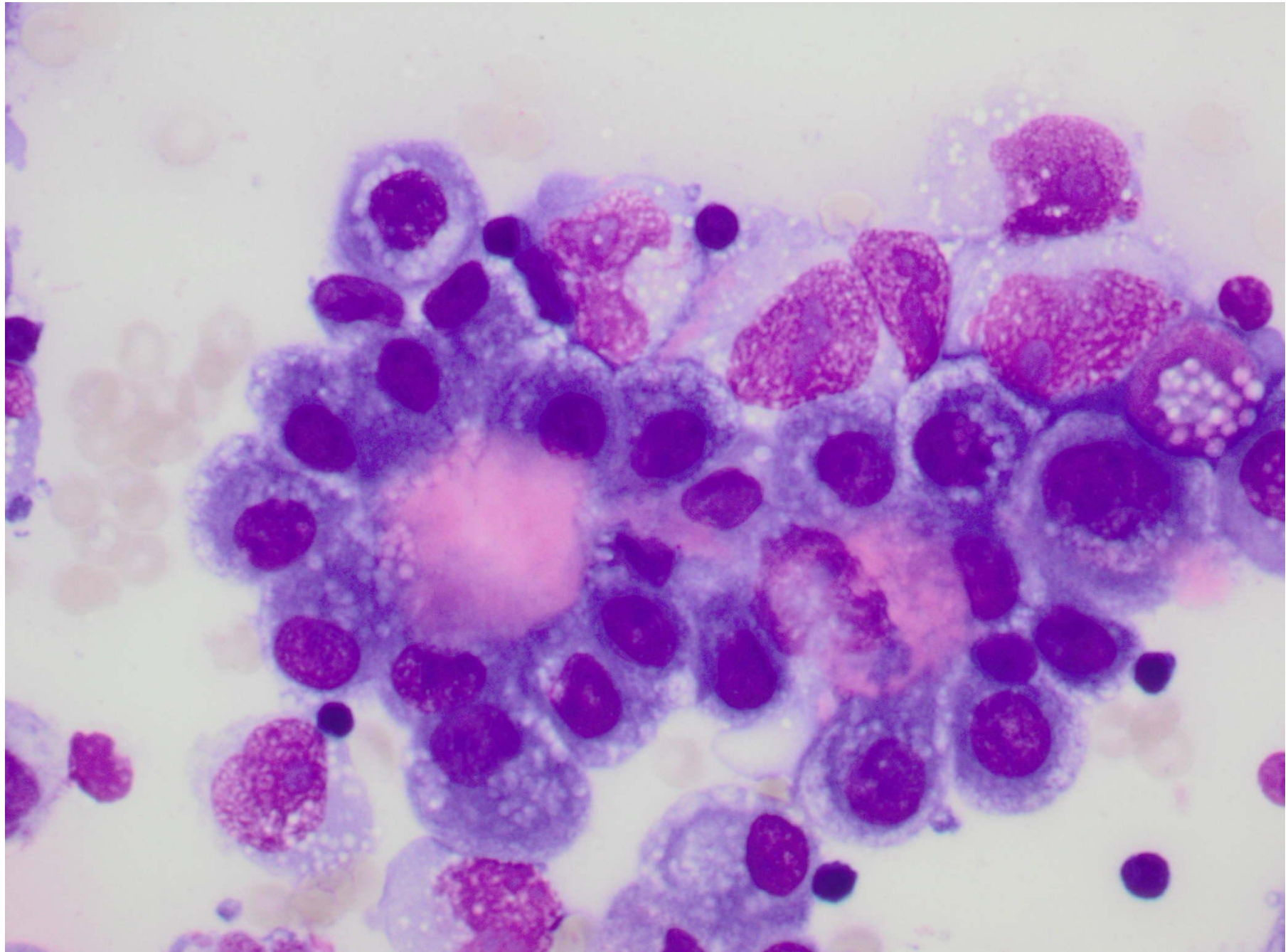


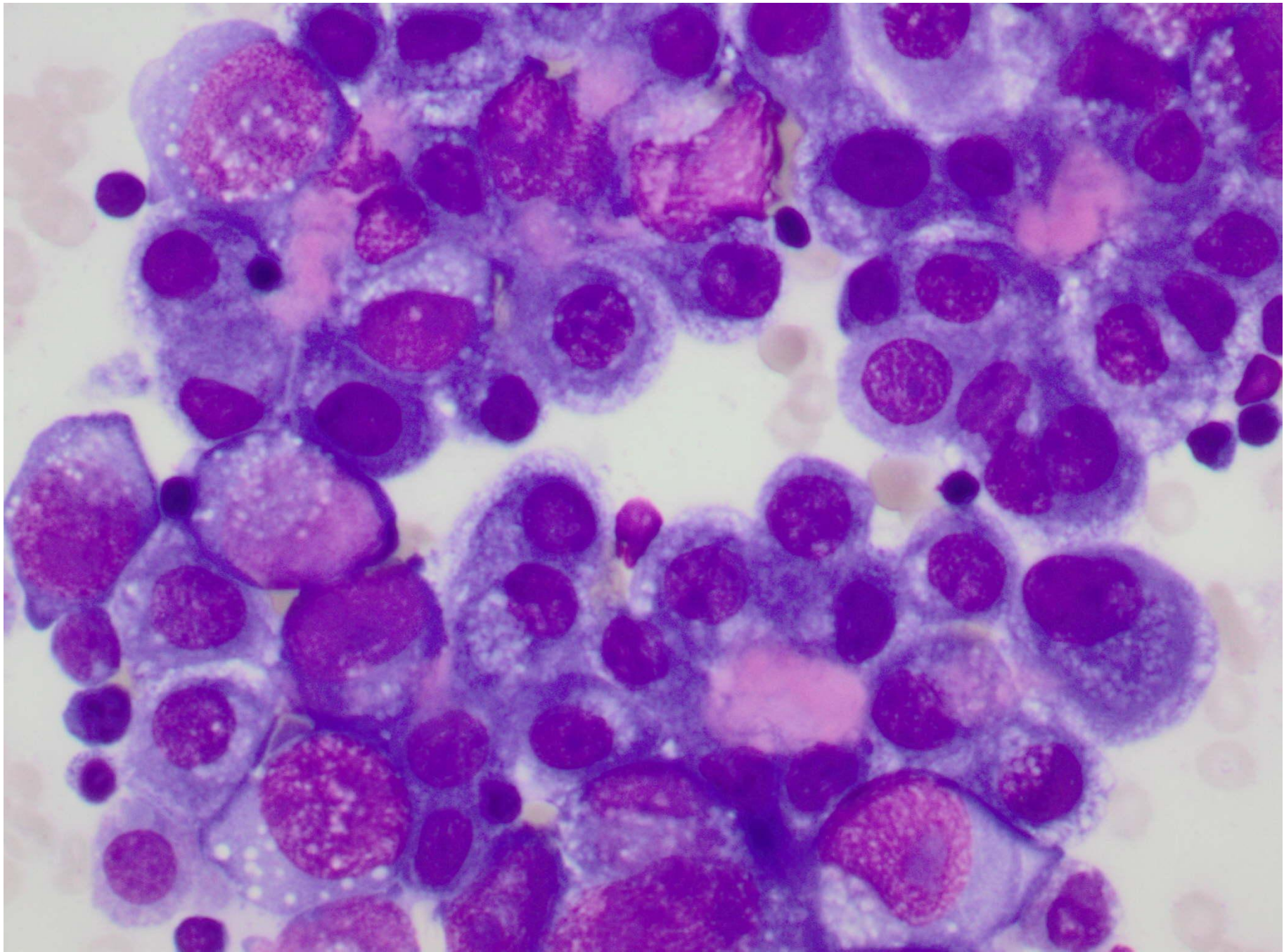


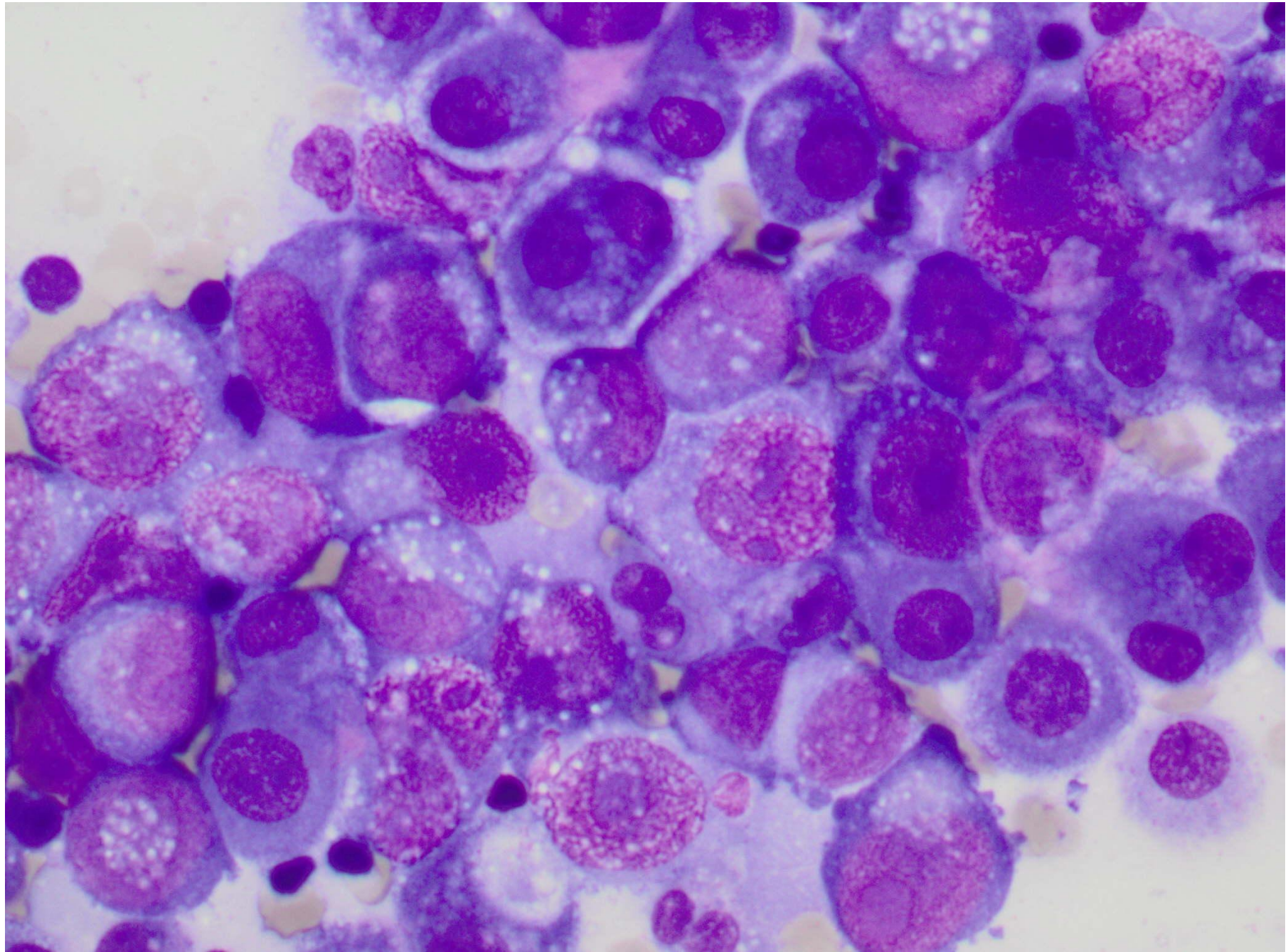
Case 23

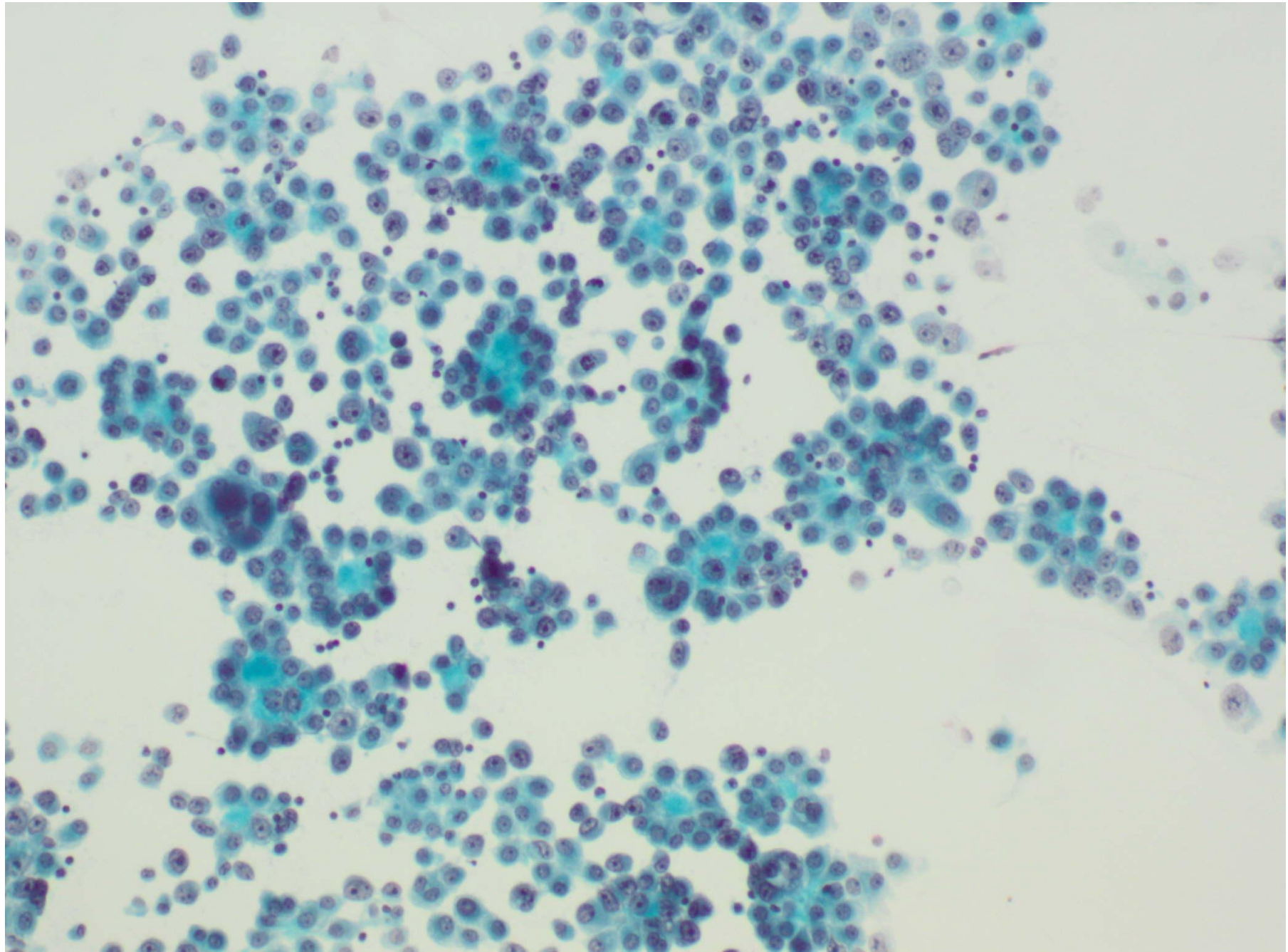
Male 65. Left pleural effusion.

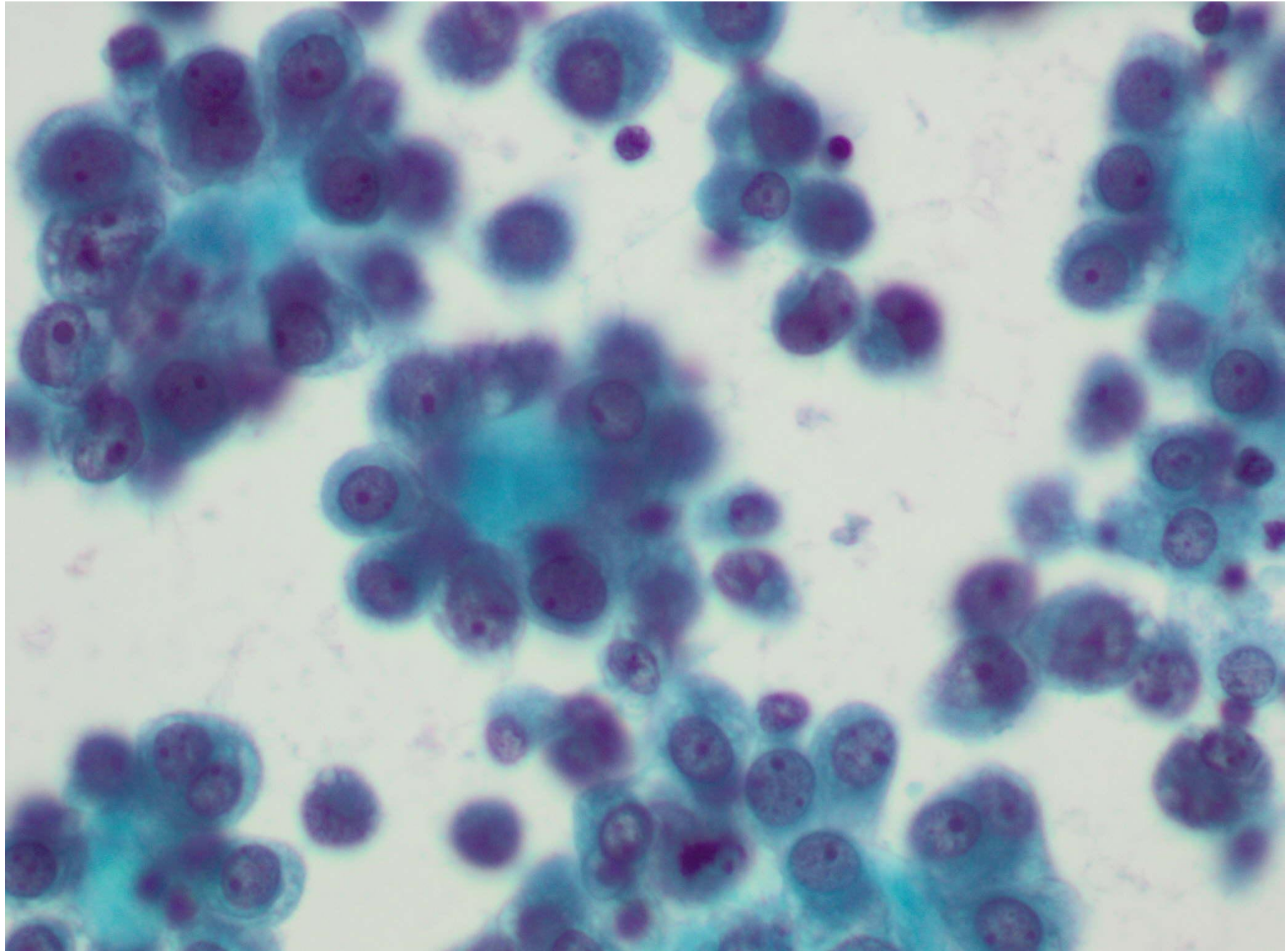


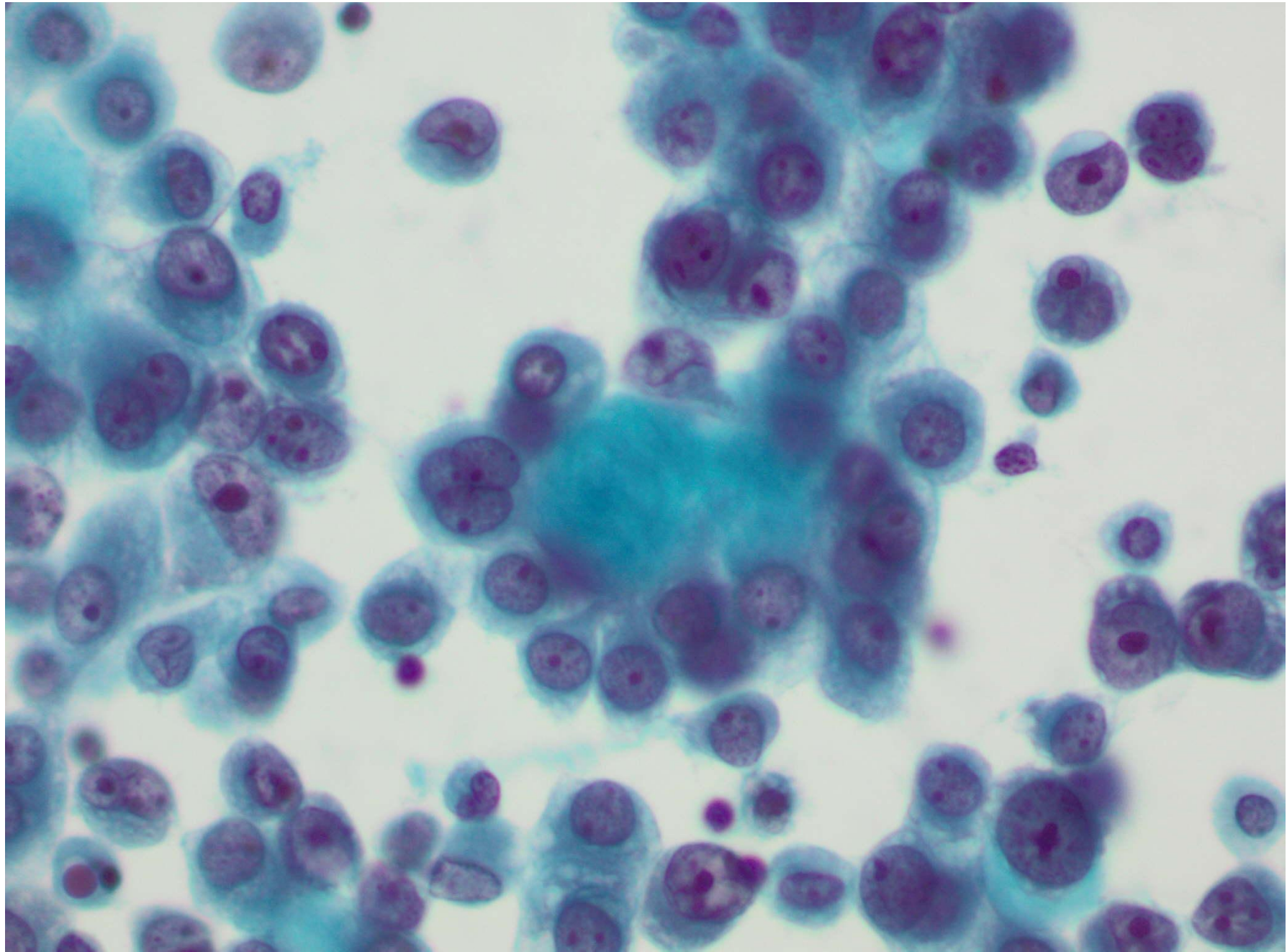






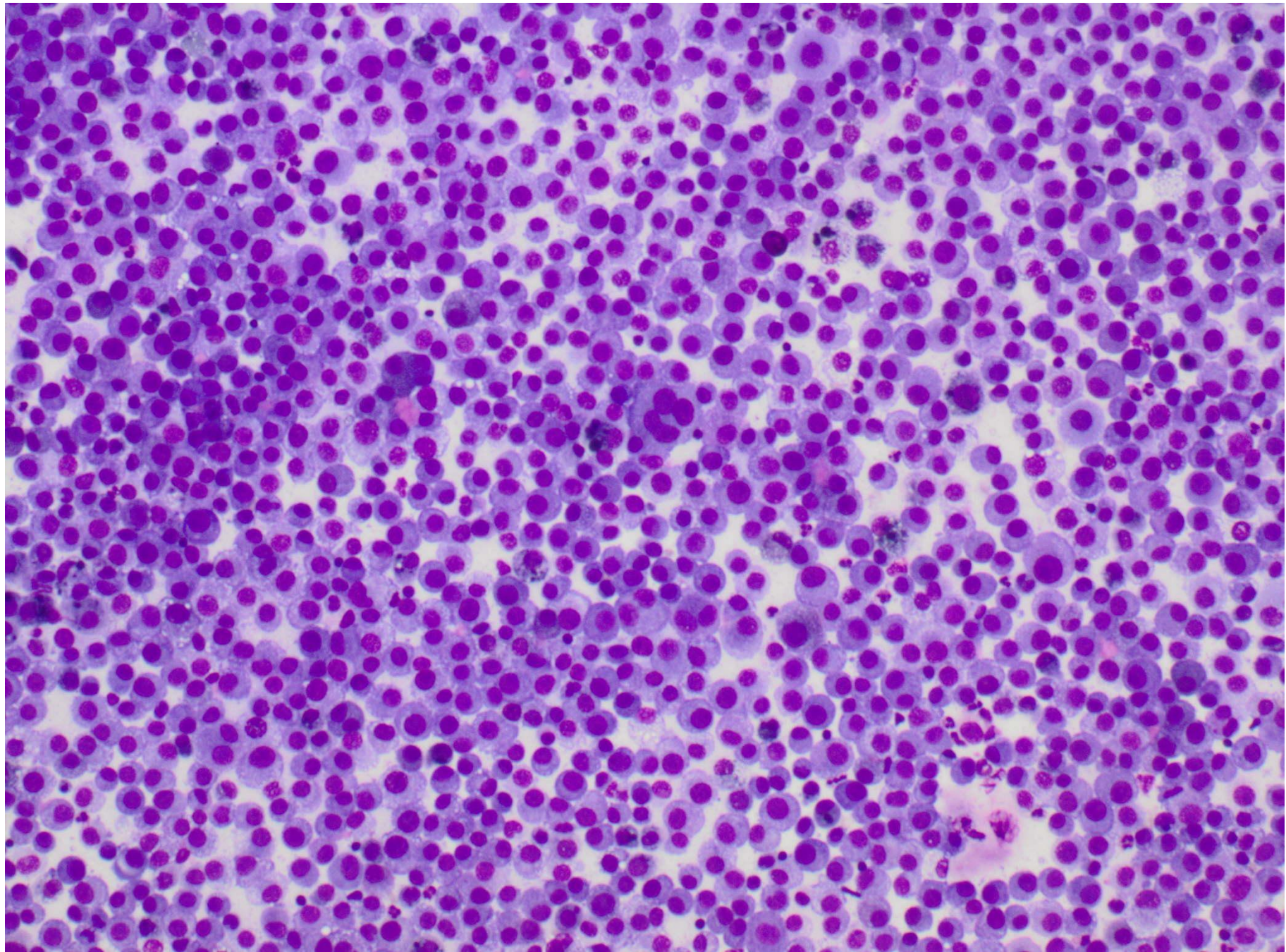


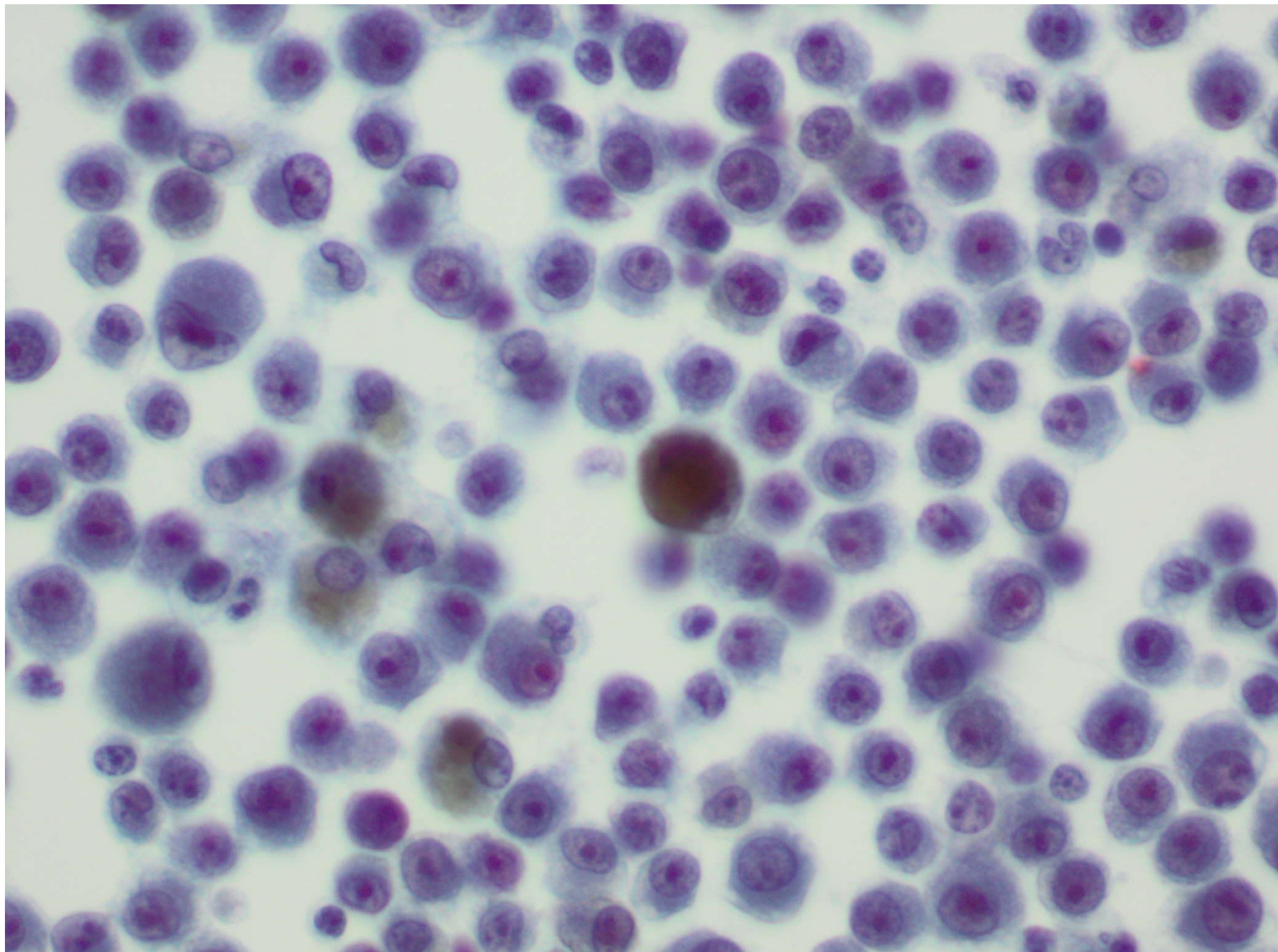


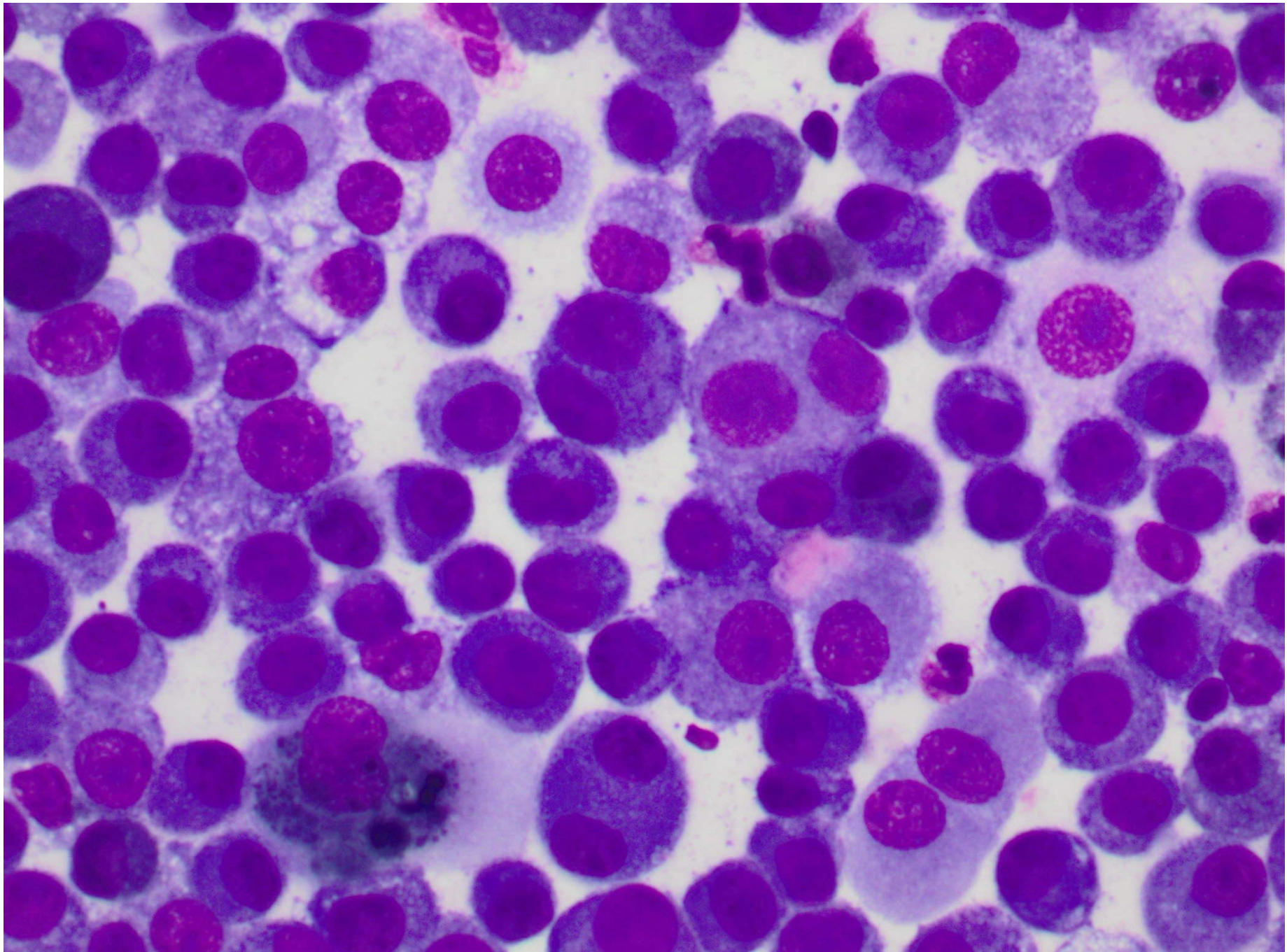


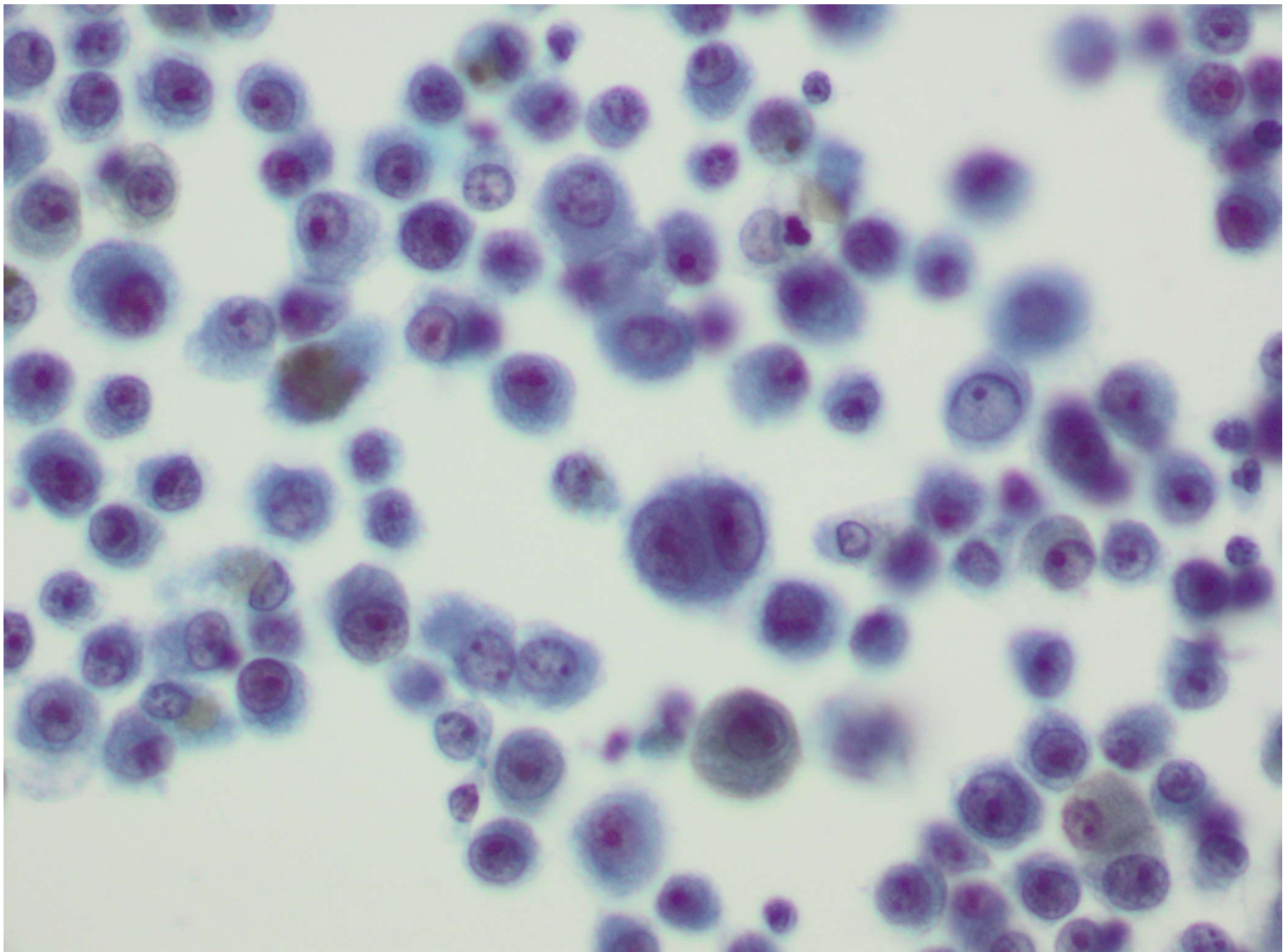
Case 24

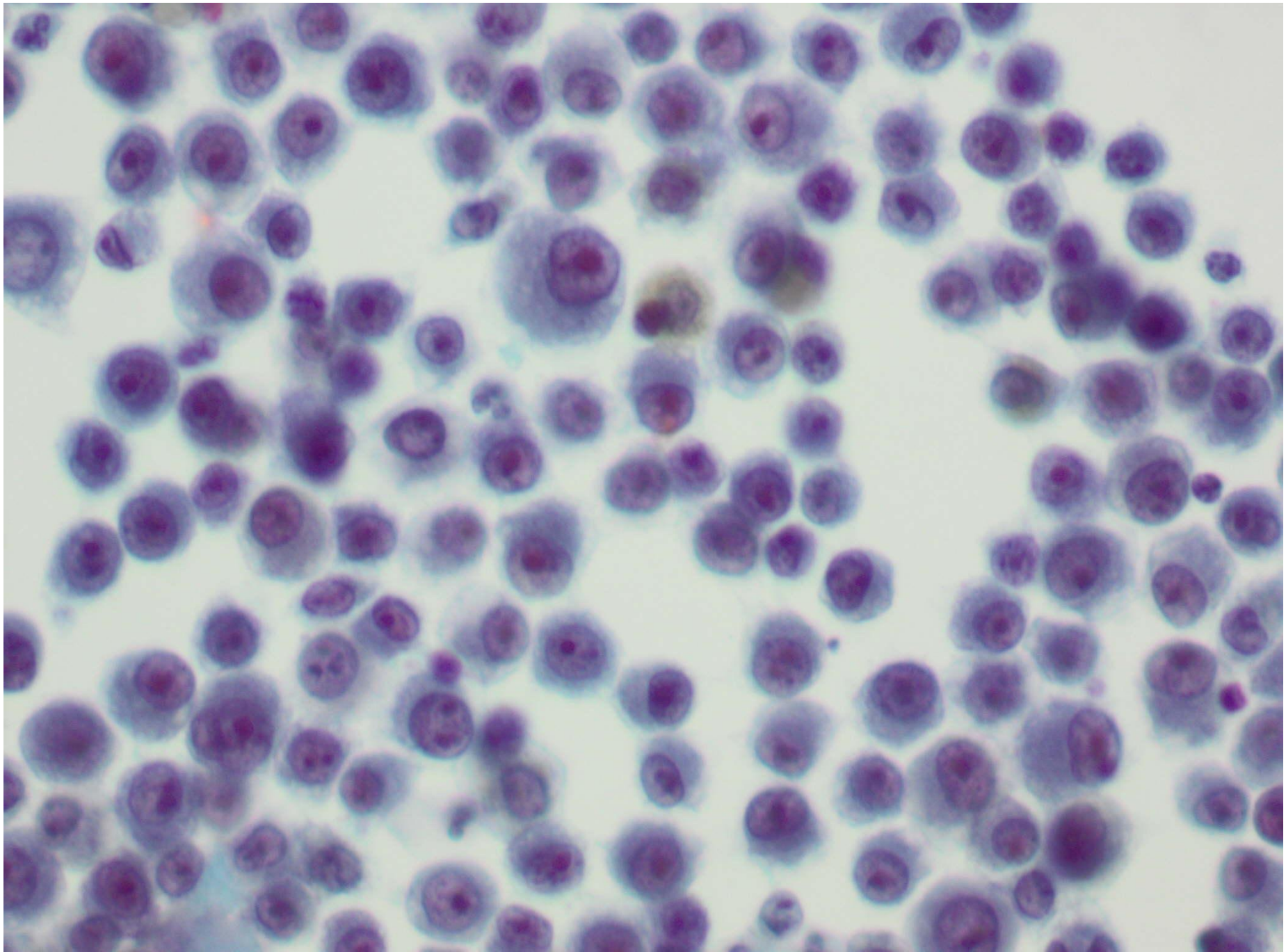
Male 60. Pleural effusion





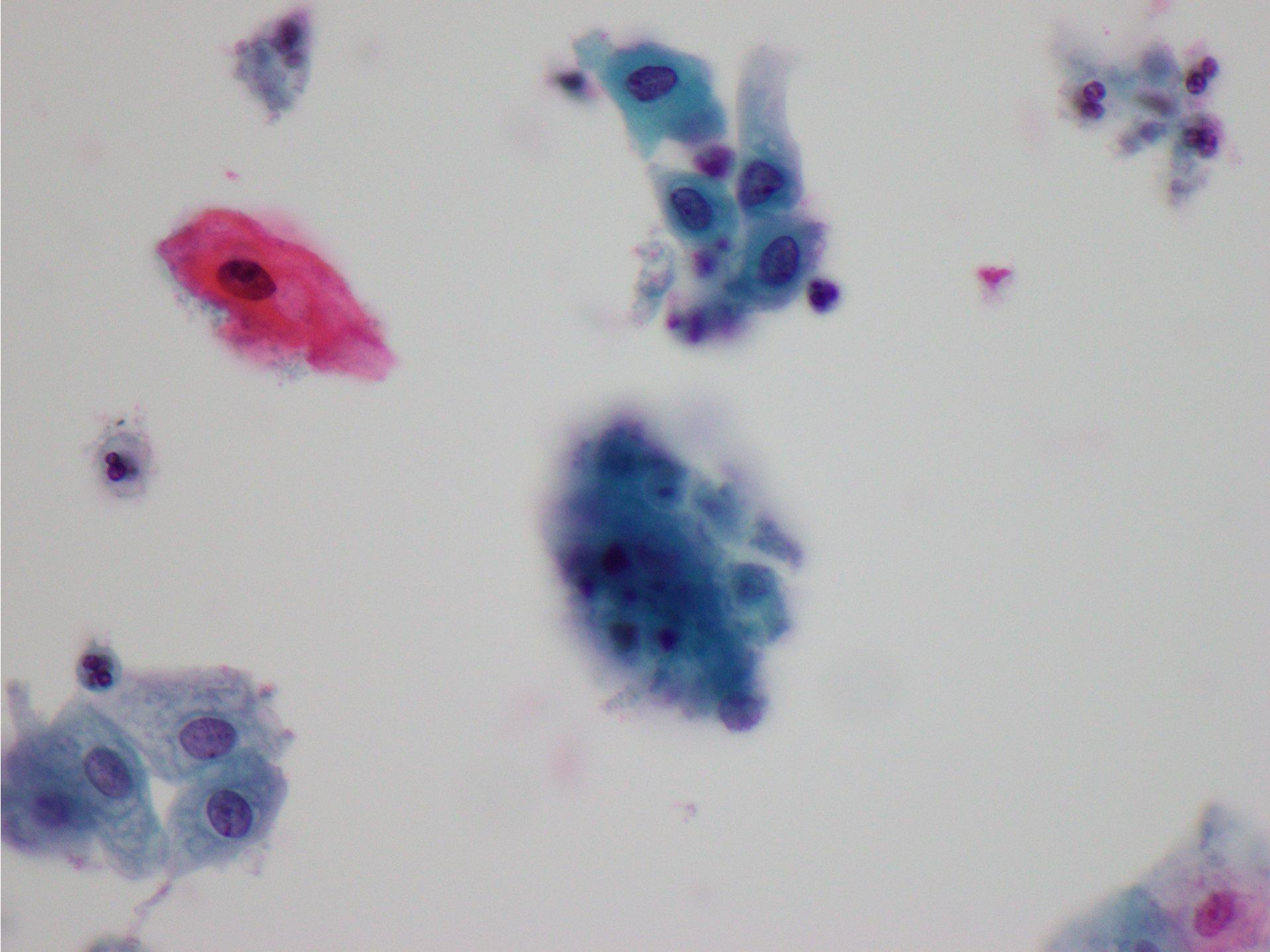


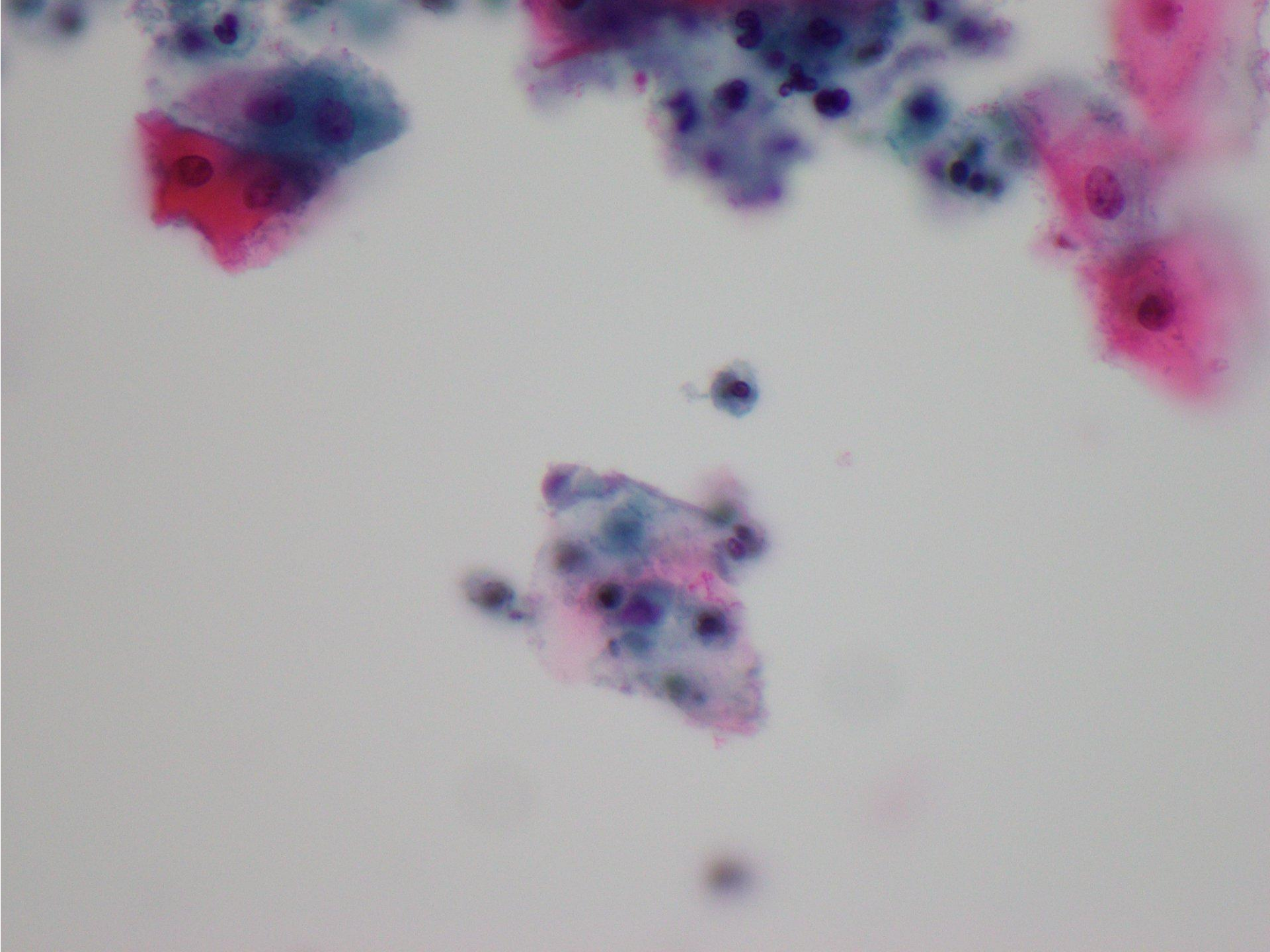


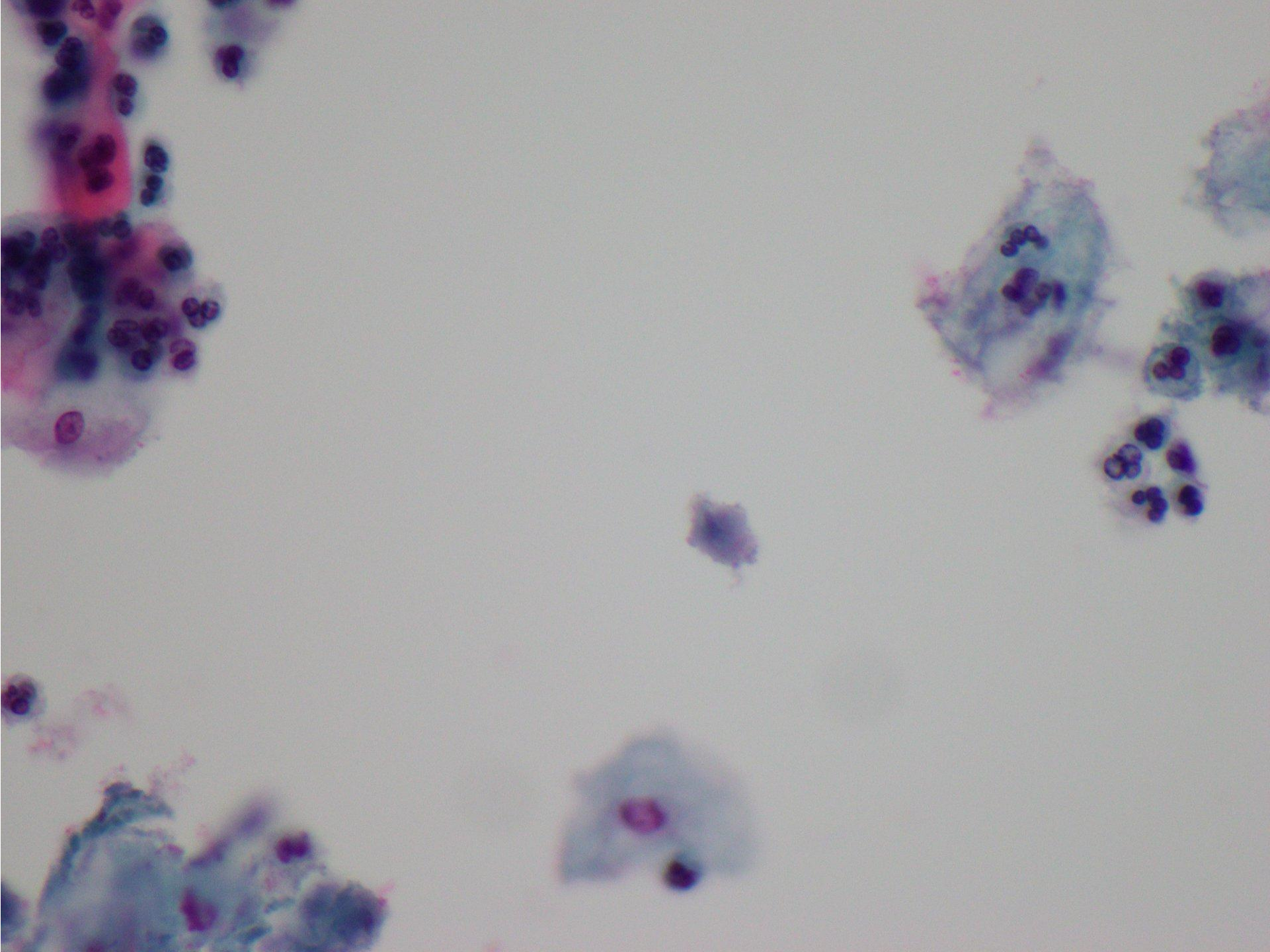


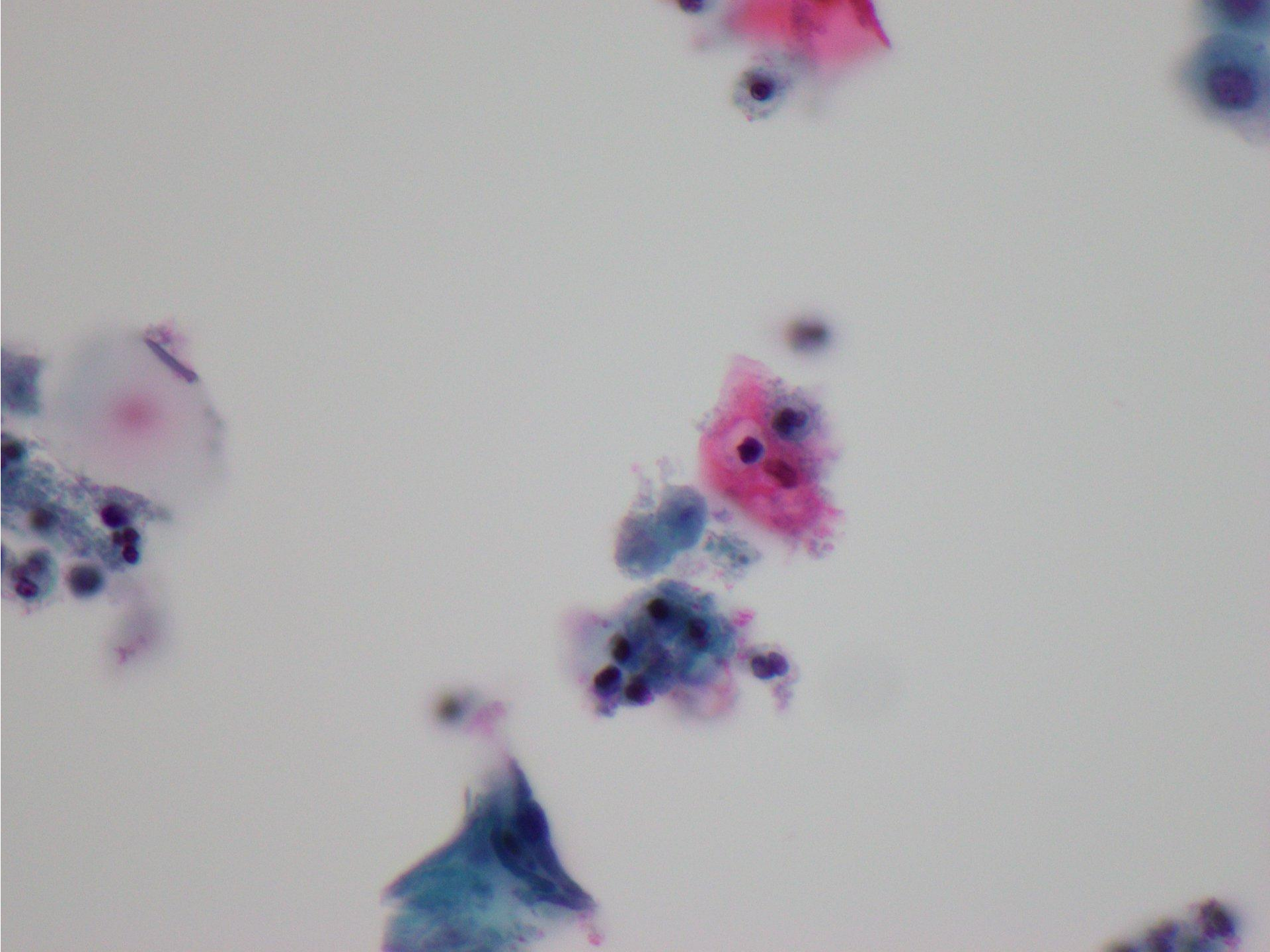
Case 25

F25, Vaginal discharge. Routine cervical screening.



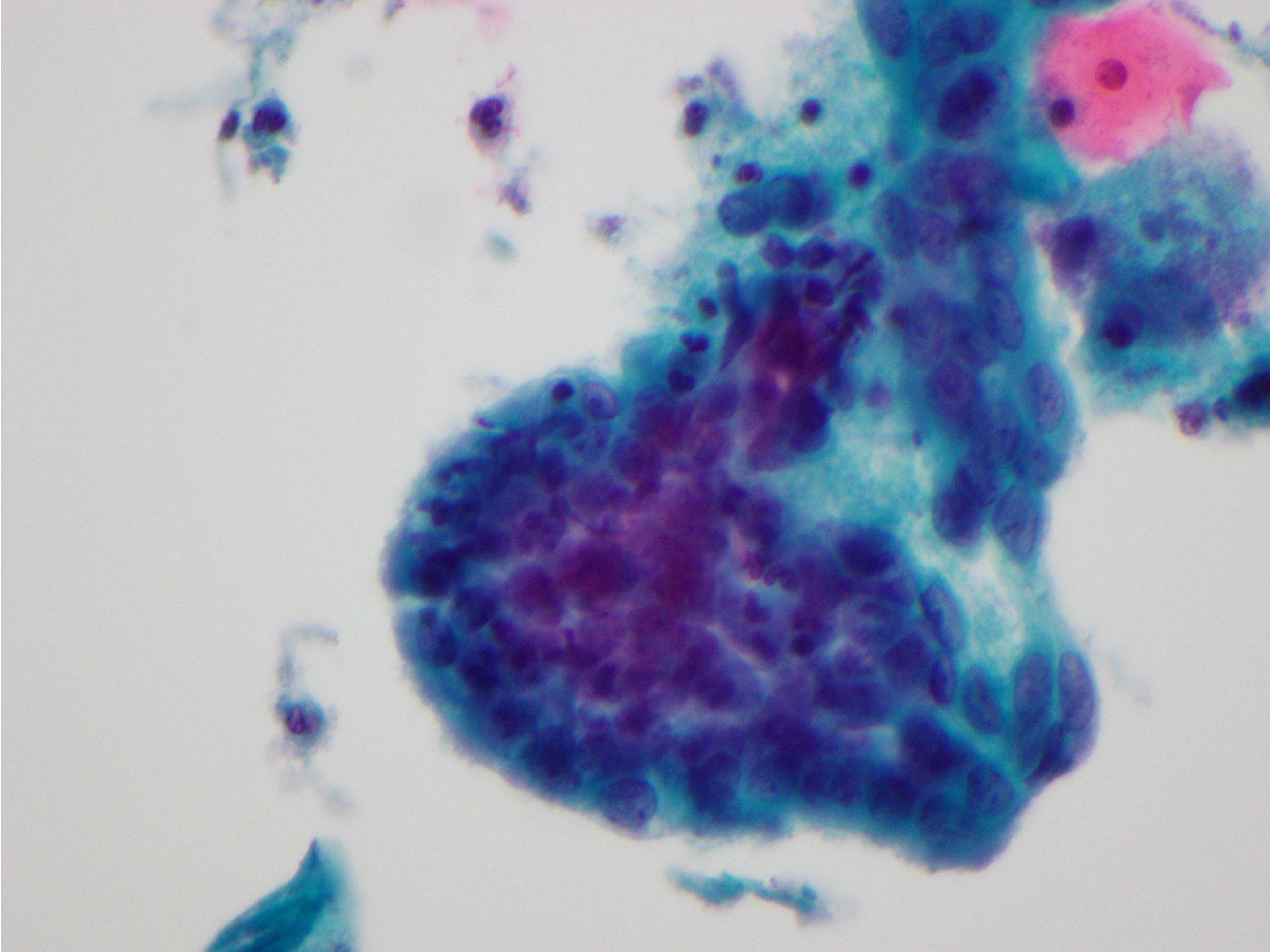


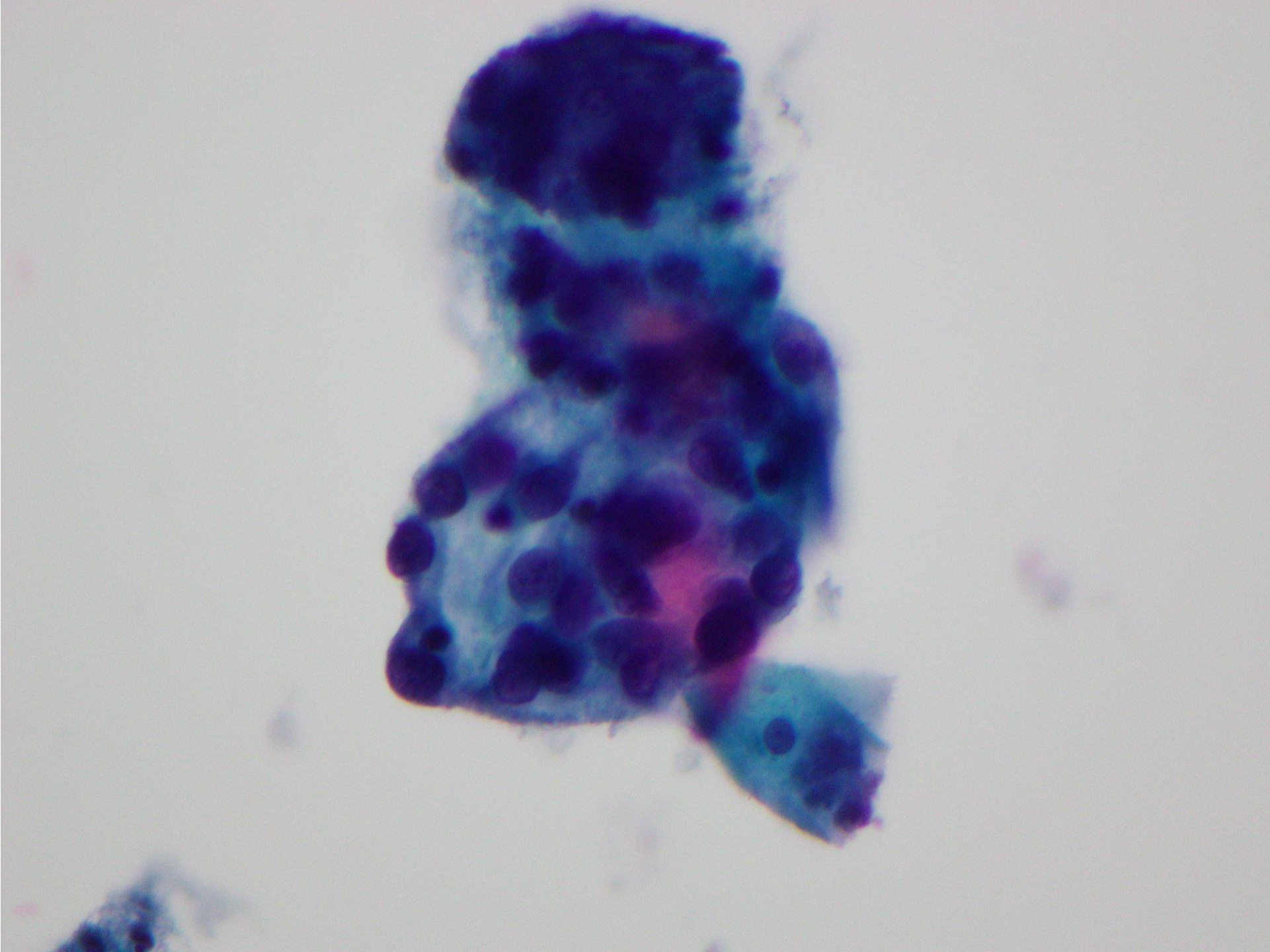


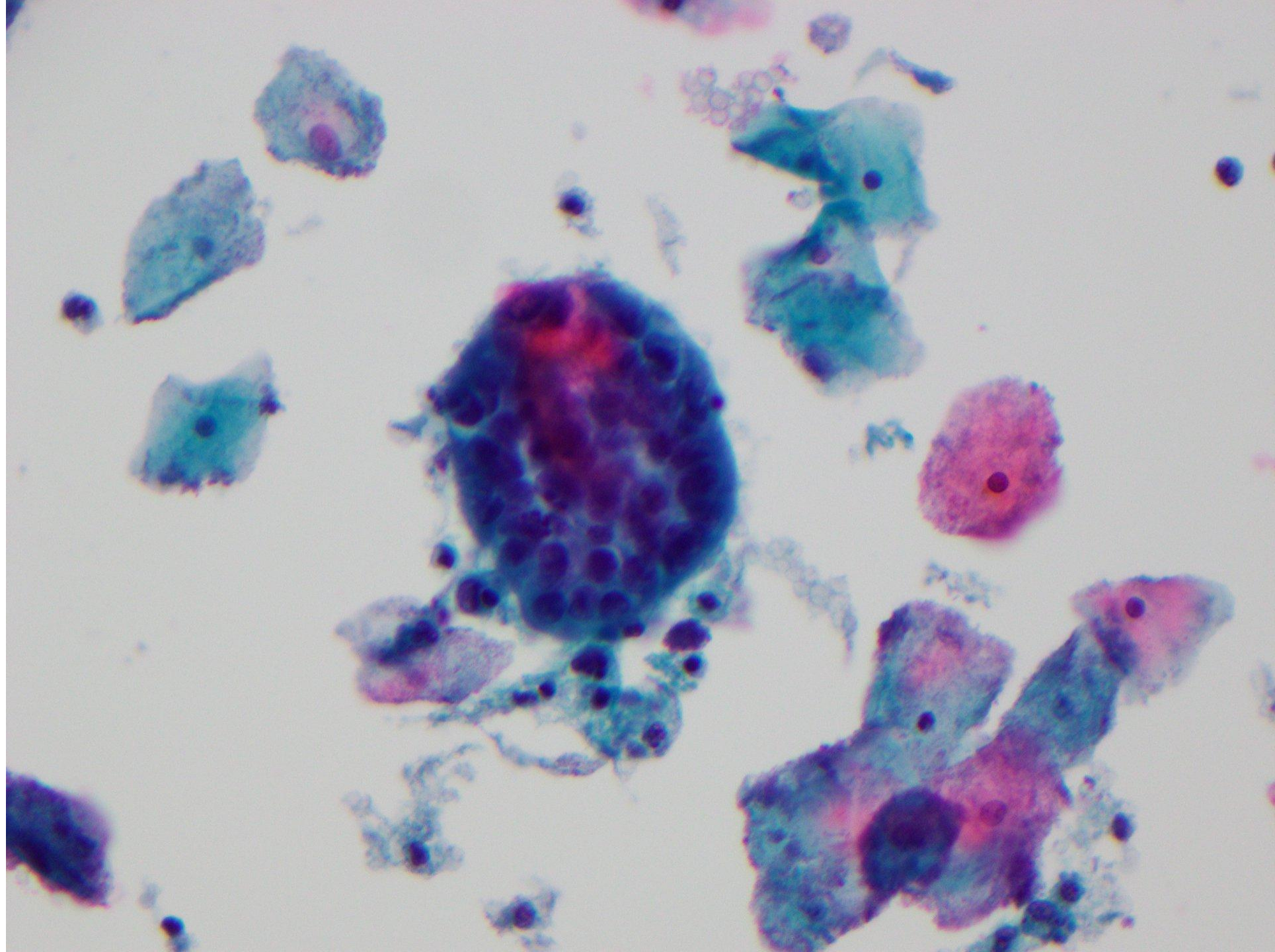


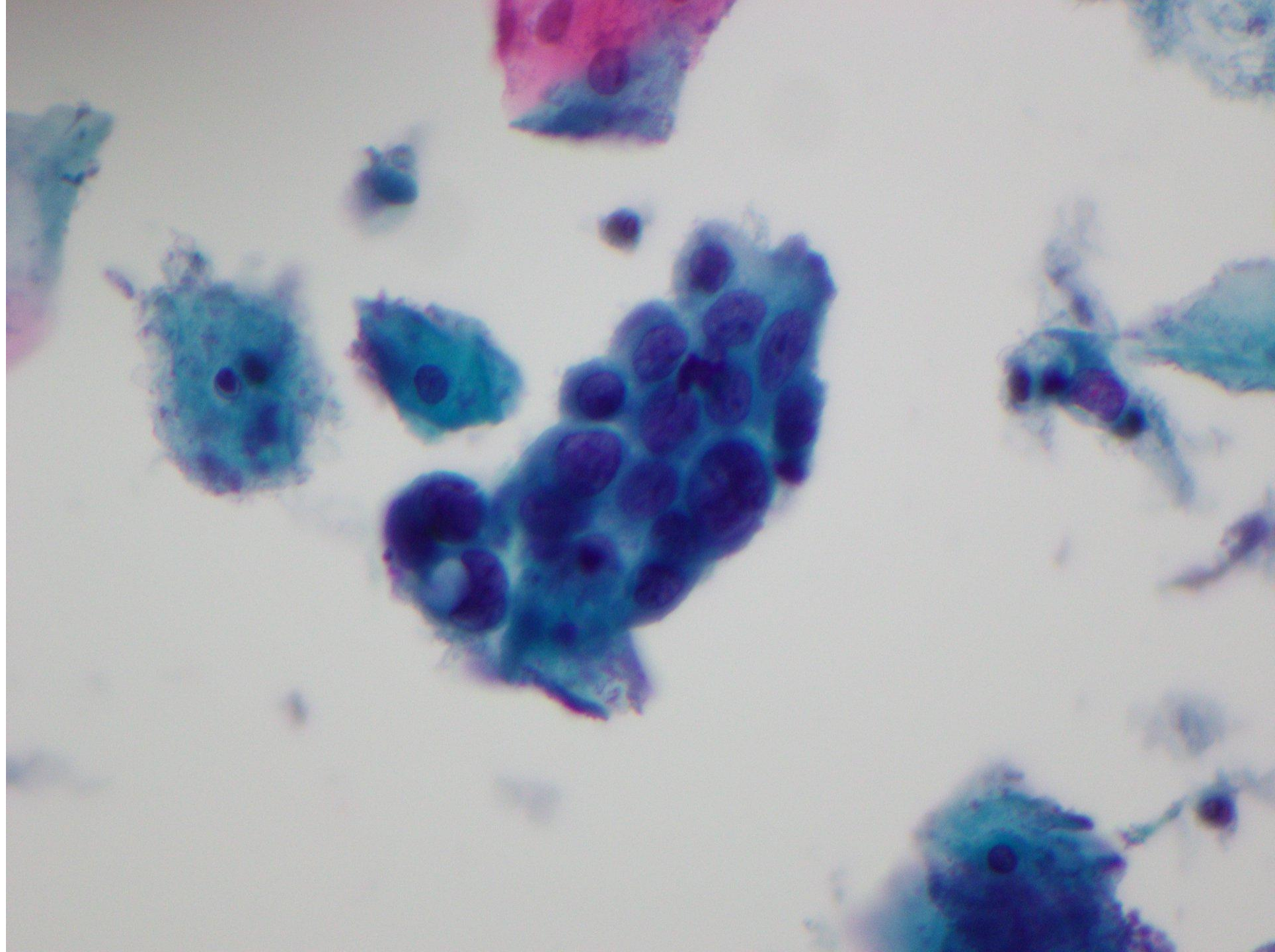
Case 26

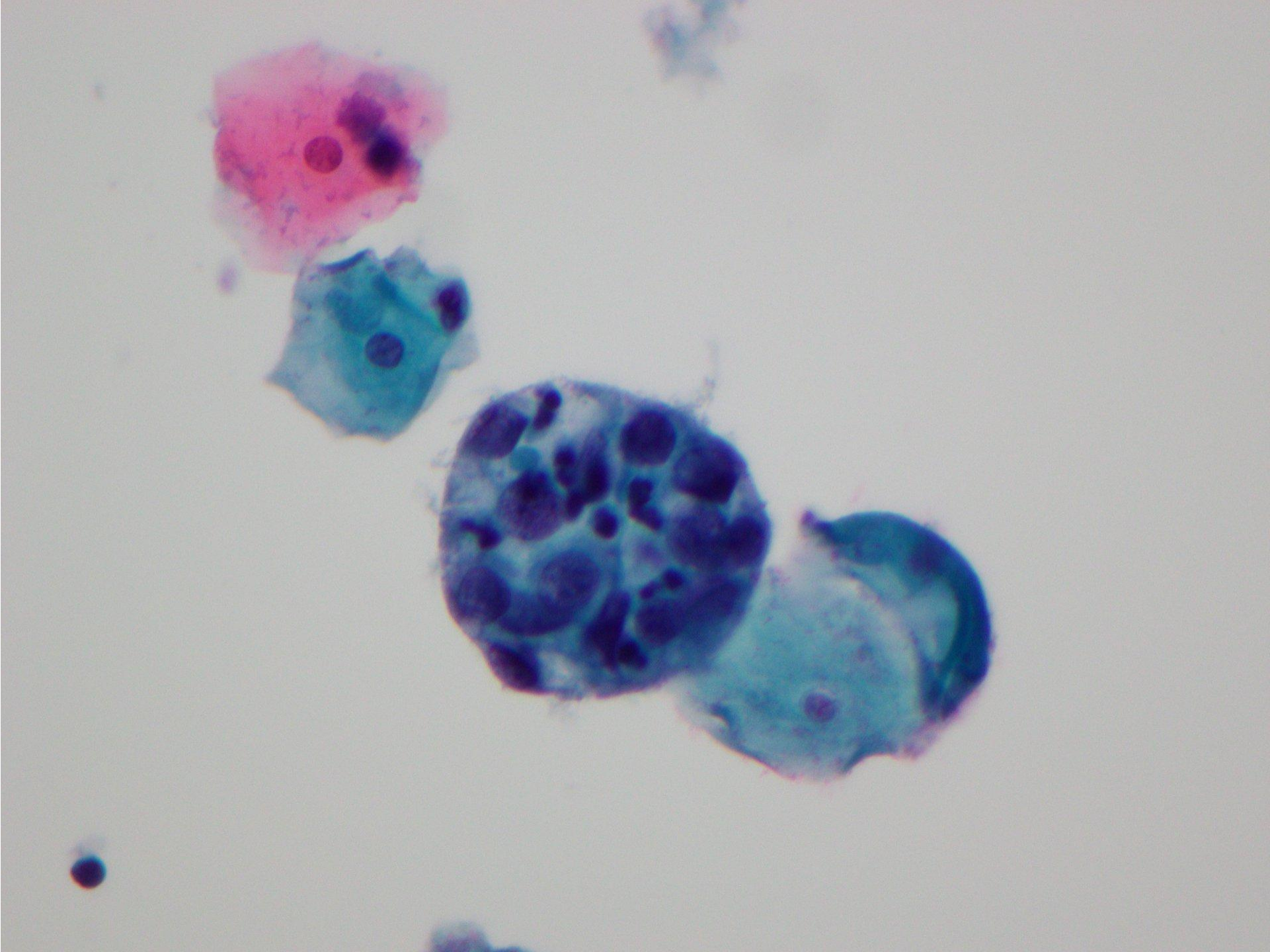
F54 – vaginal vault smear. Previous TAH and BSO.

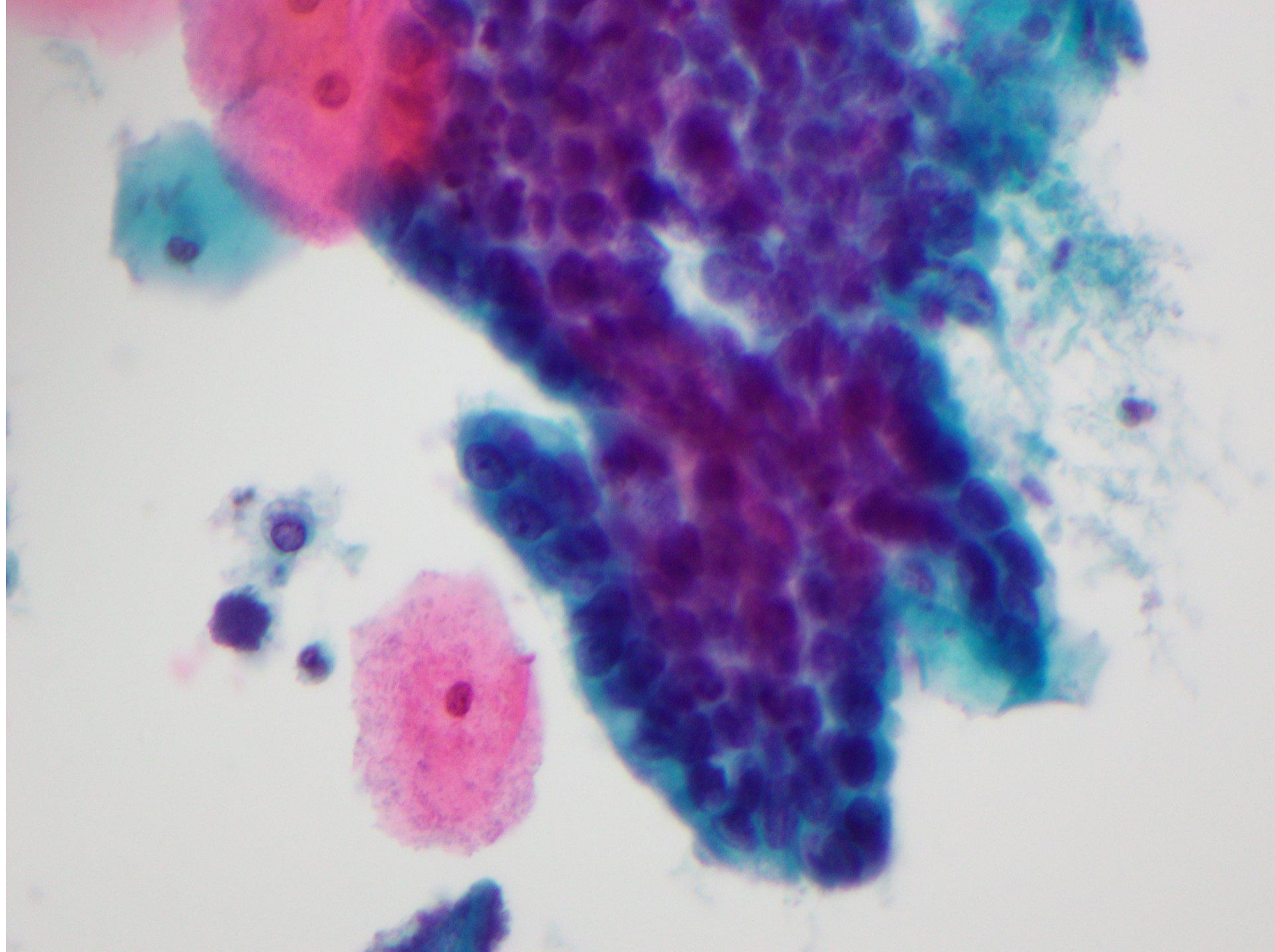






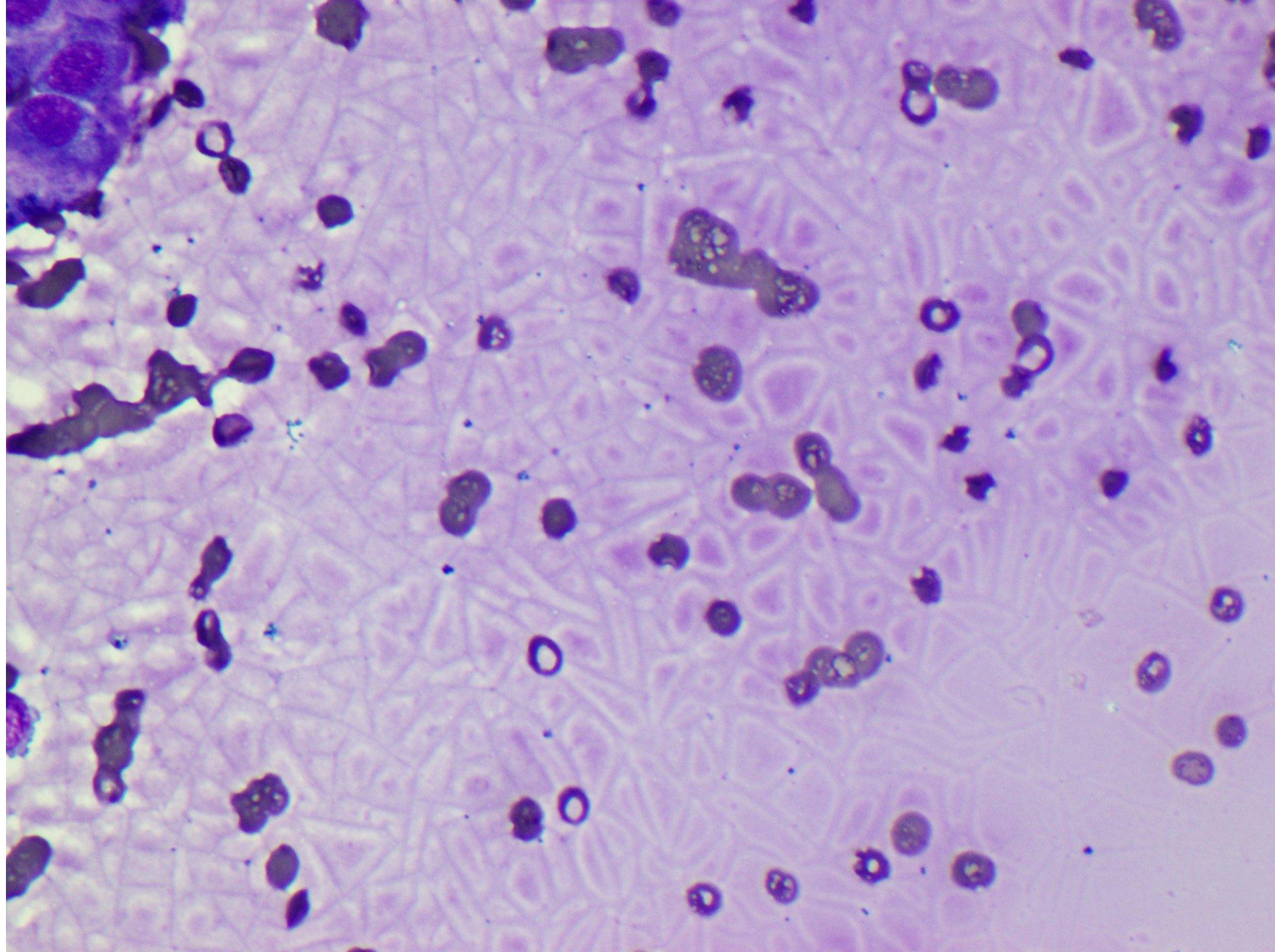


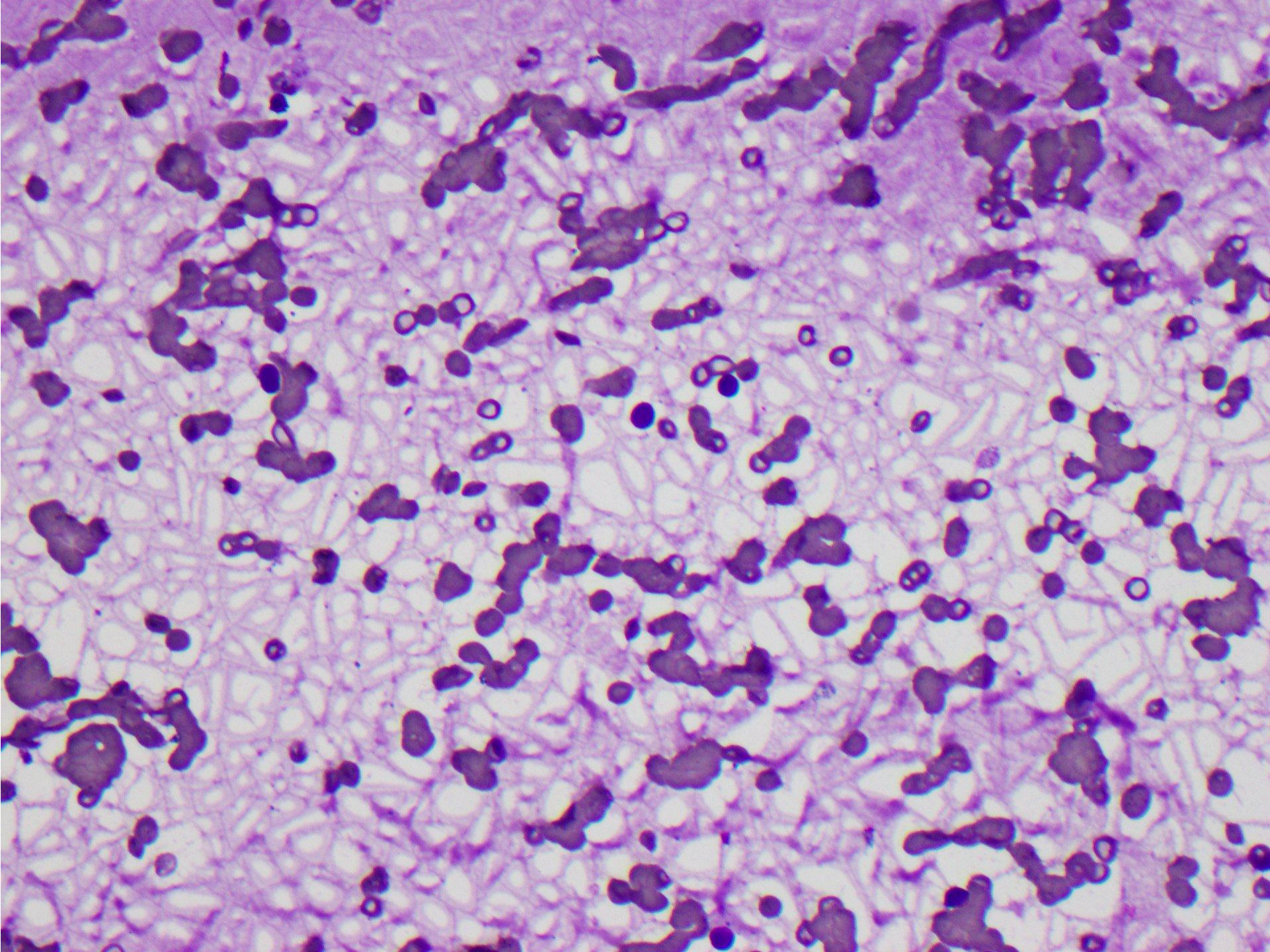


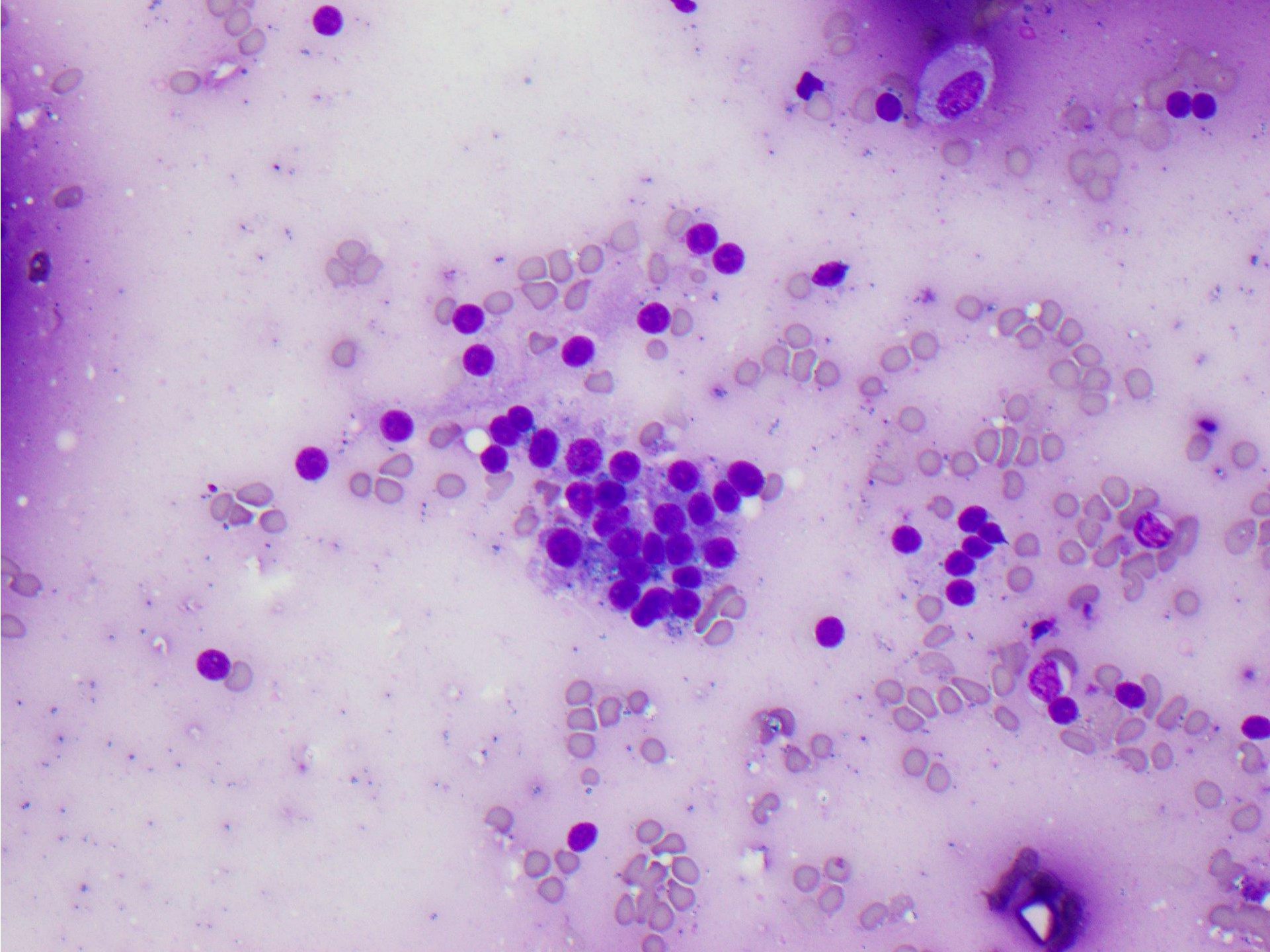


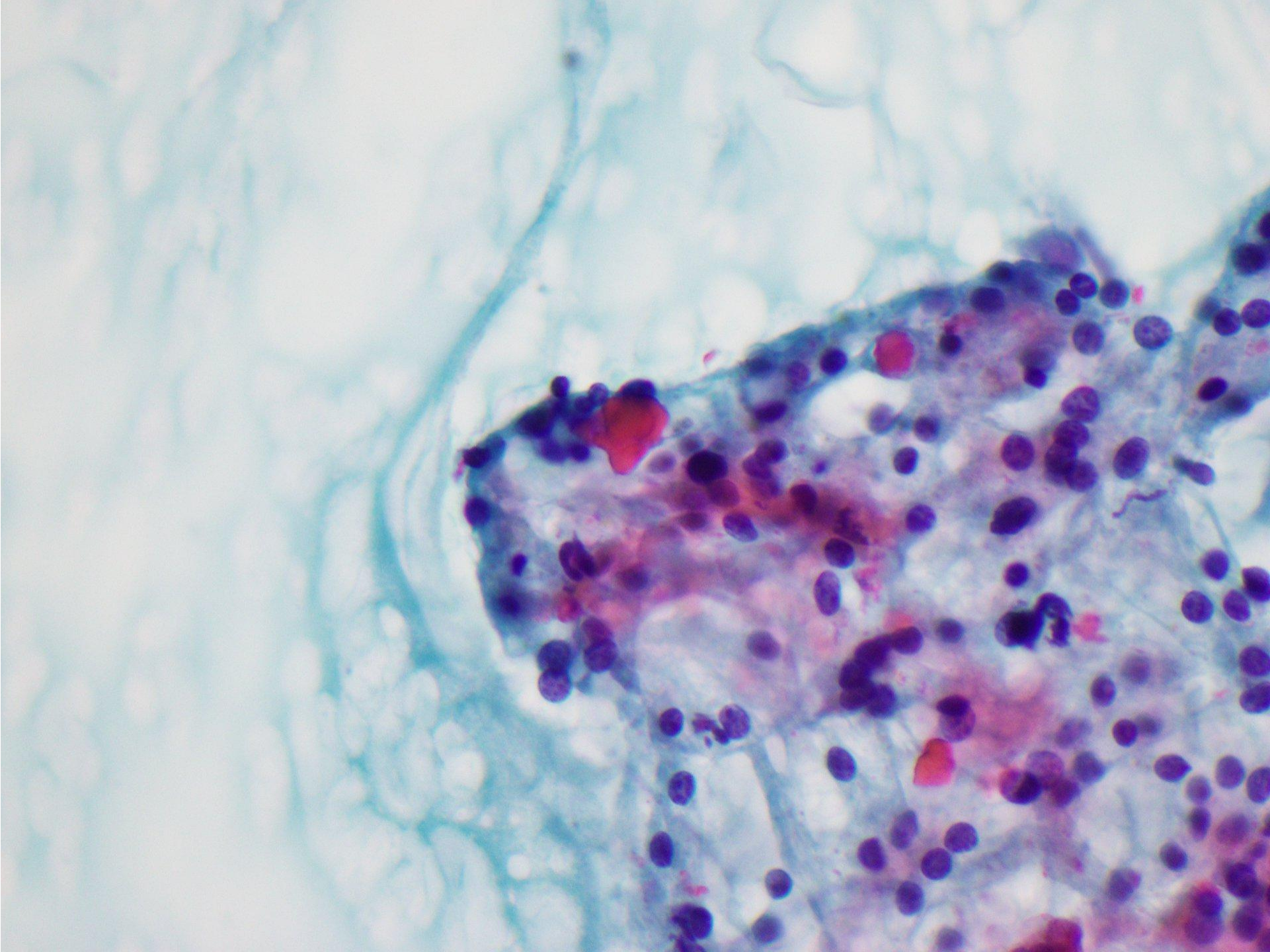
Case 27

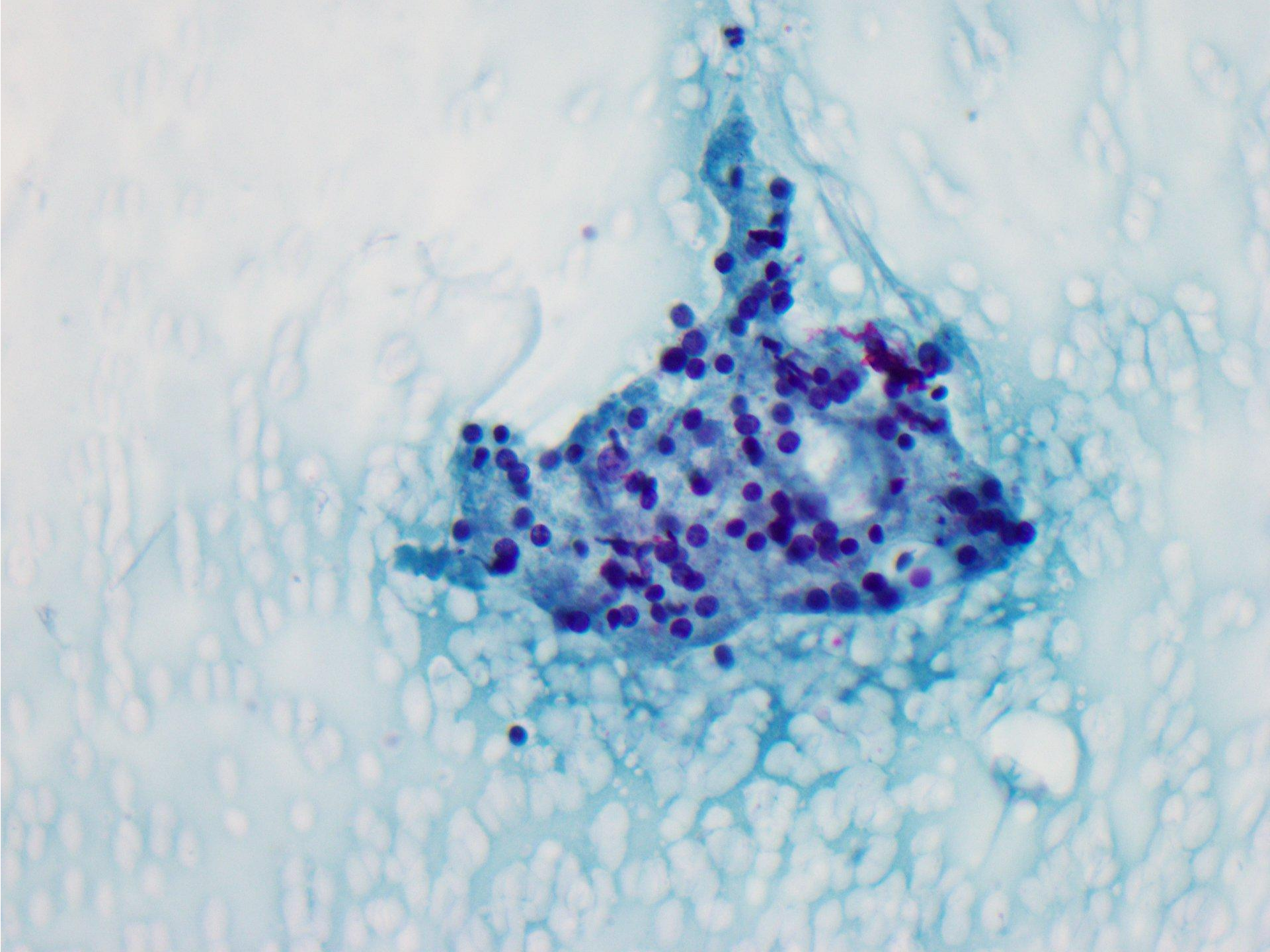
F25. FNA thyroid nodule.





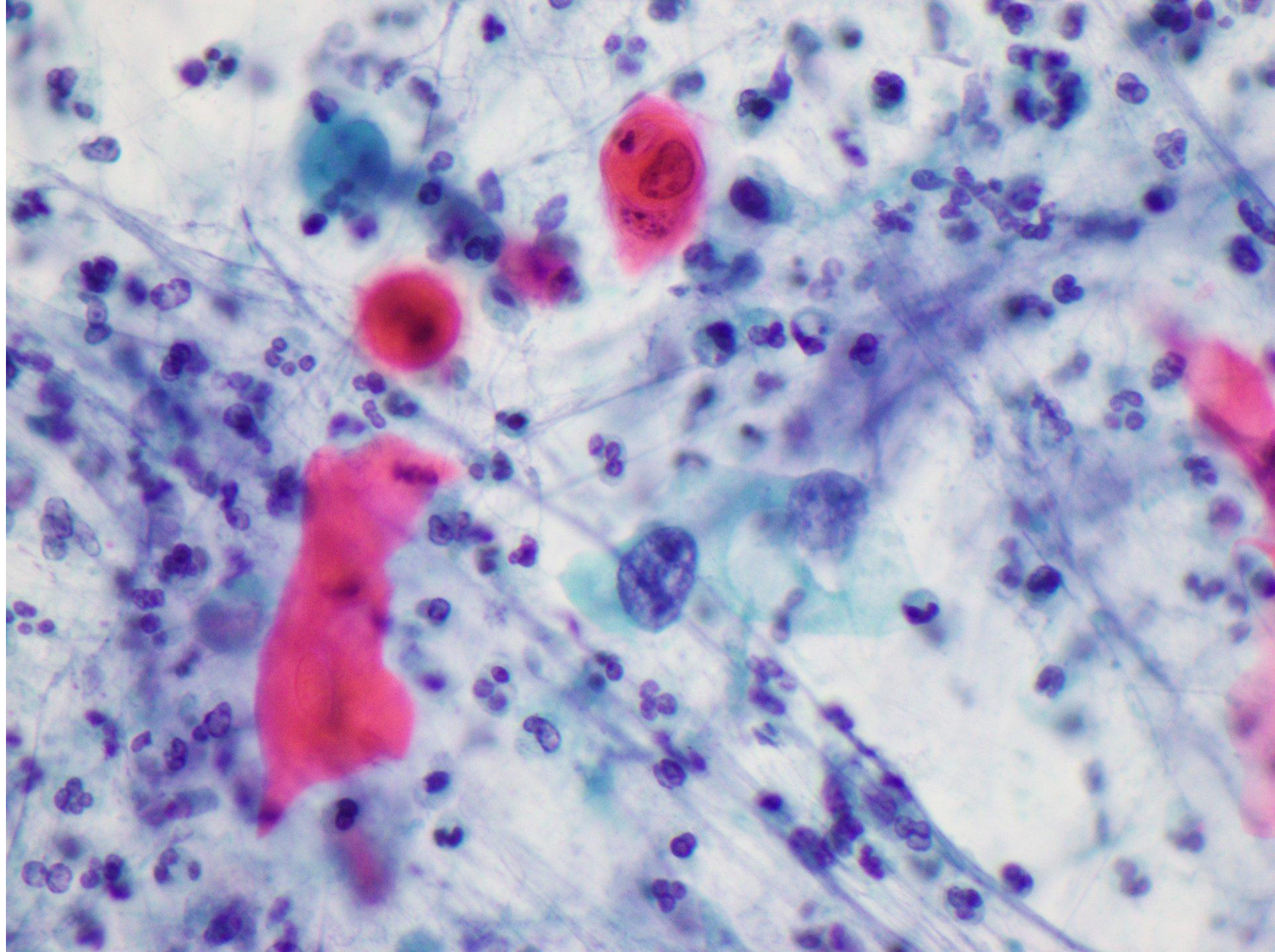


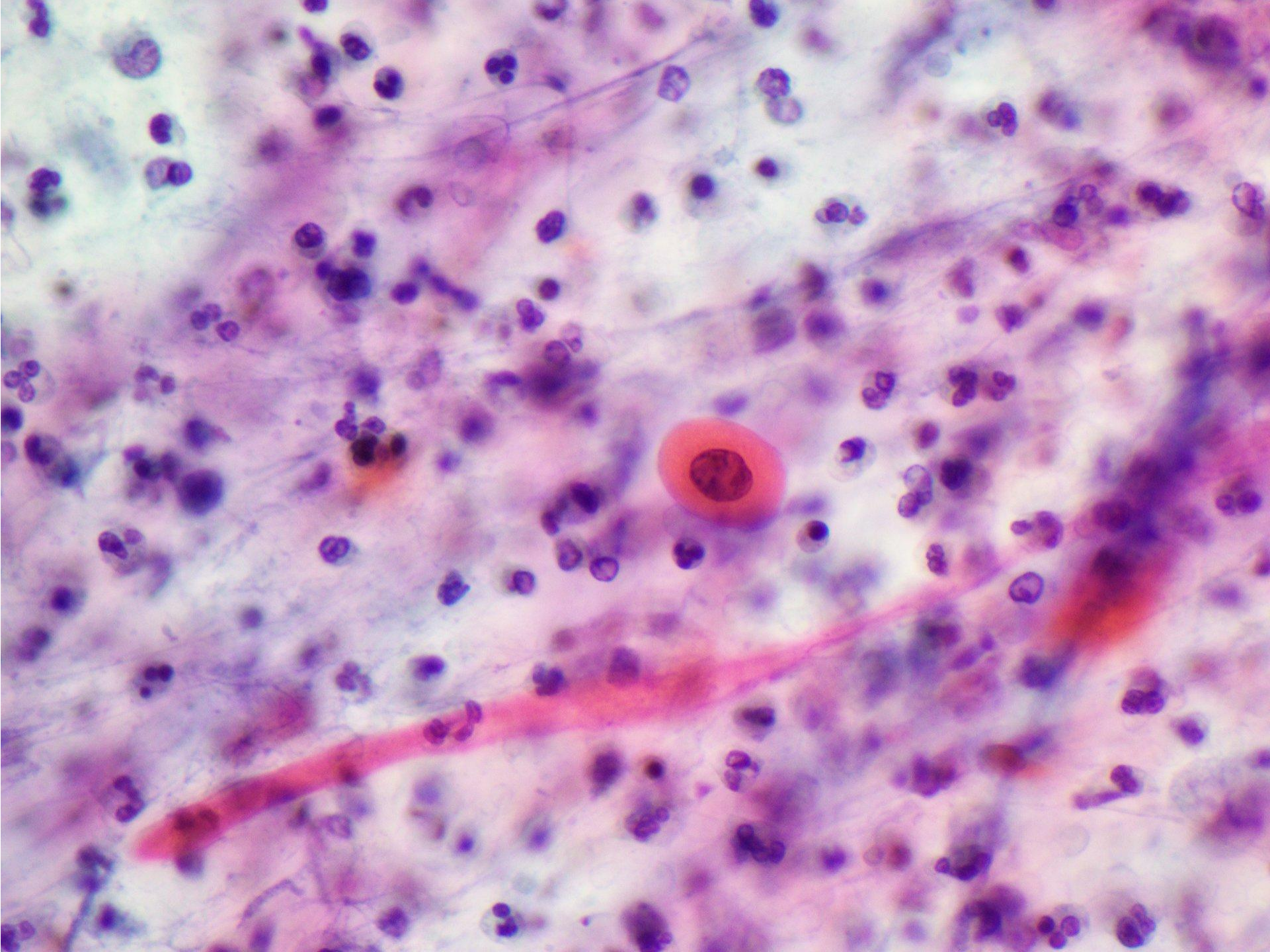


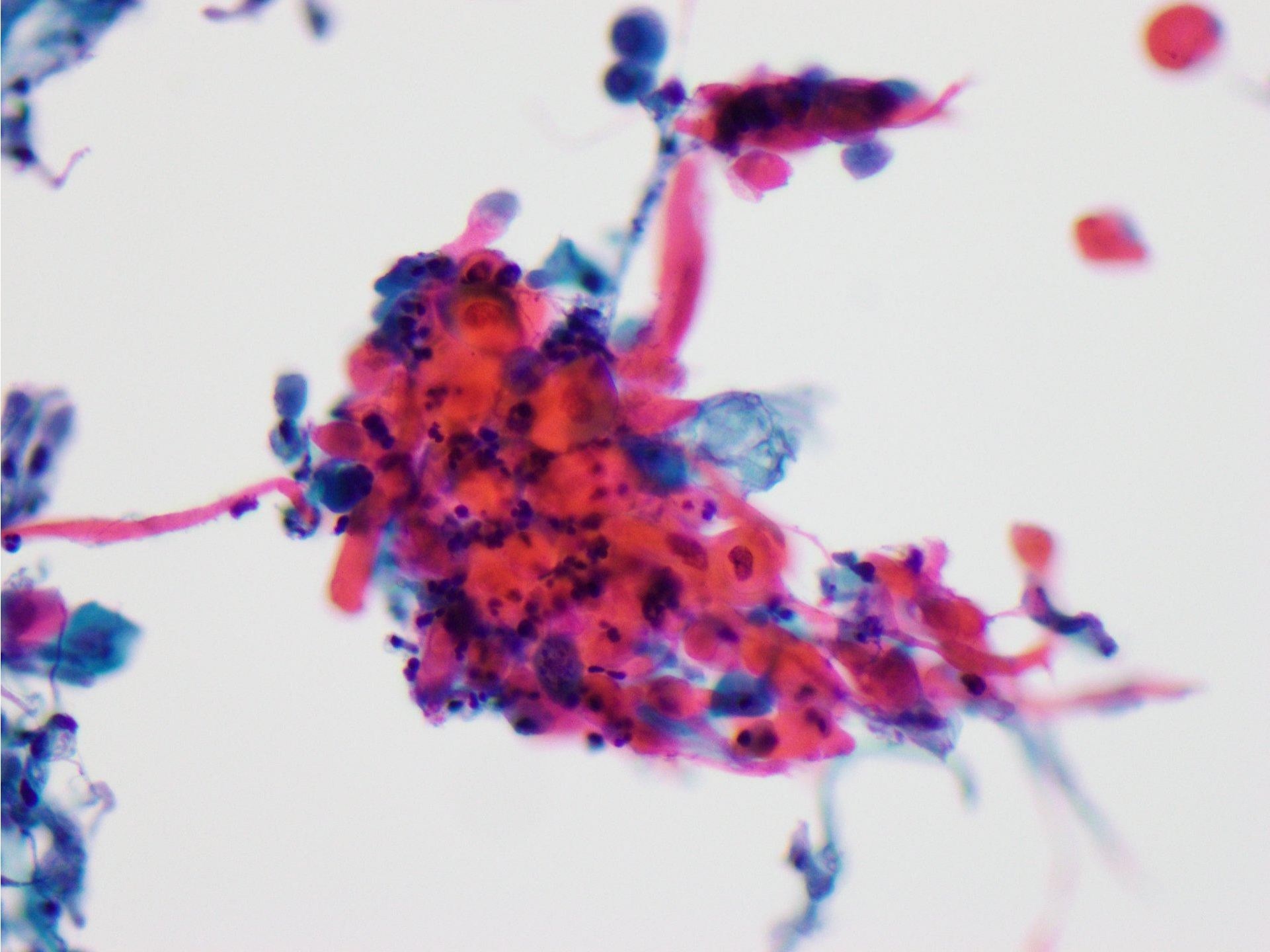


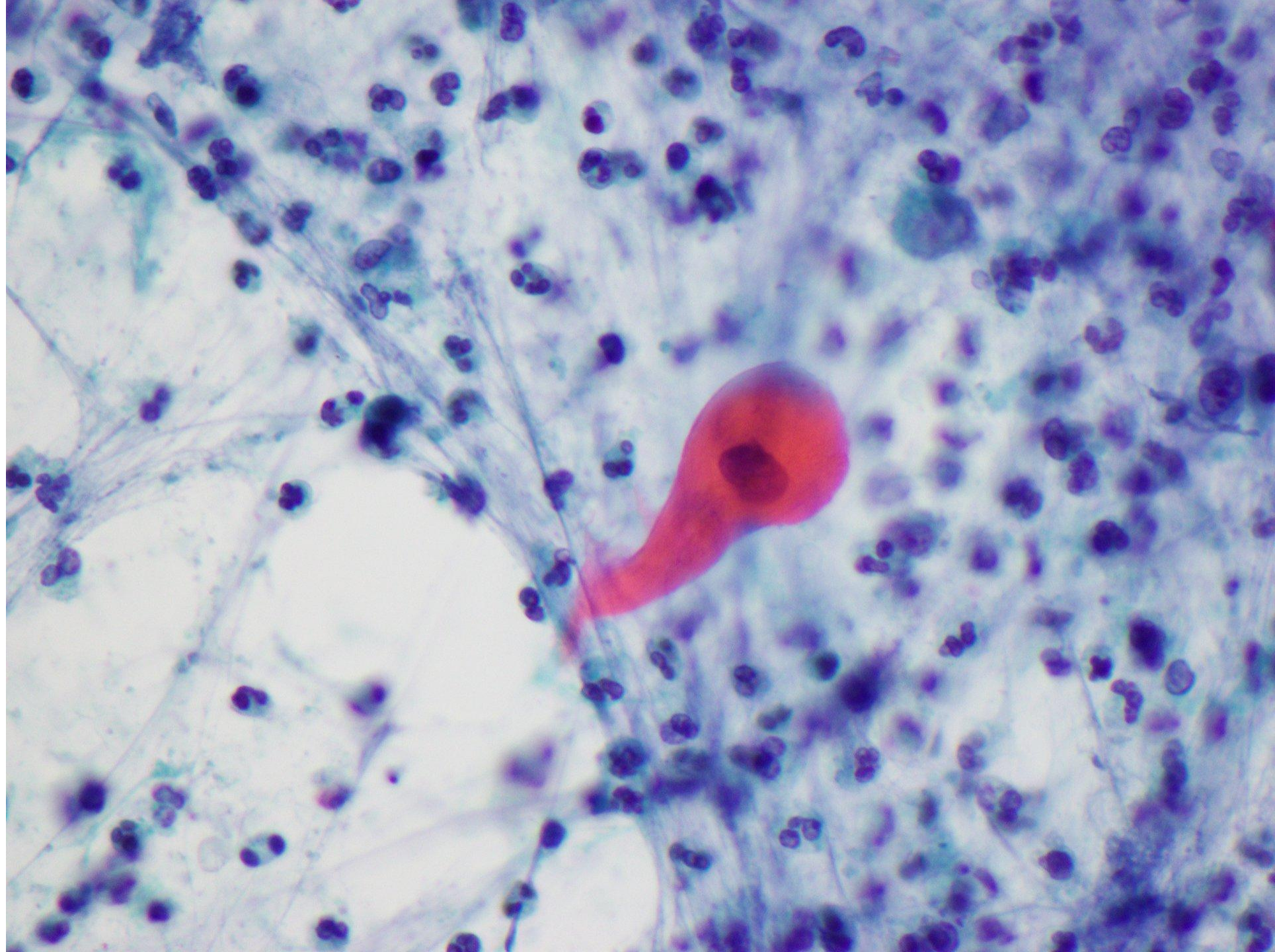
Case 28

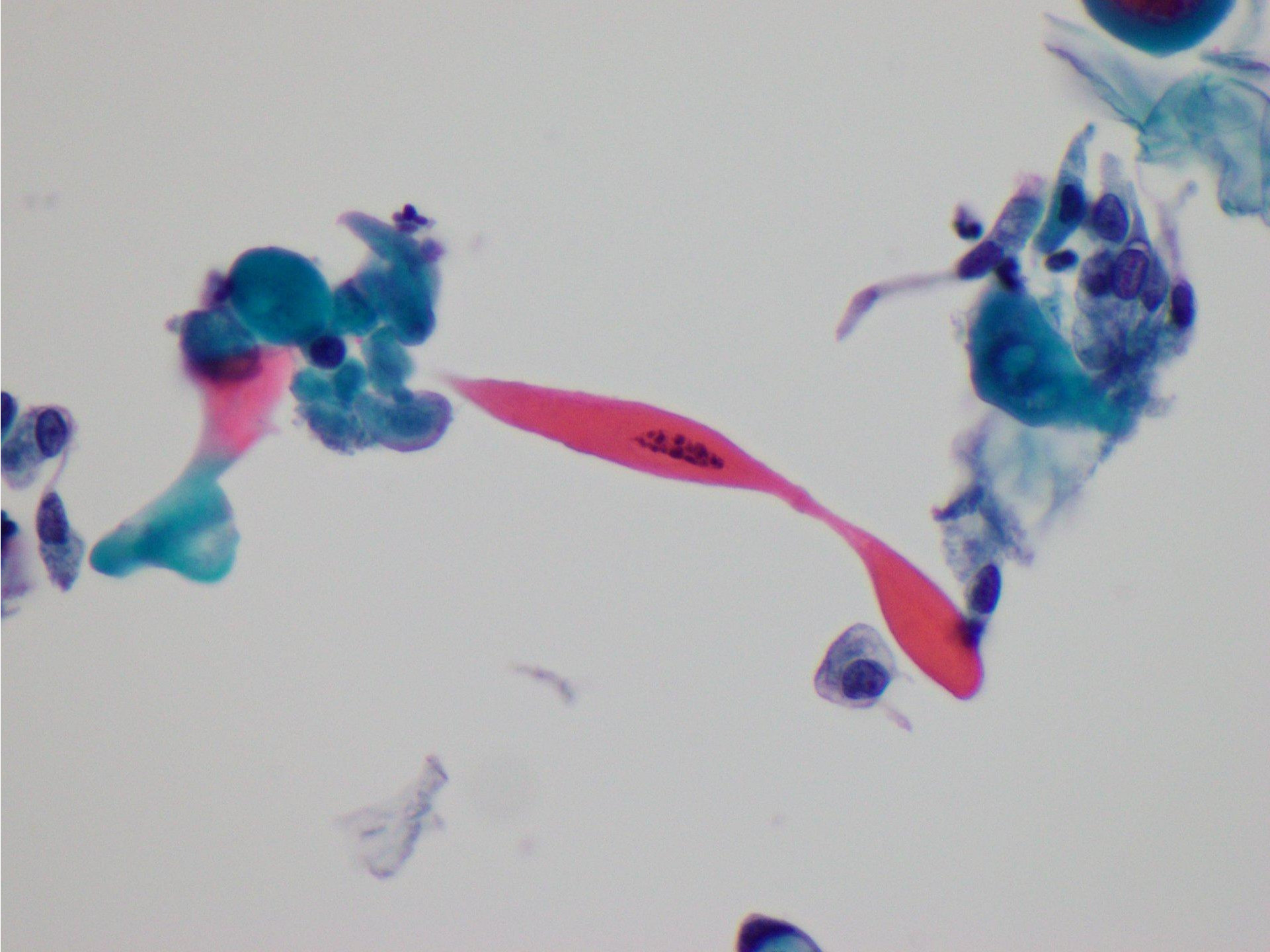
M63. Sputum.





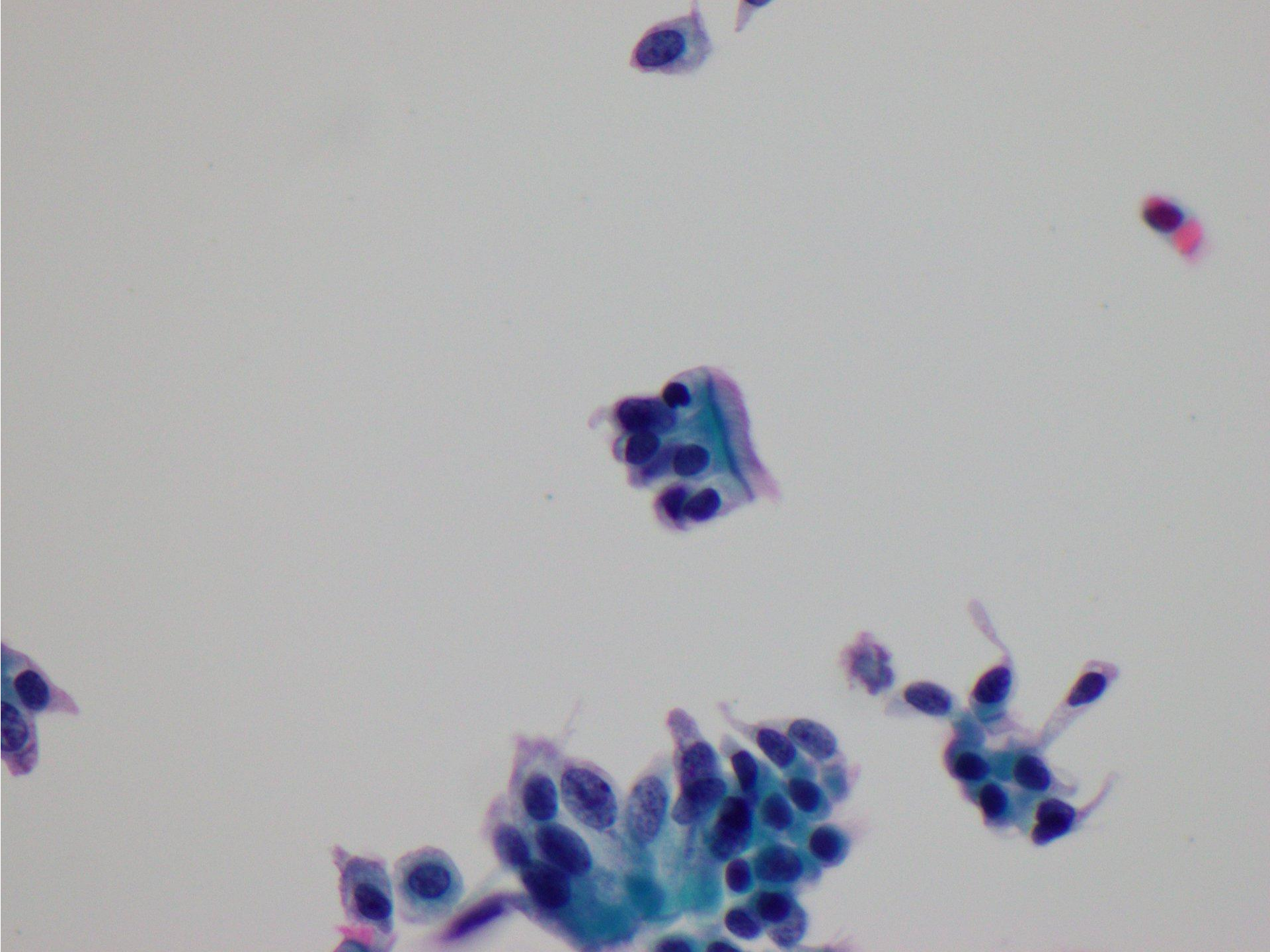


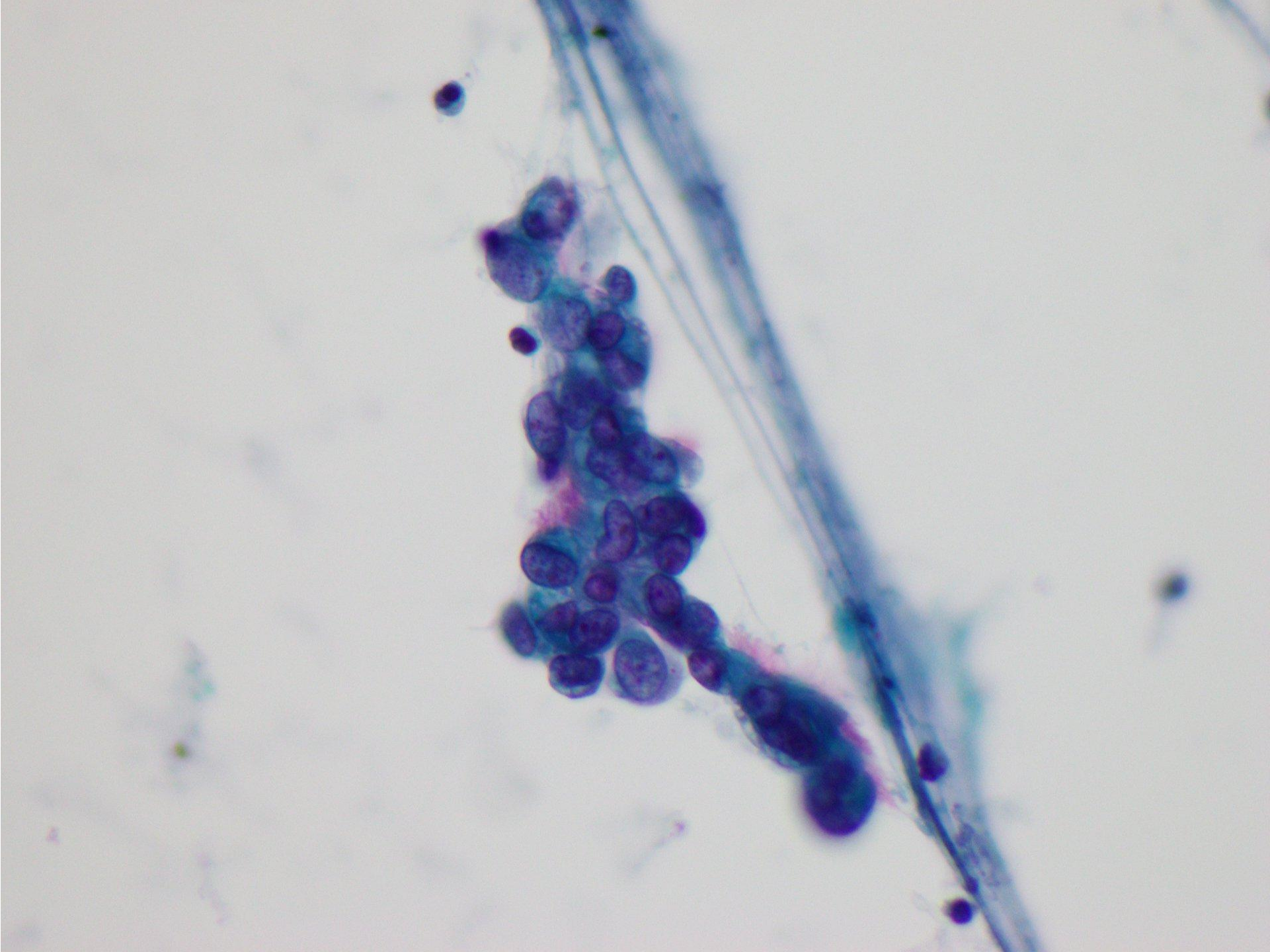


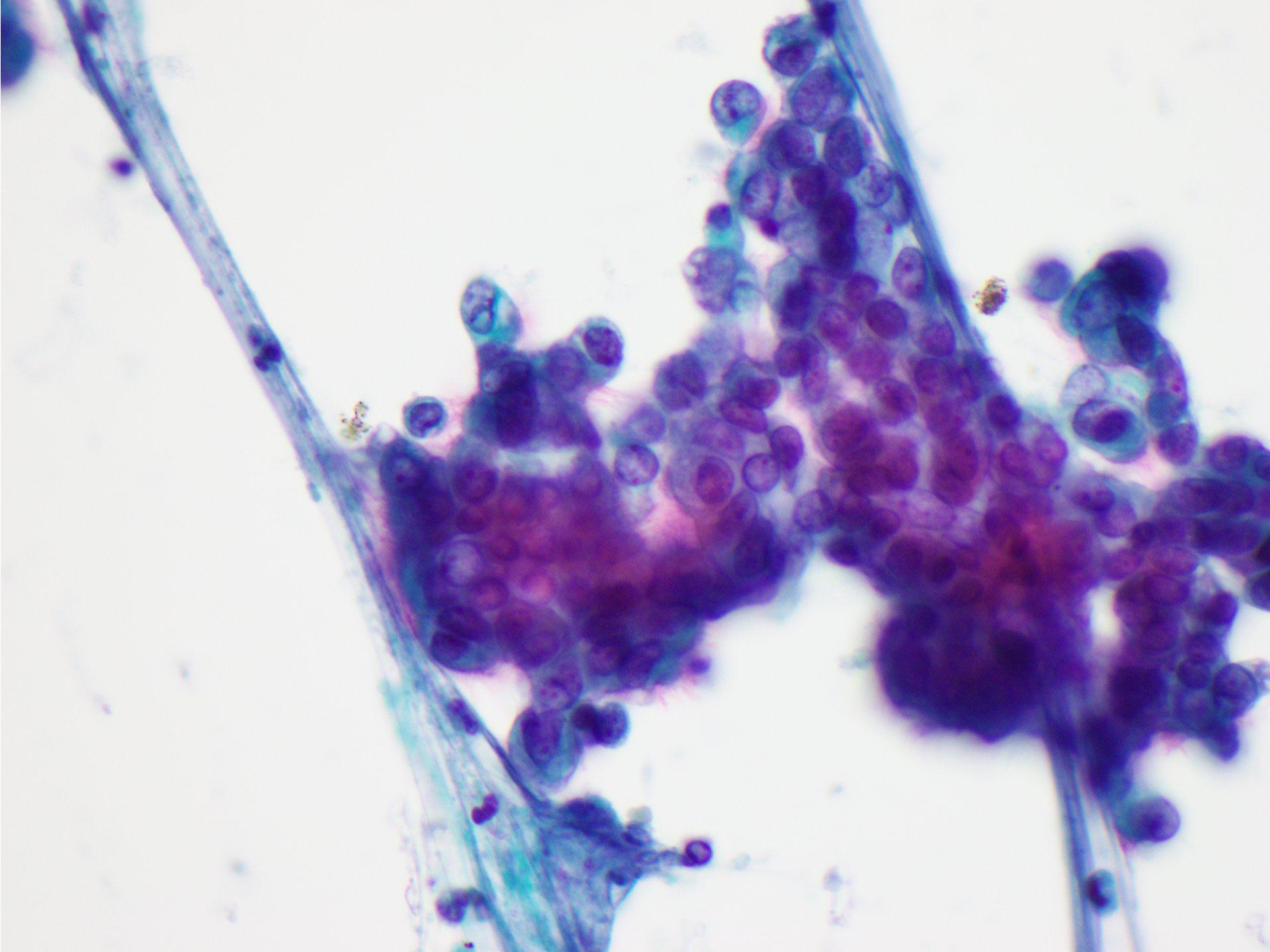


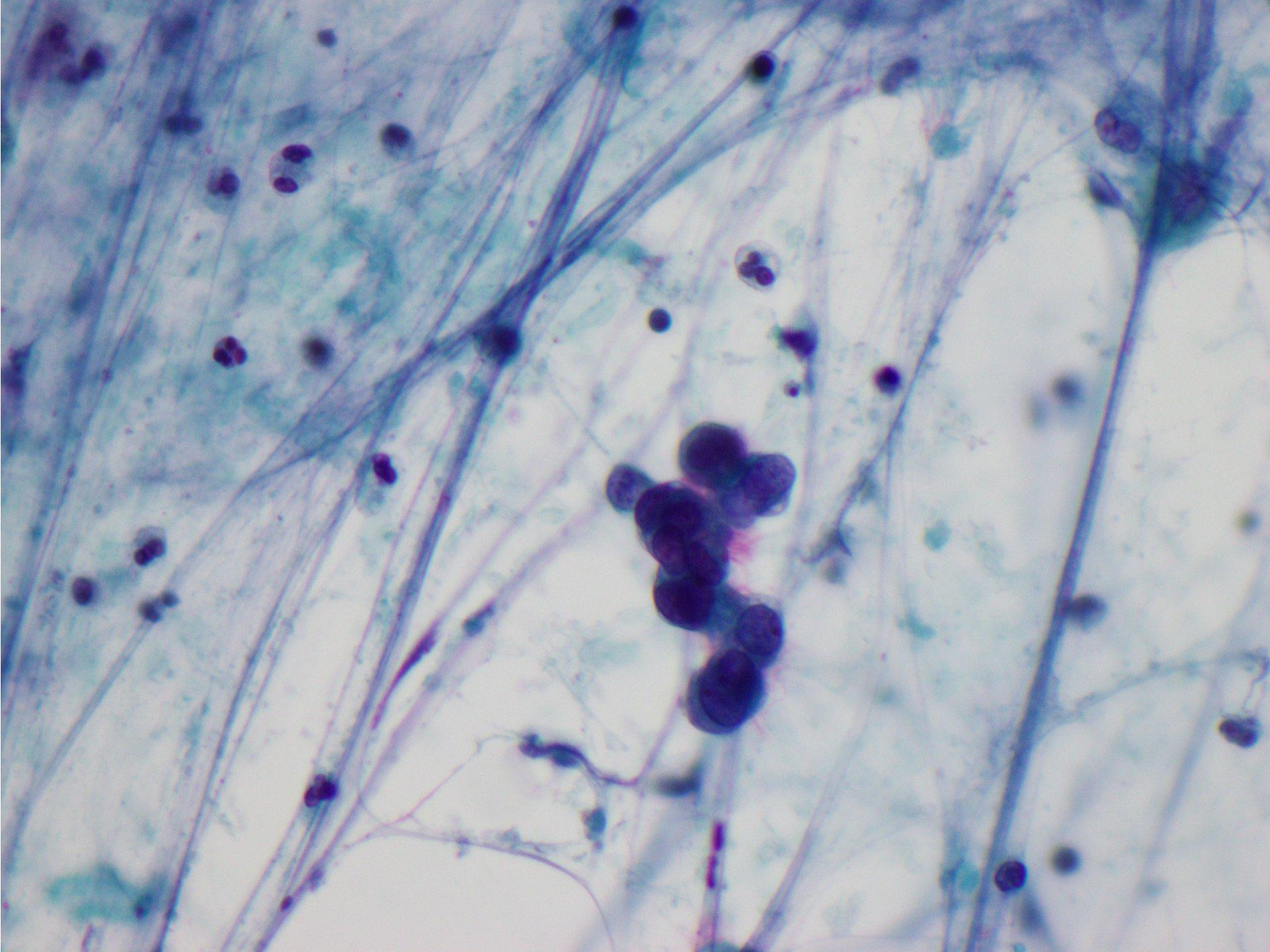
Case 29

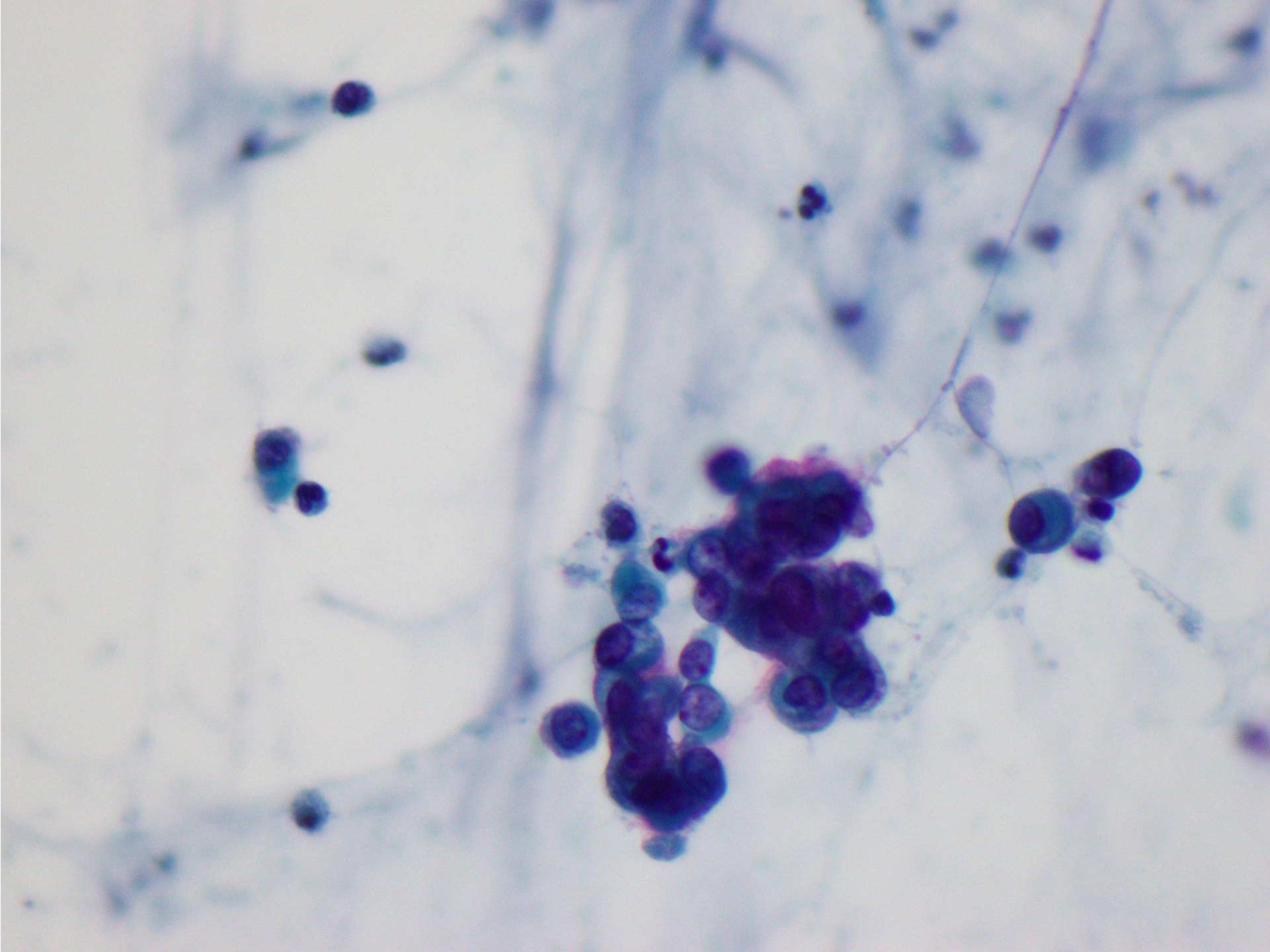
F45. Chronic cough. Bronchial brushings





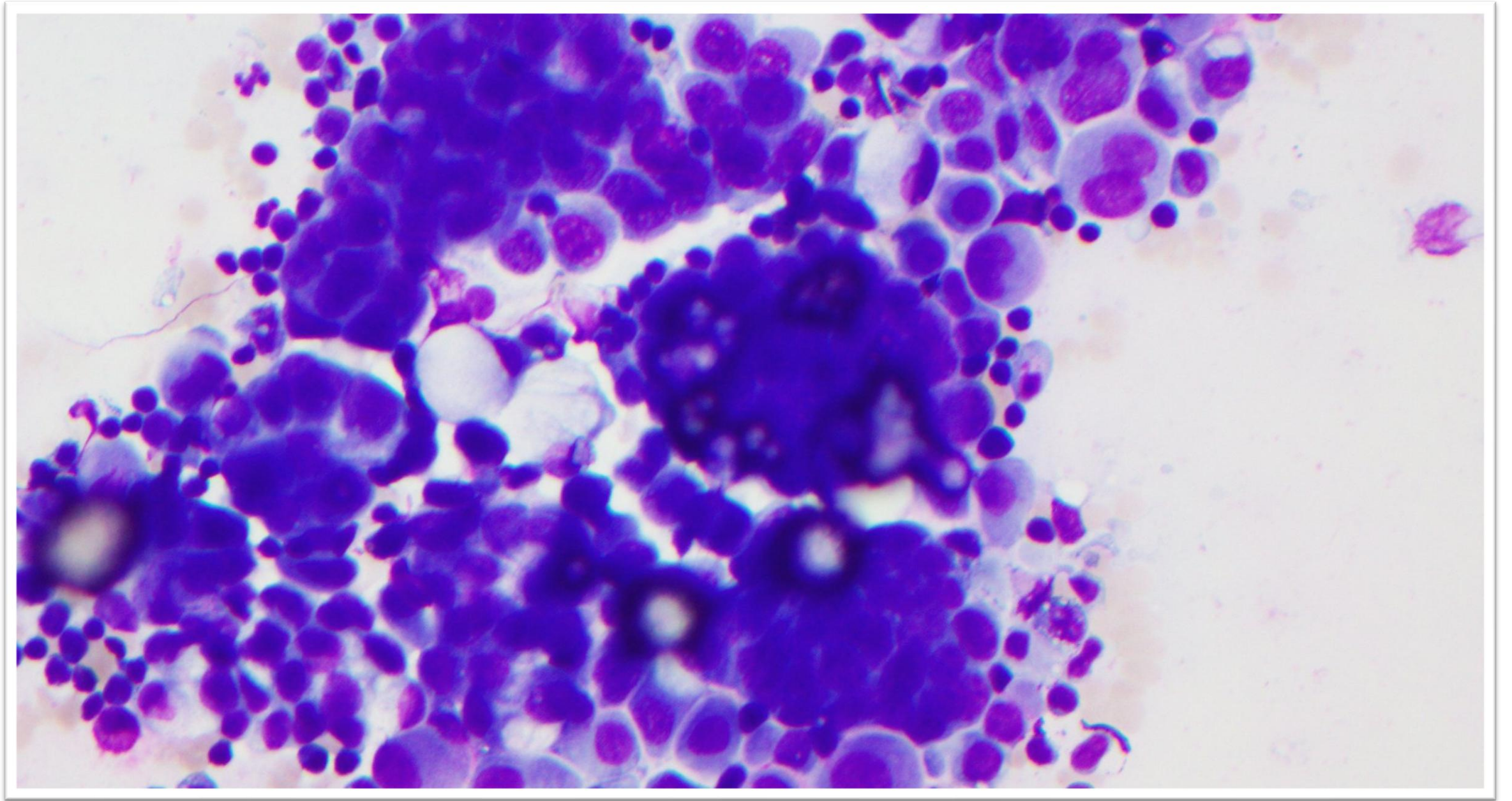


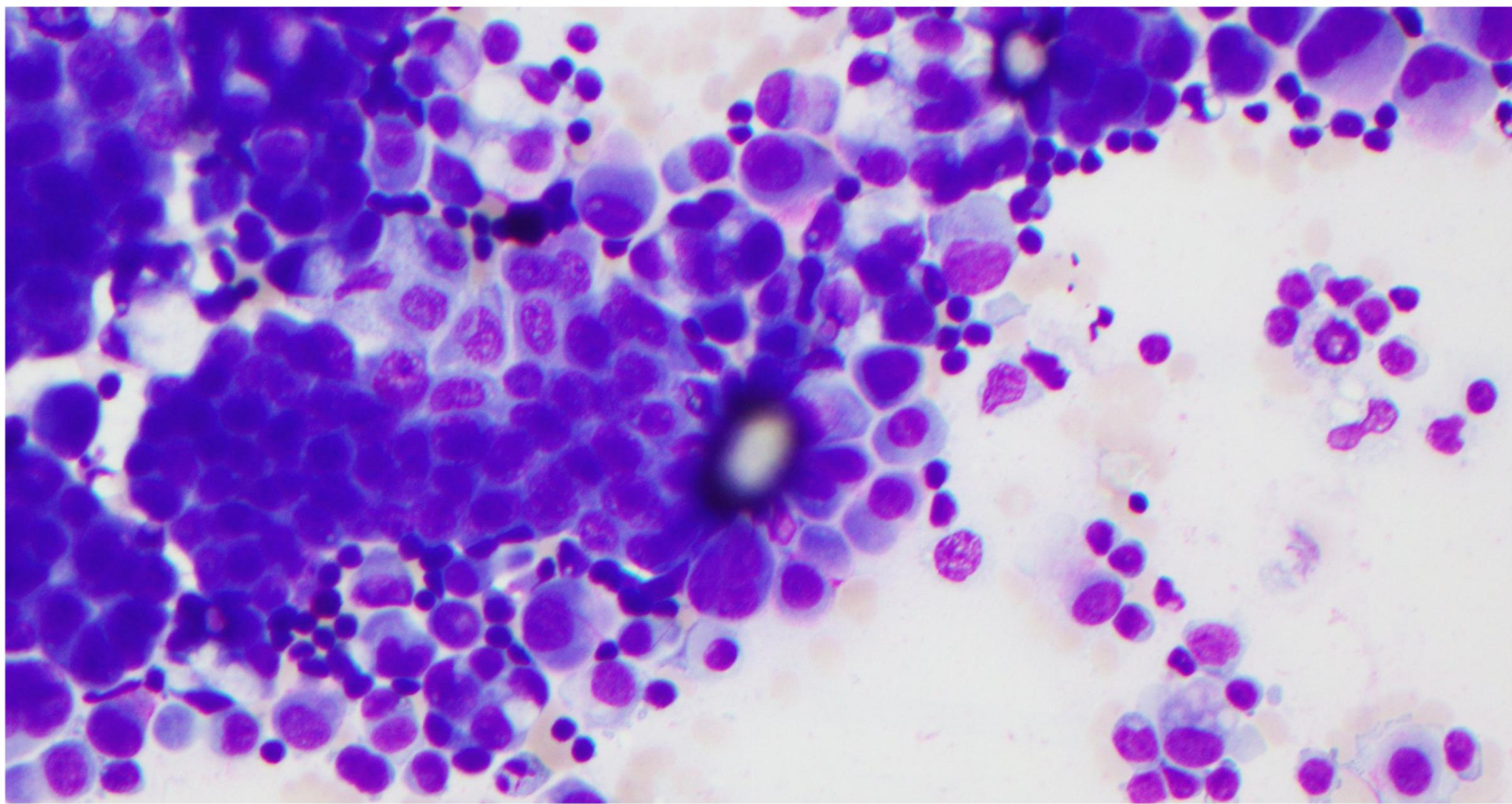


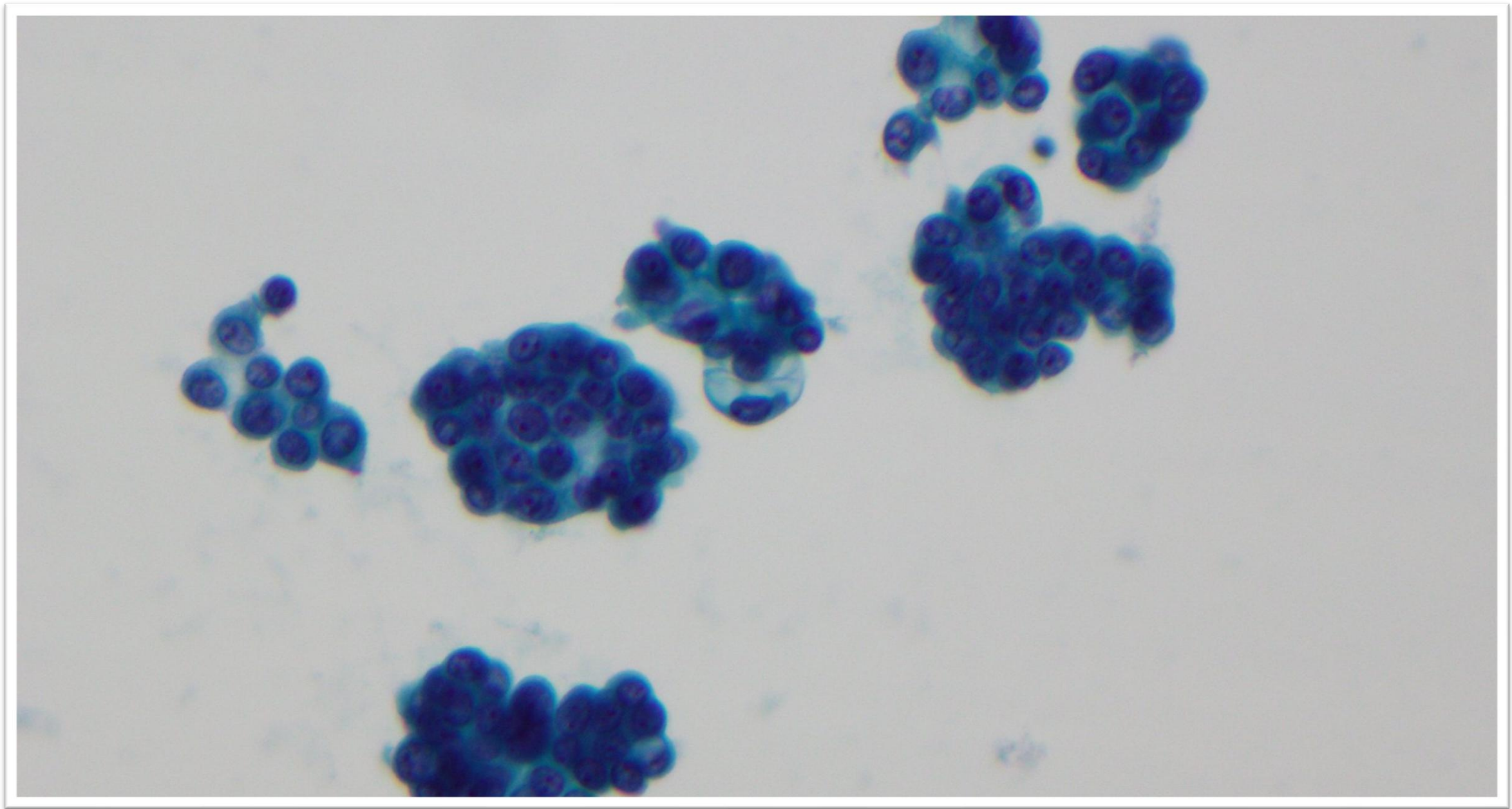


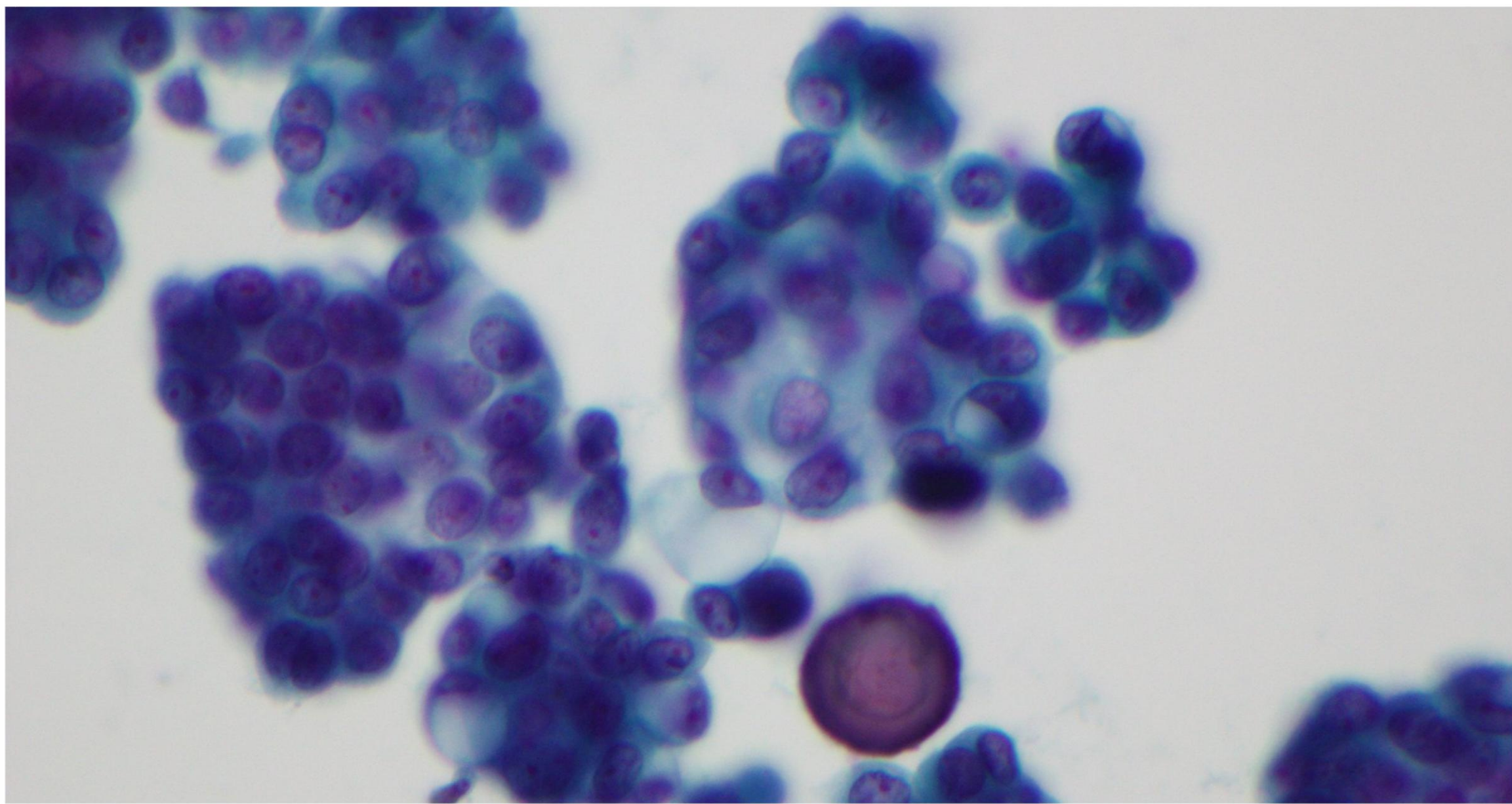
Case 30

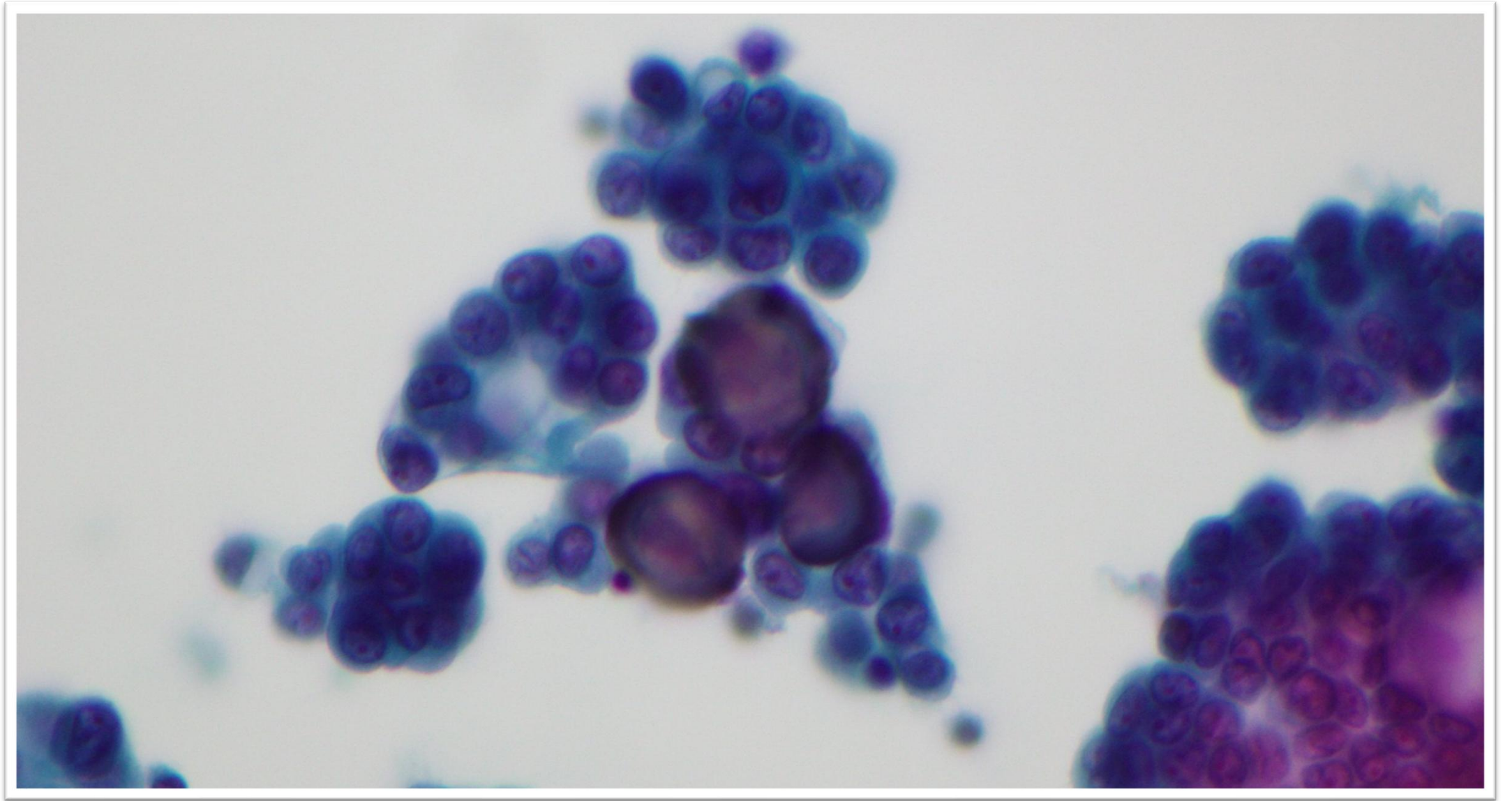
F60. Peritoneal washings

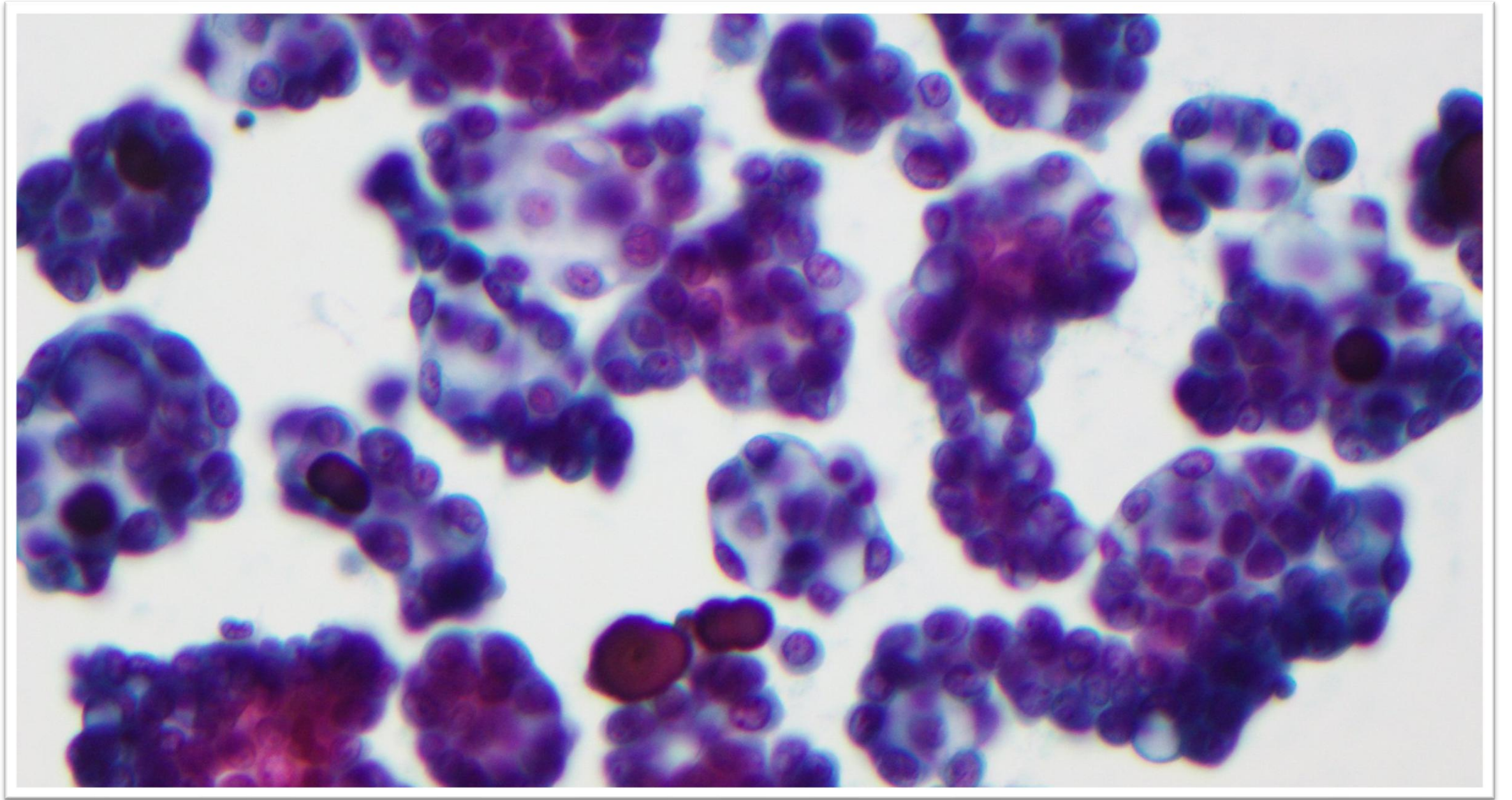








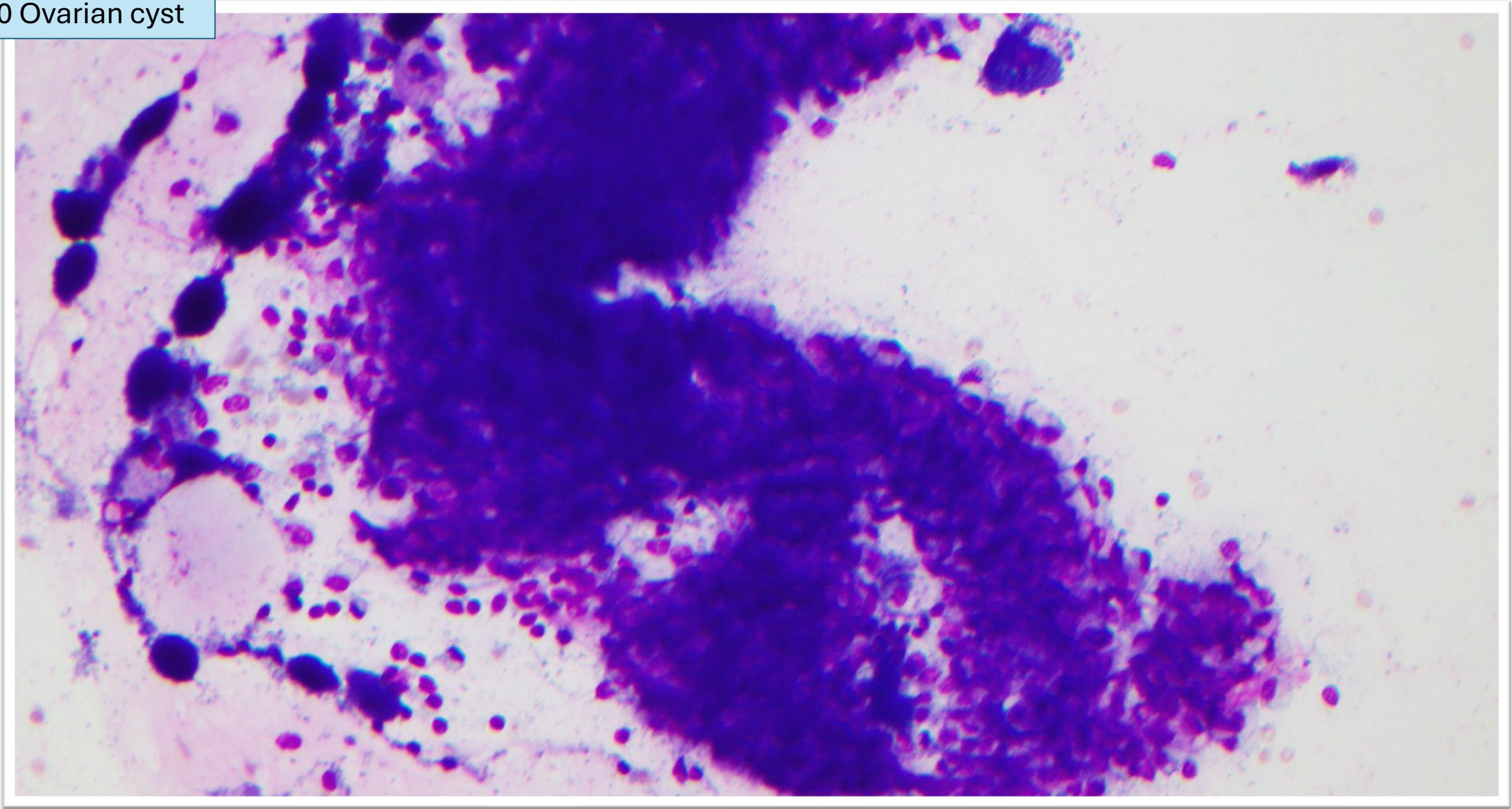


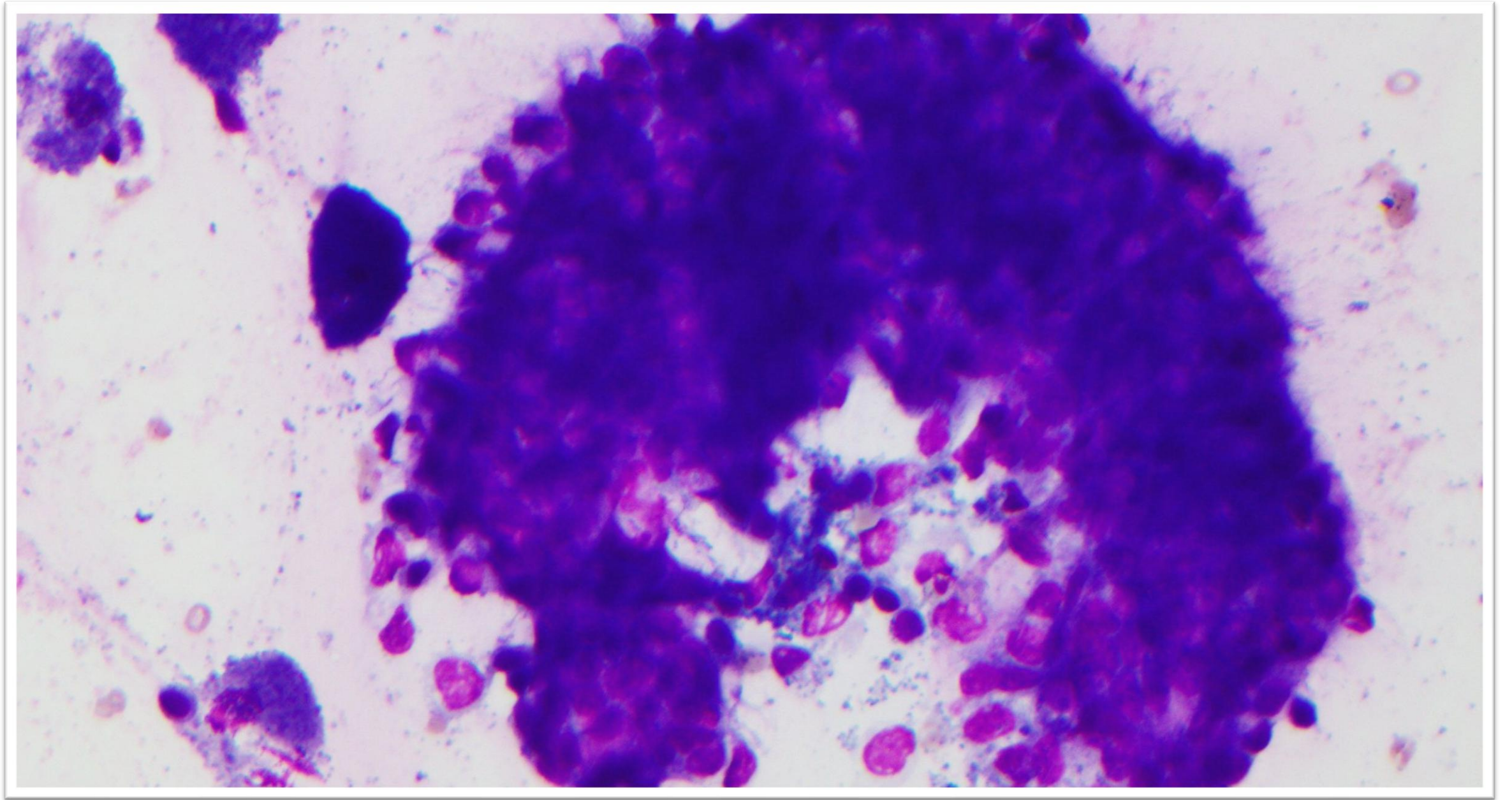


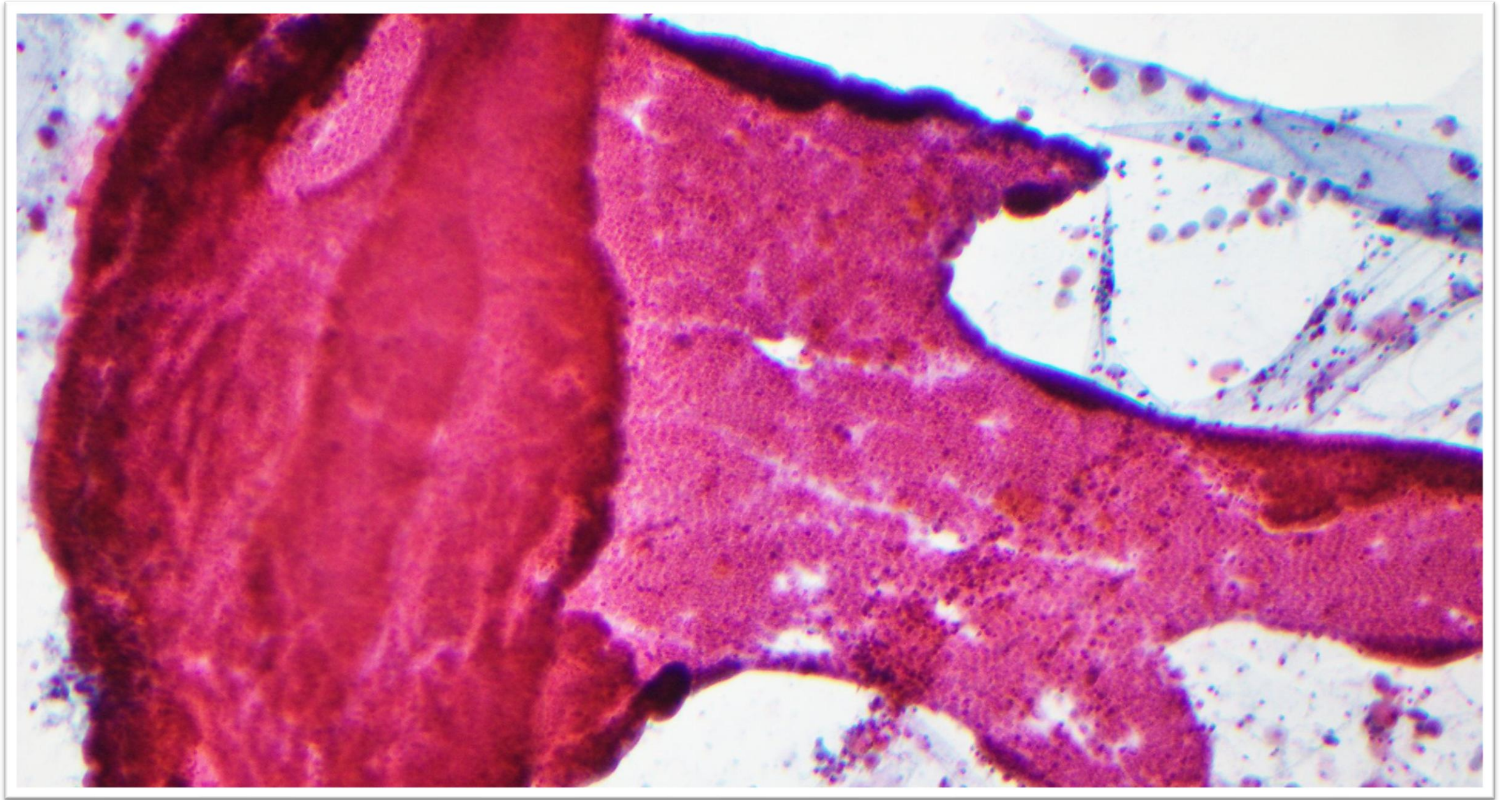
Case 31

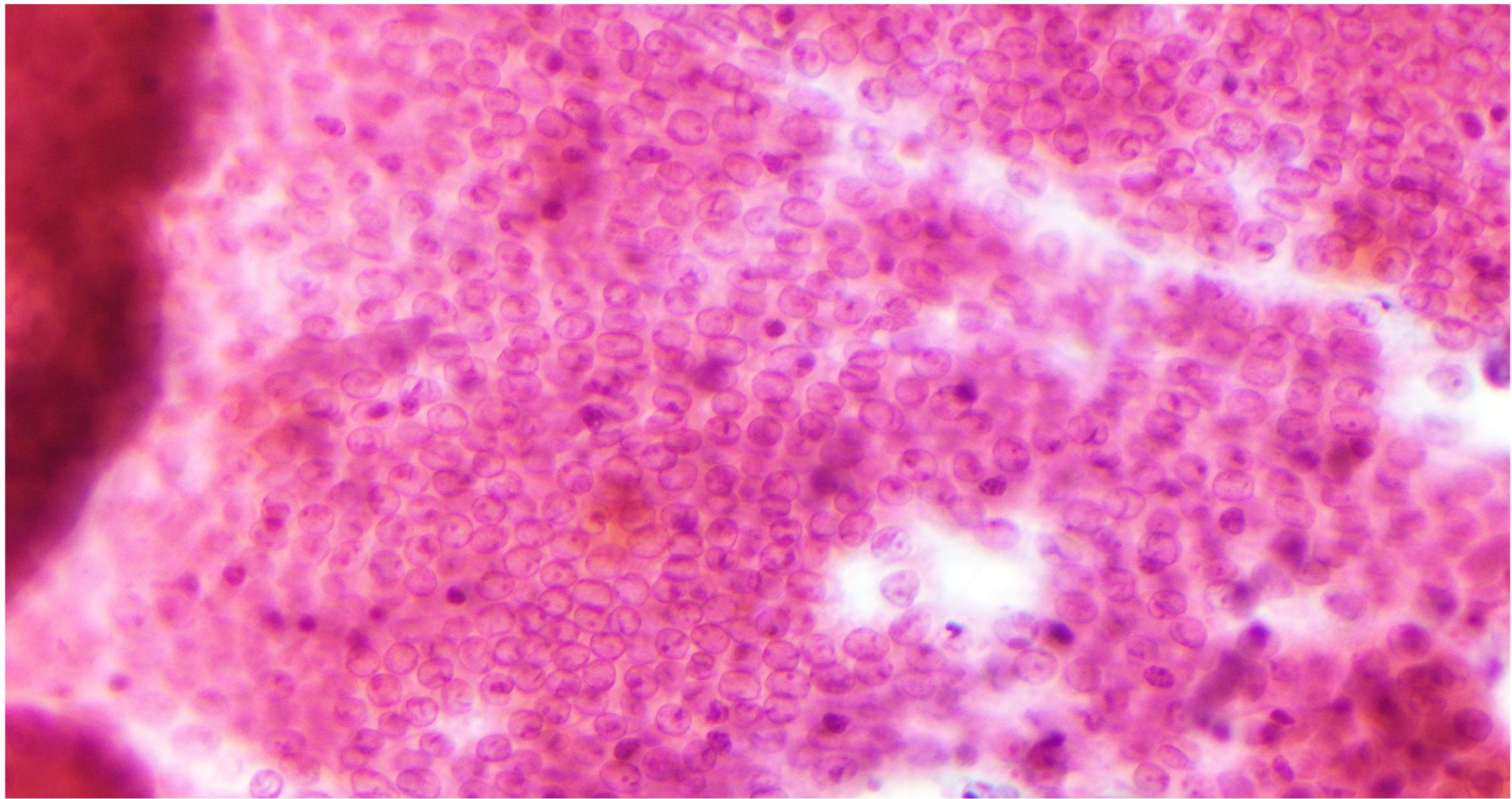
F50. FNA Ovarian cyst

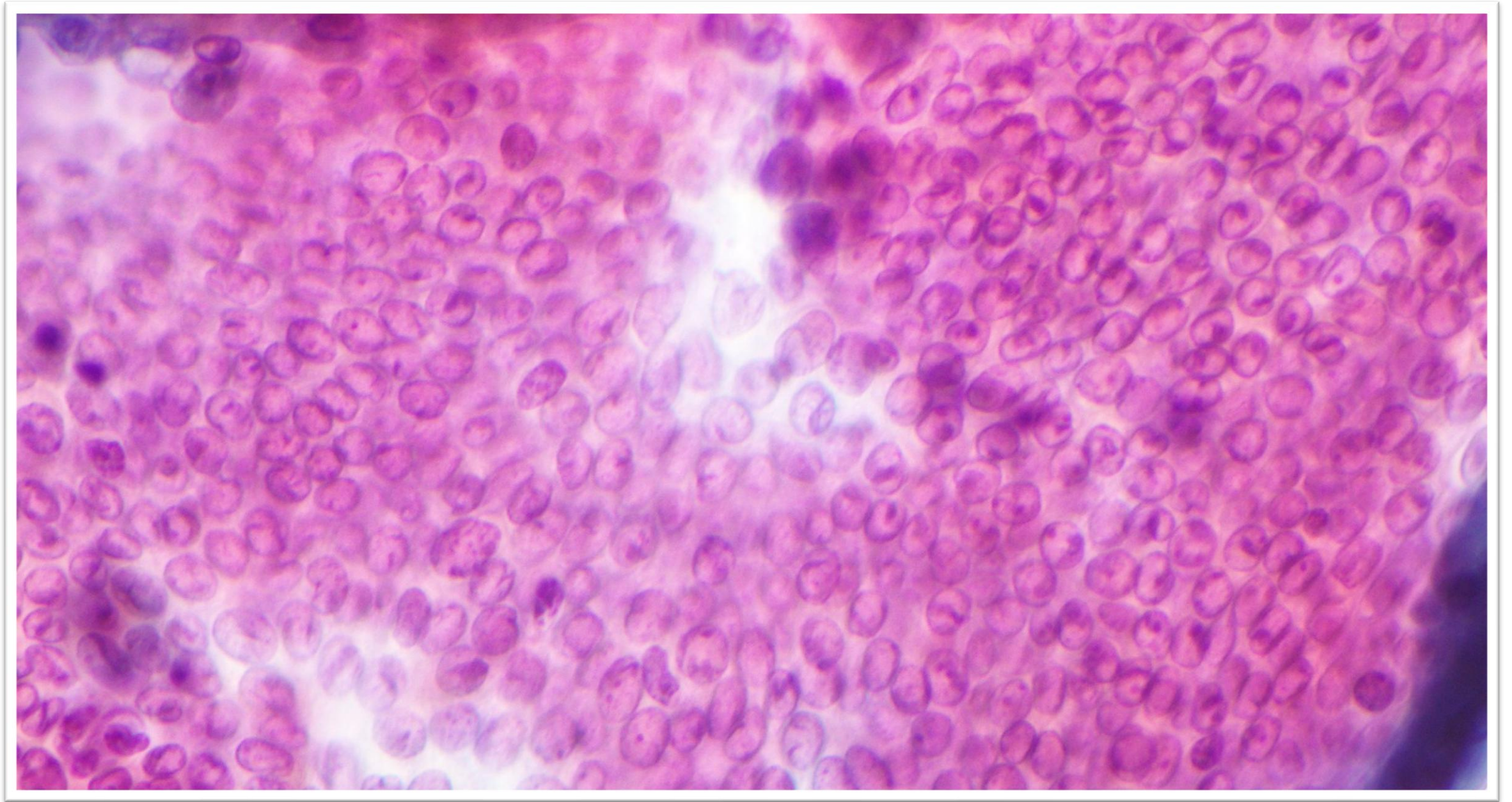
F50 Ovarian cyst

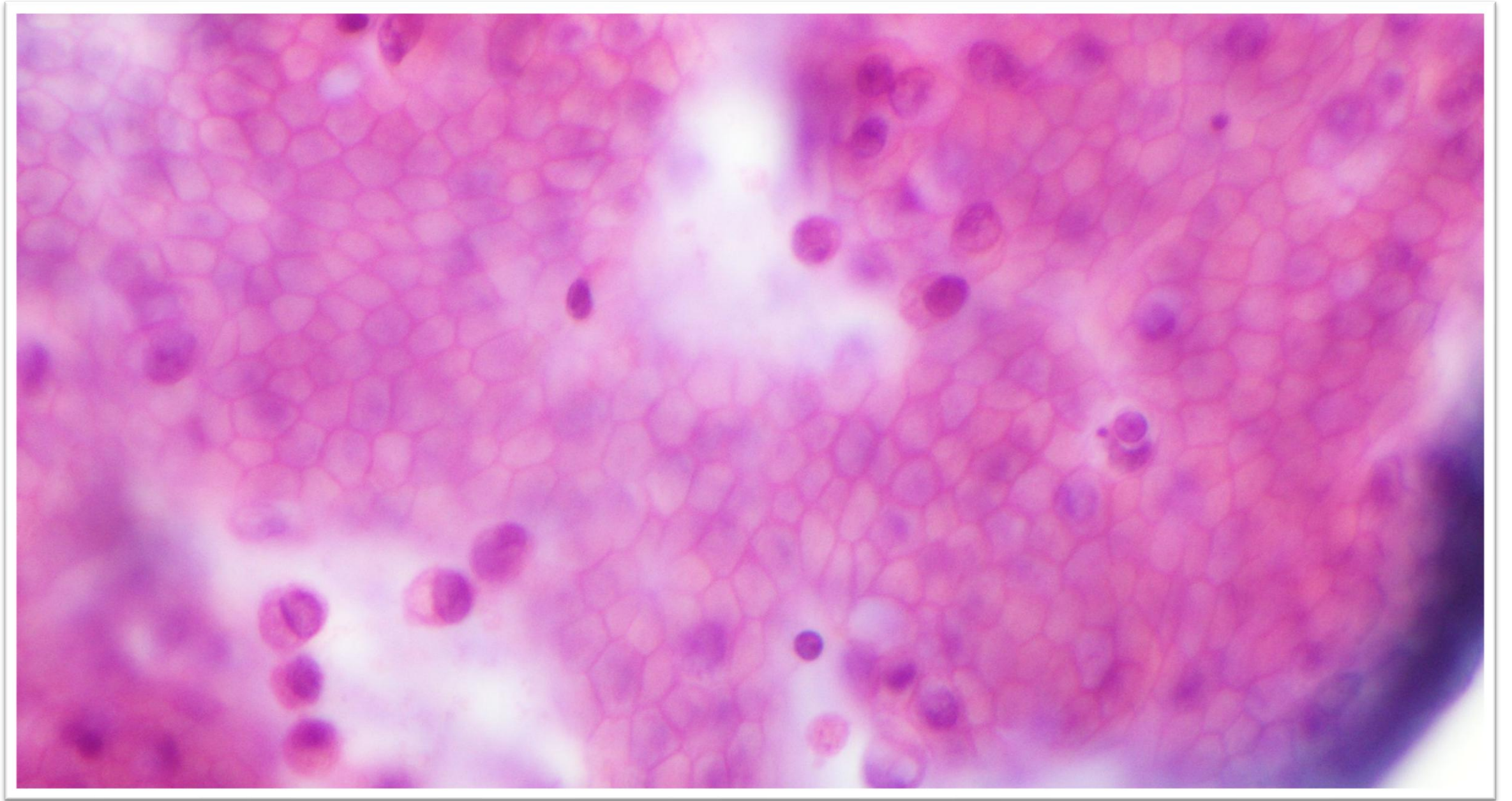


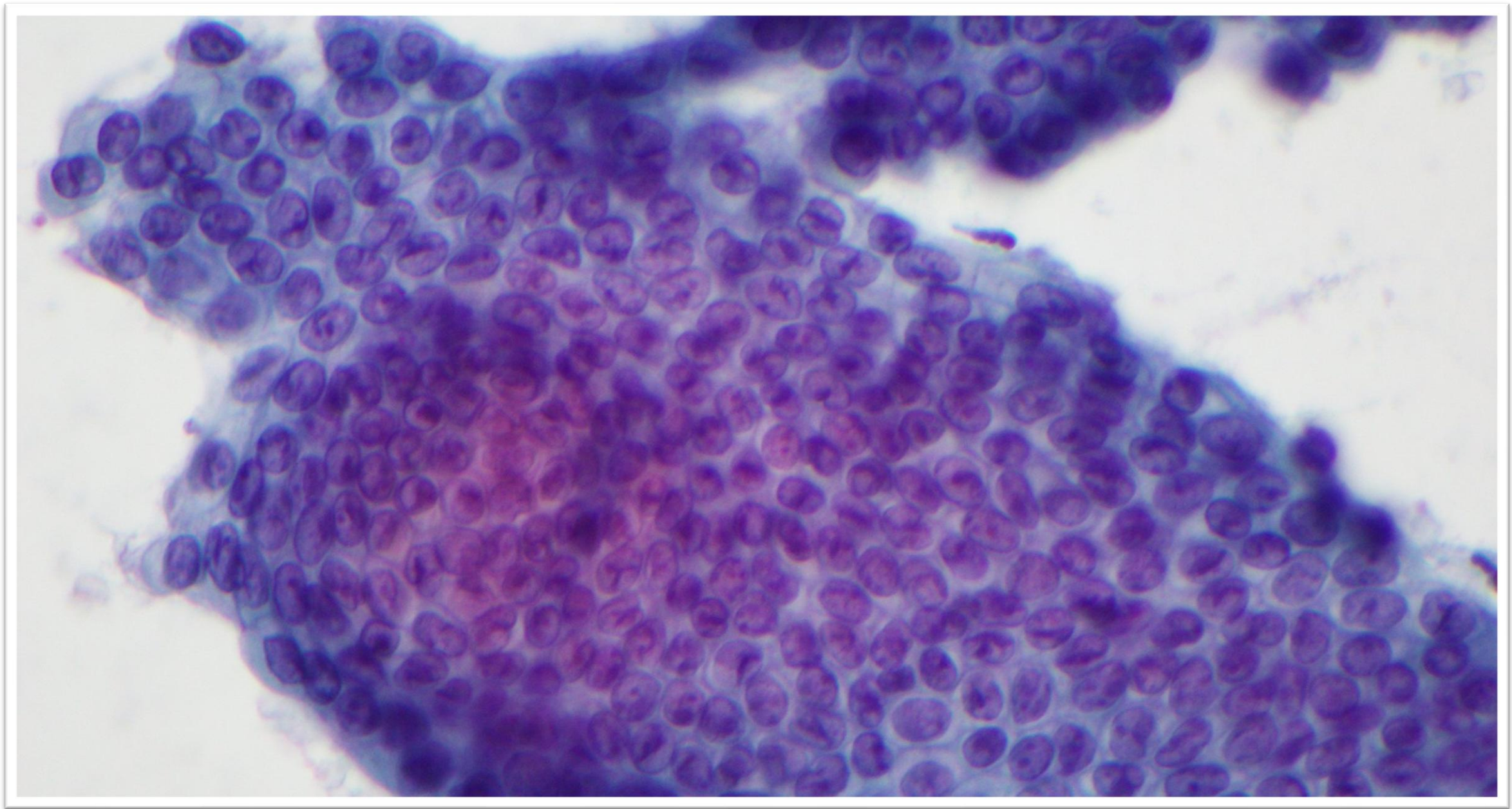


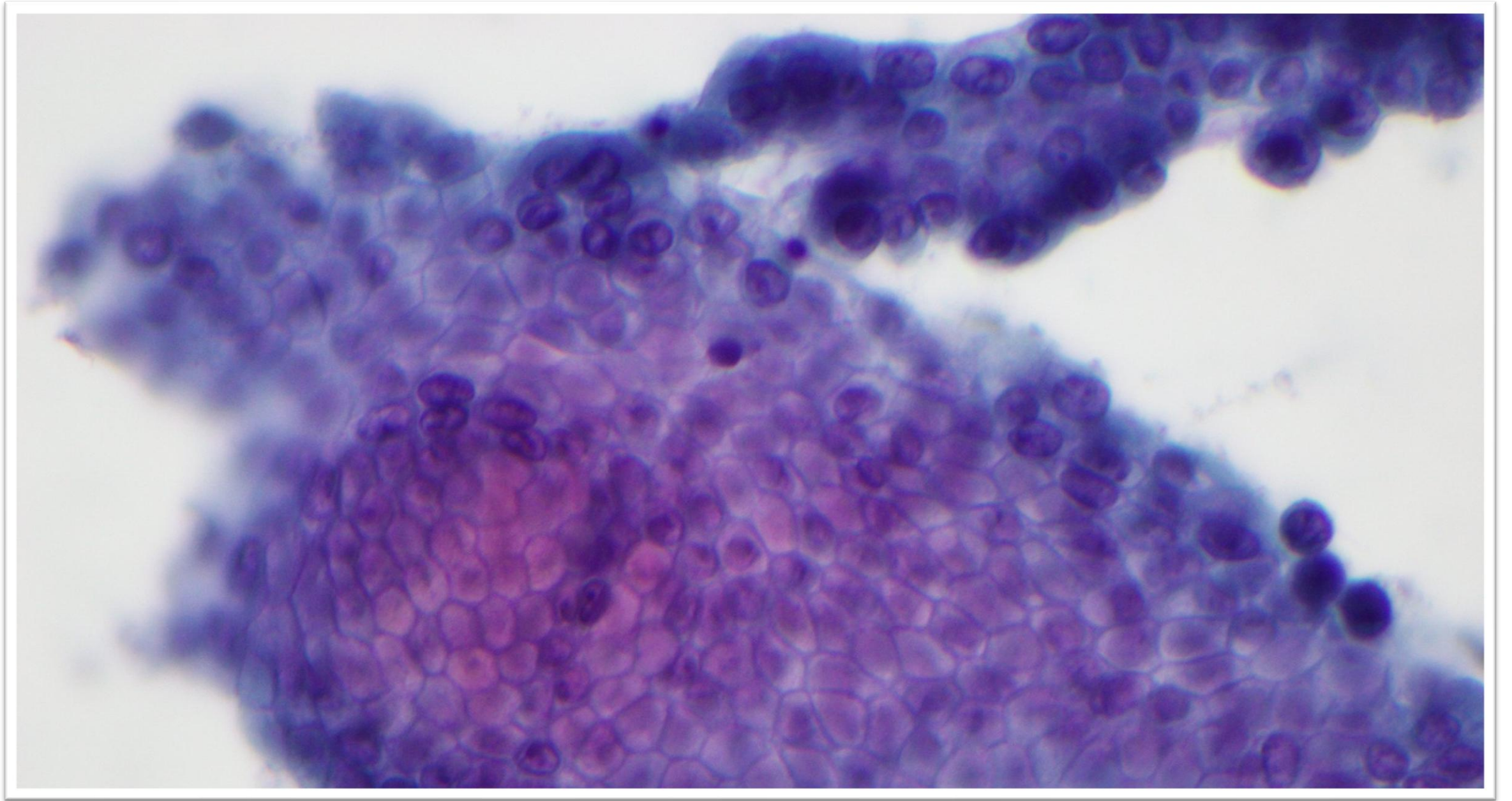


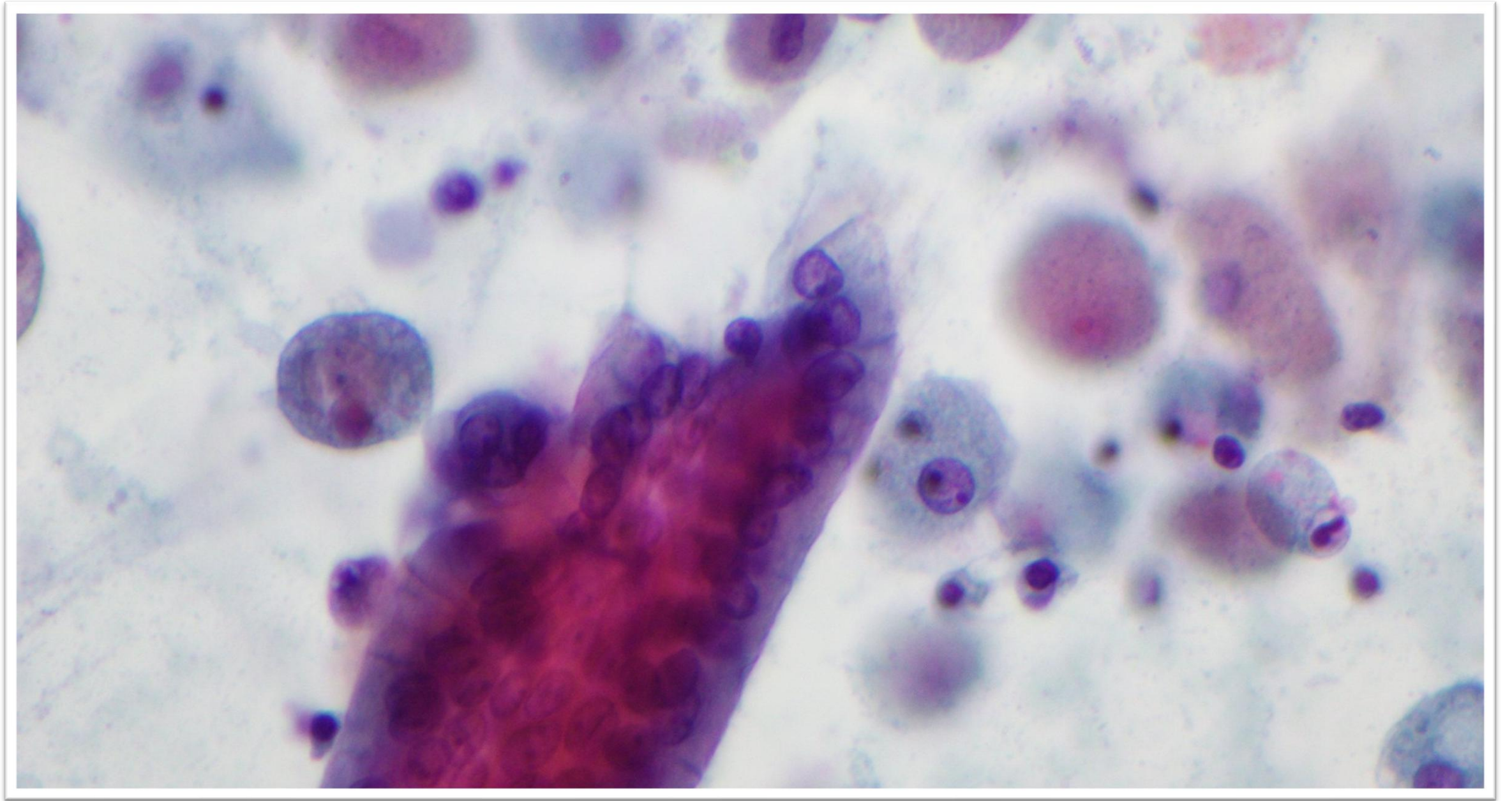


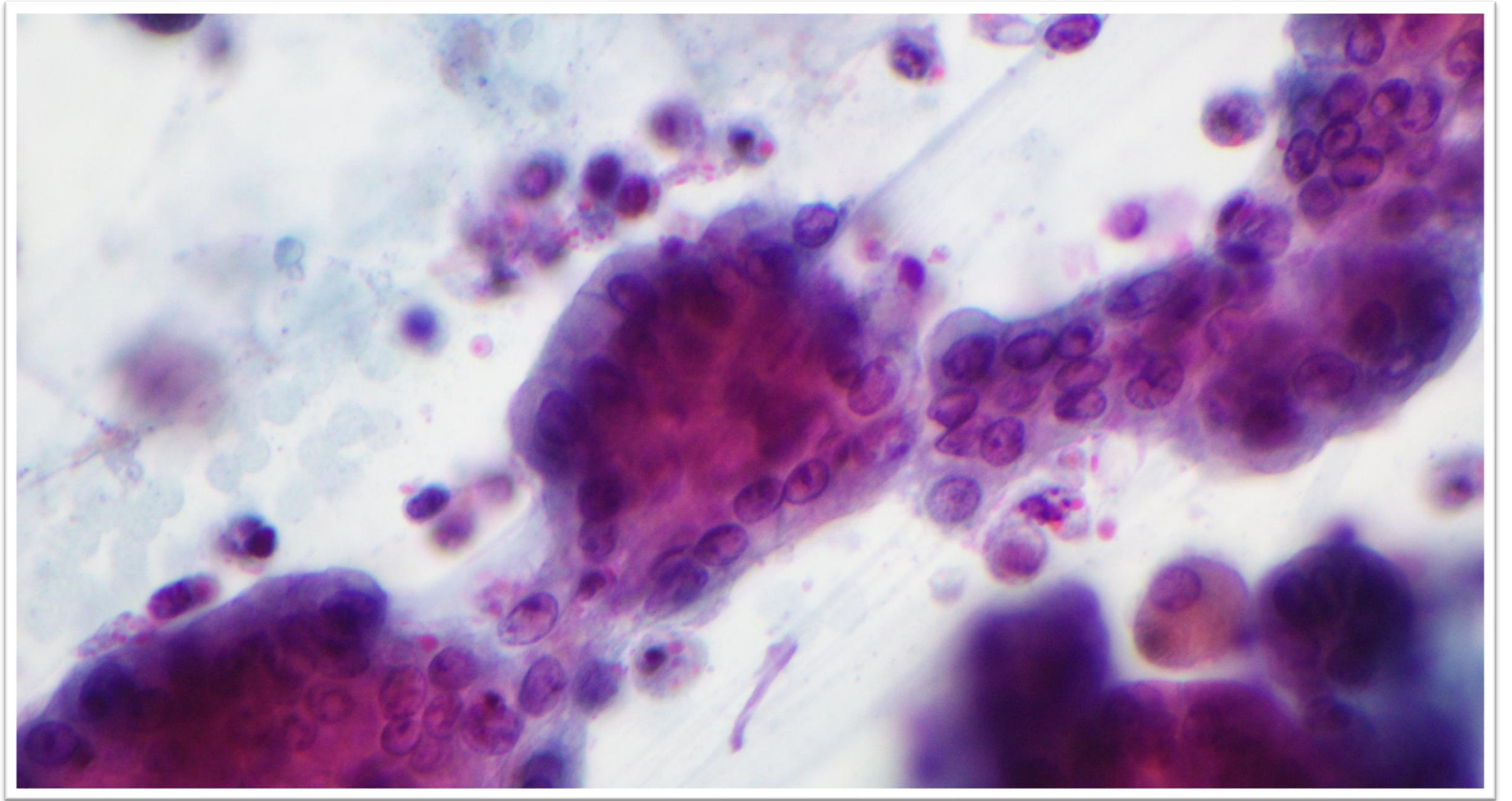


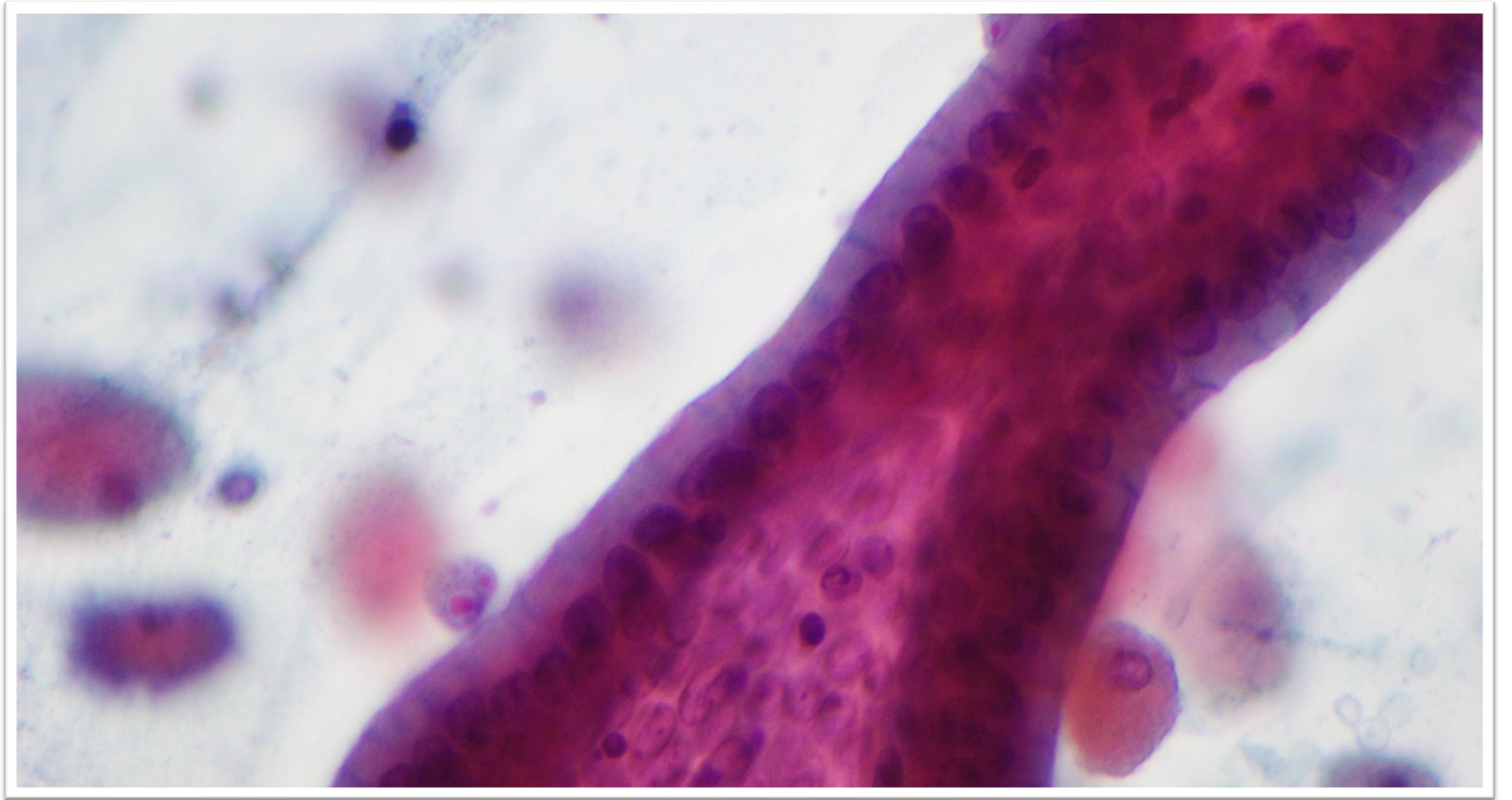






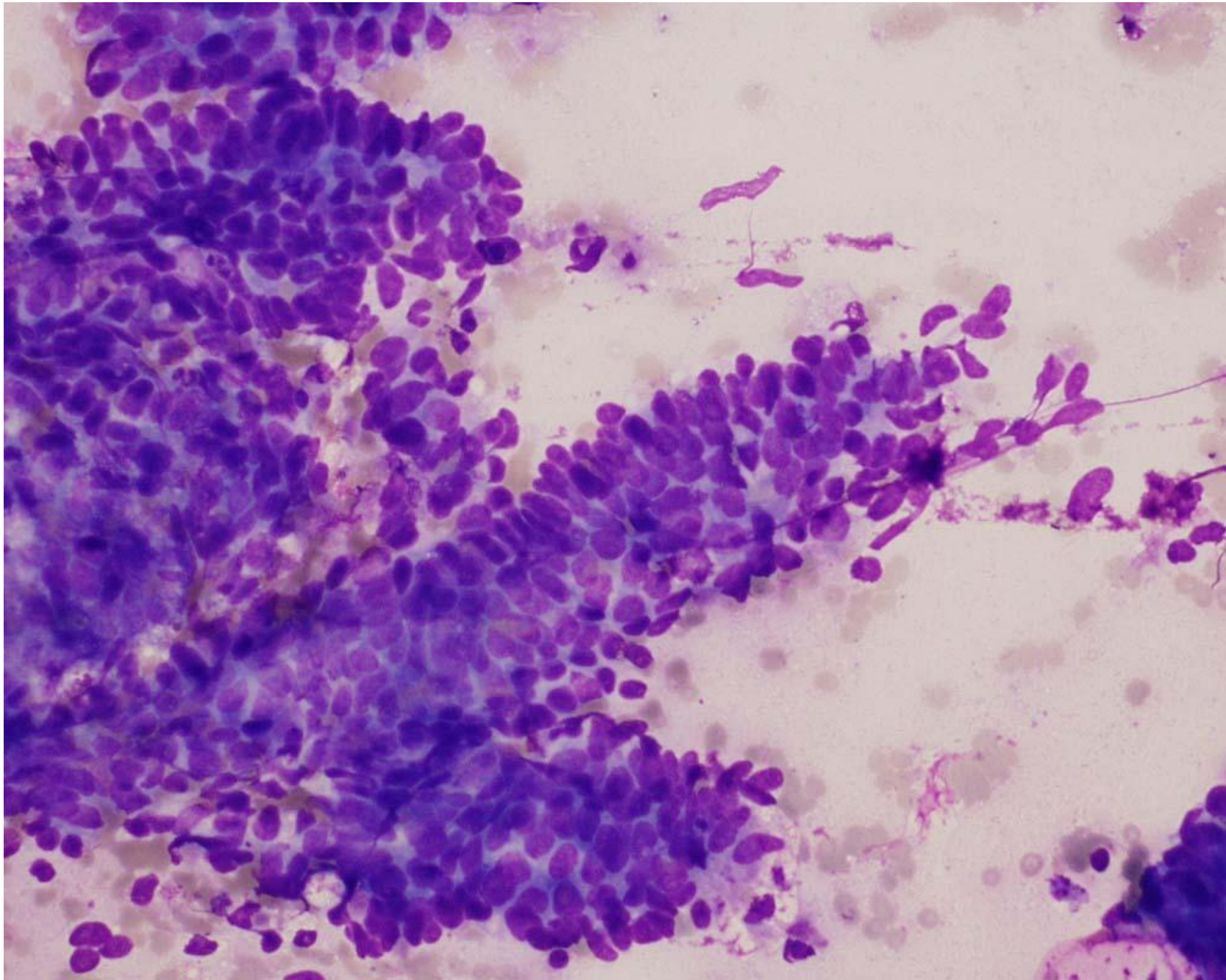


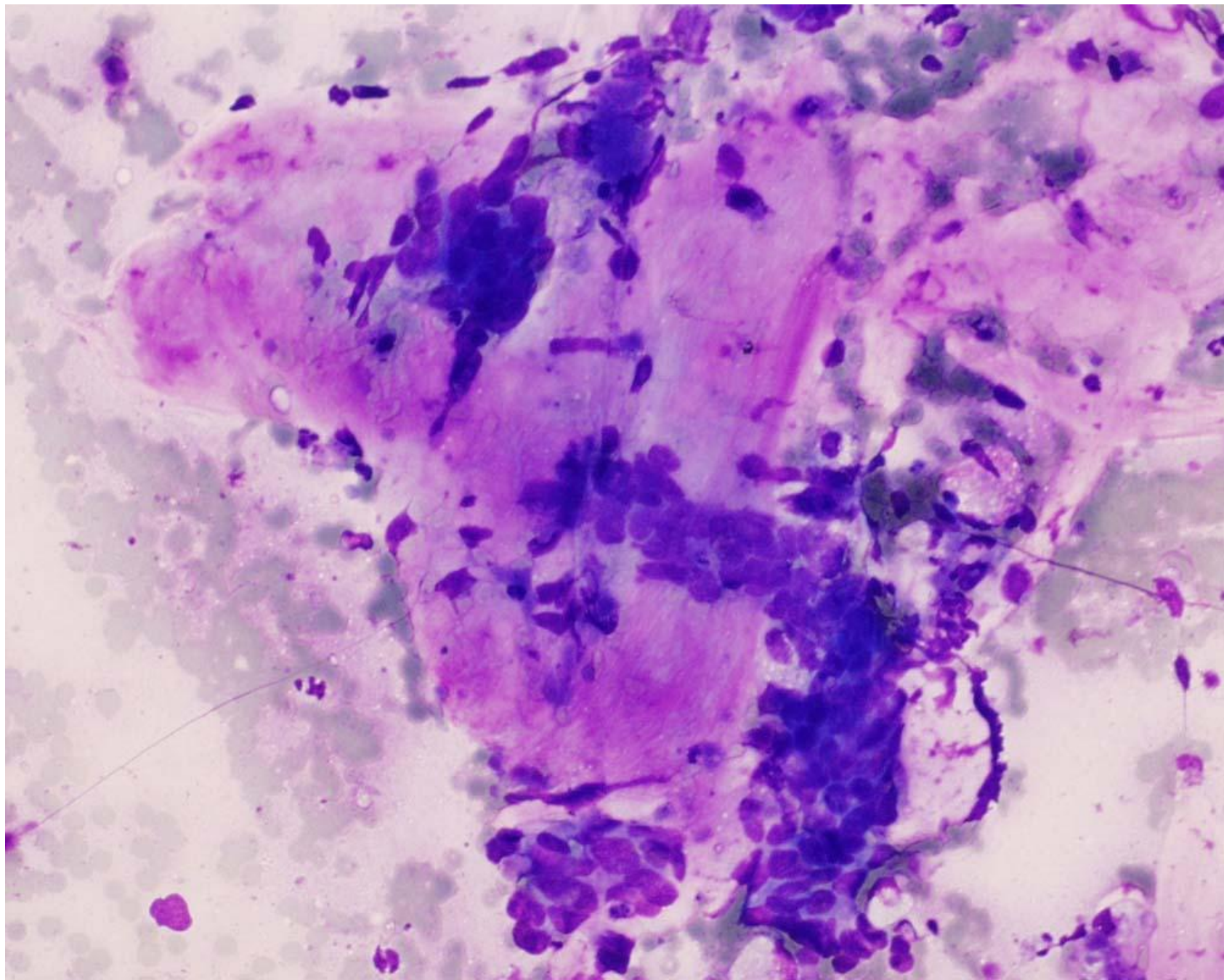


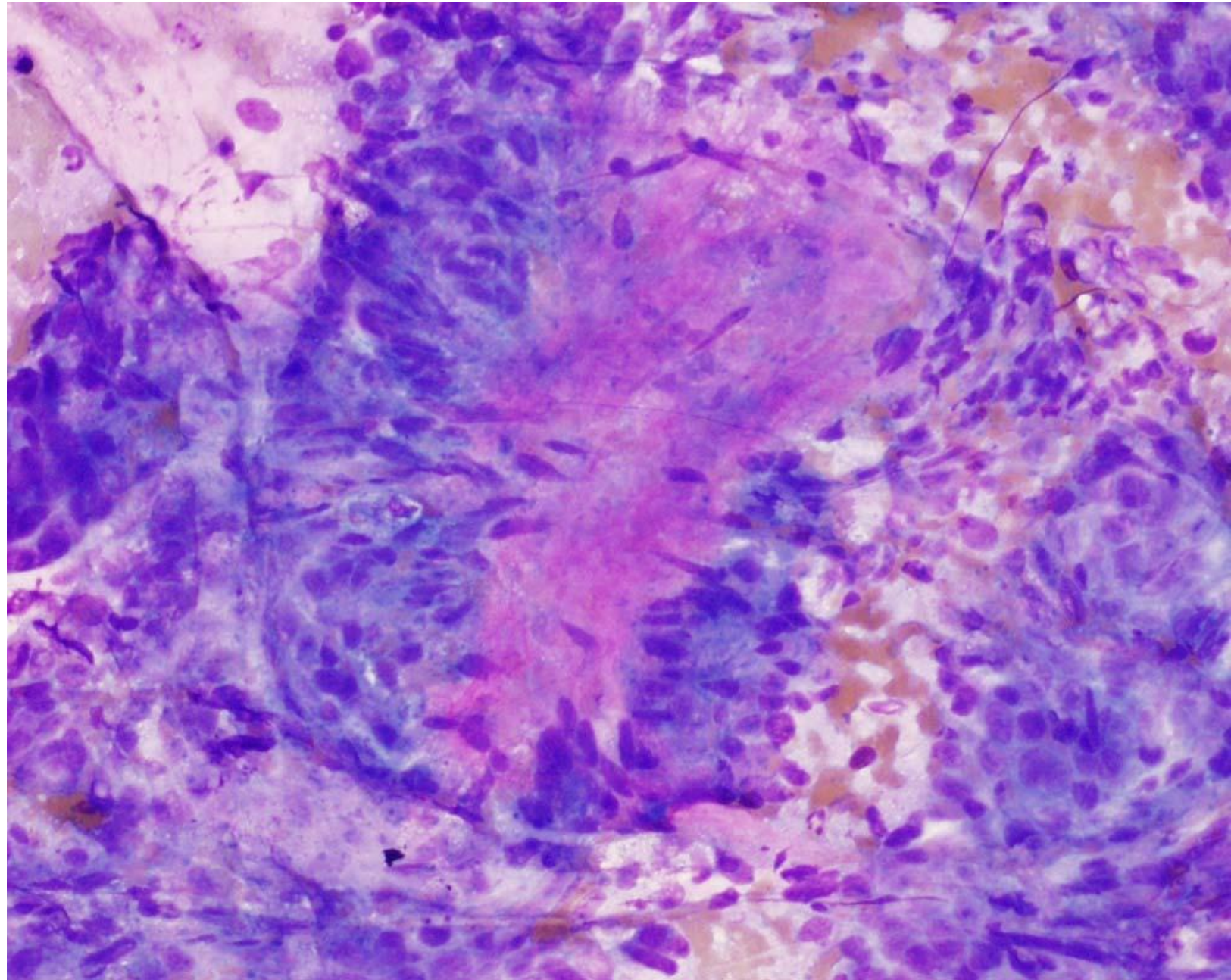


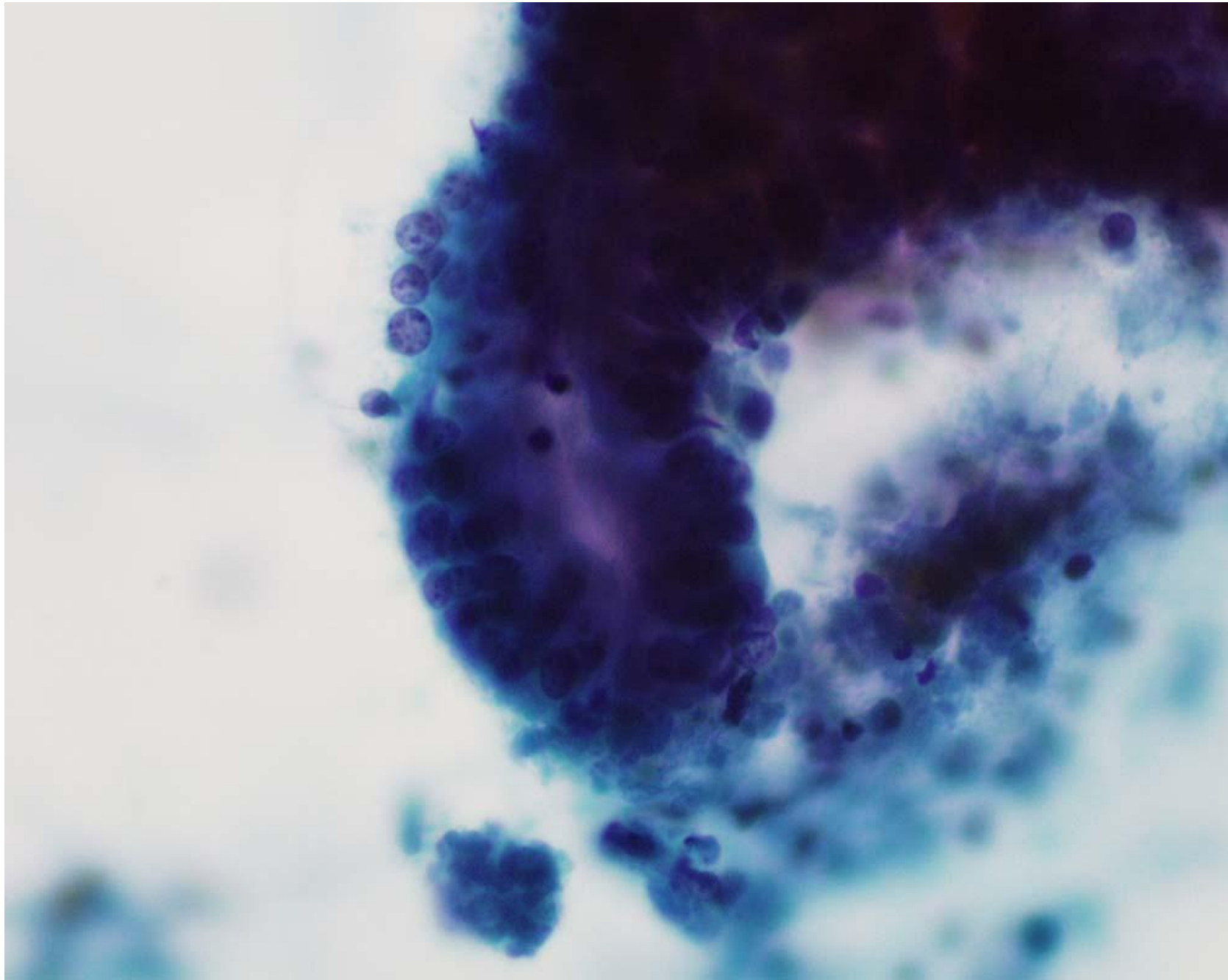
Case 32

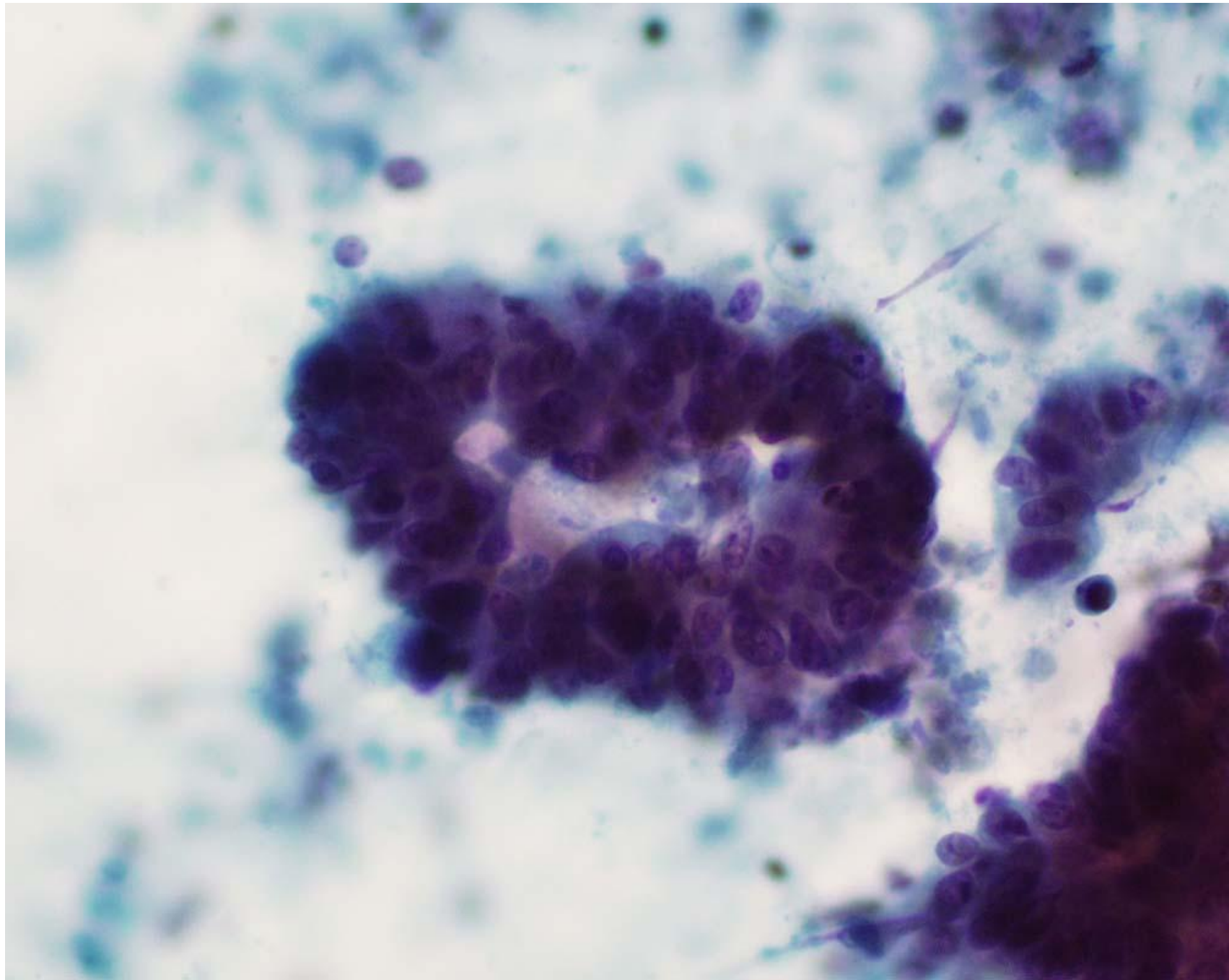
M65. FNA Liver nodule.

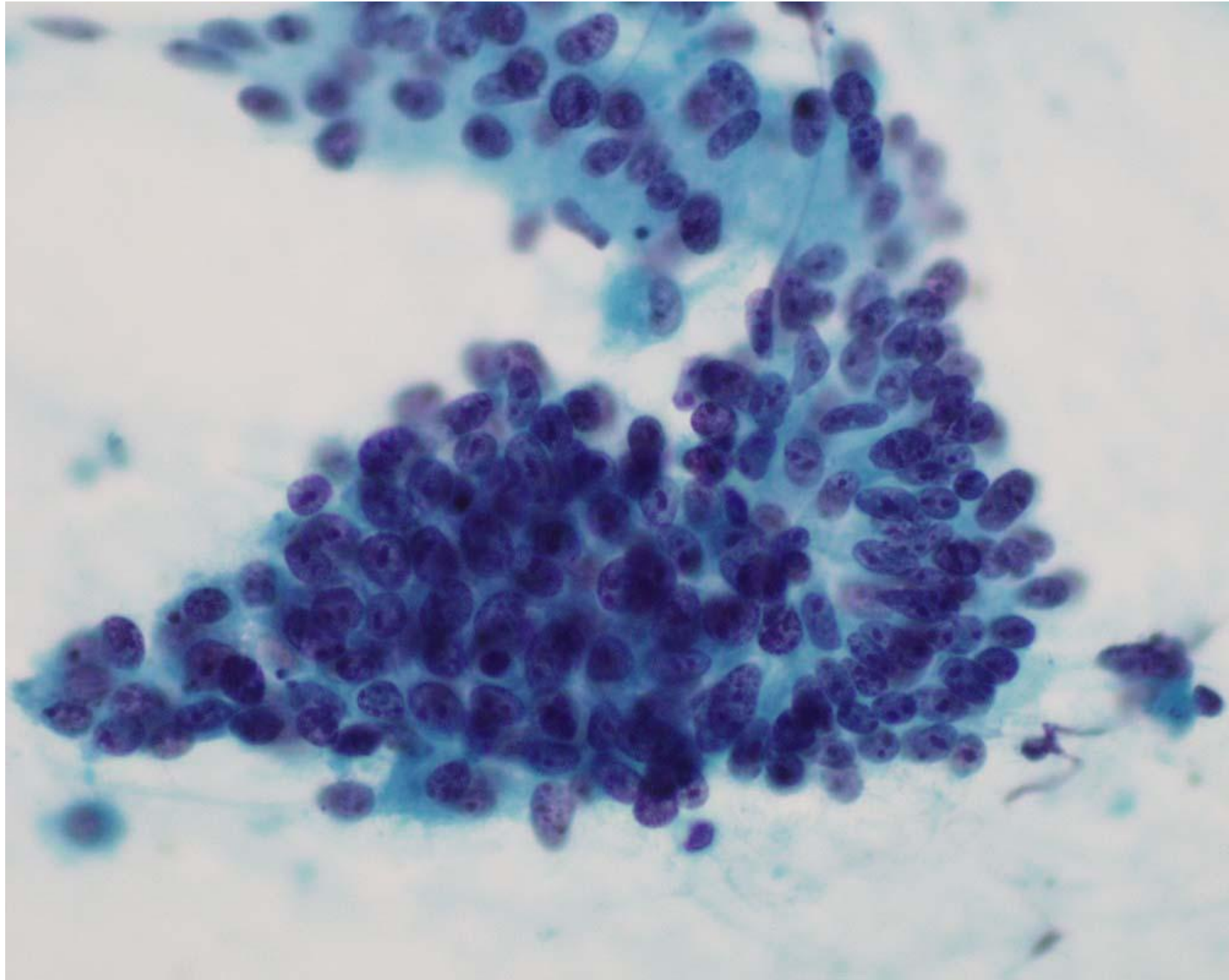






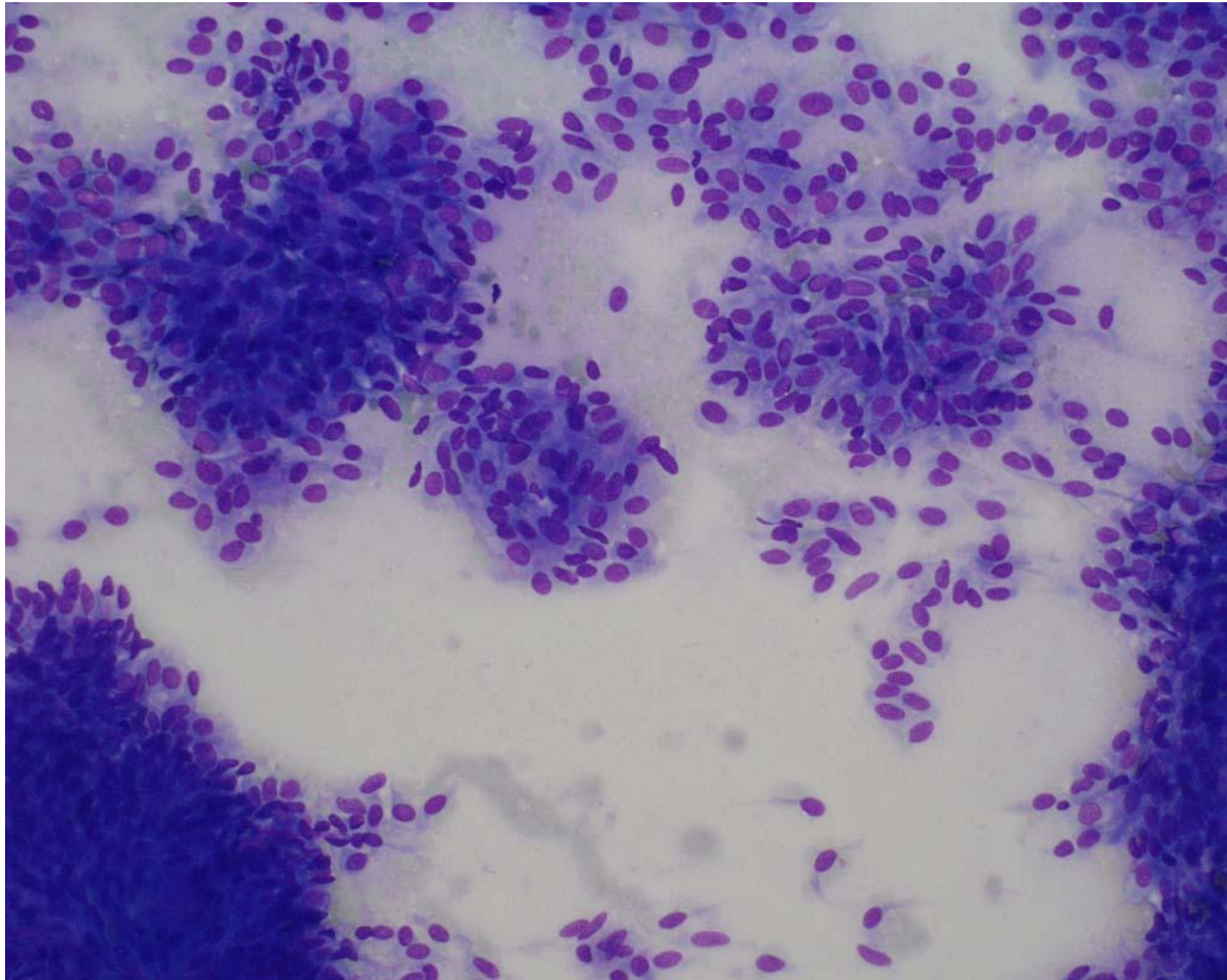


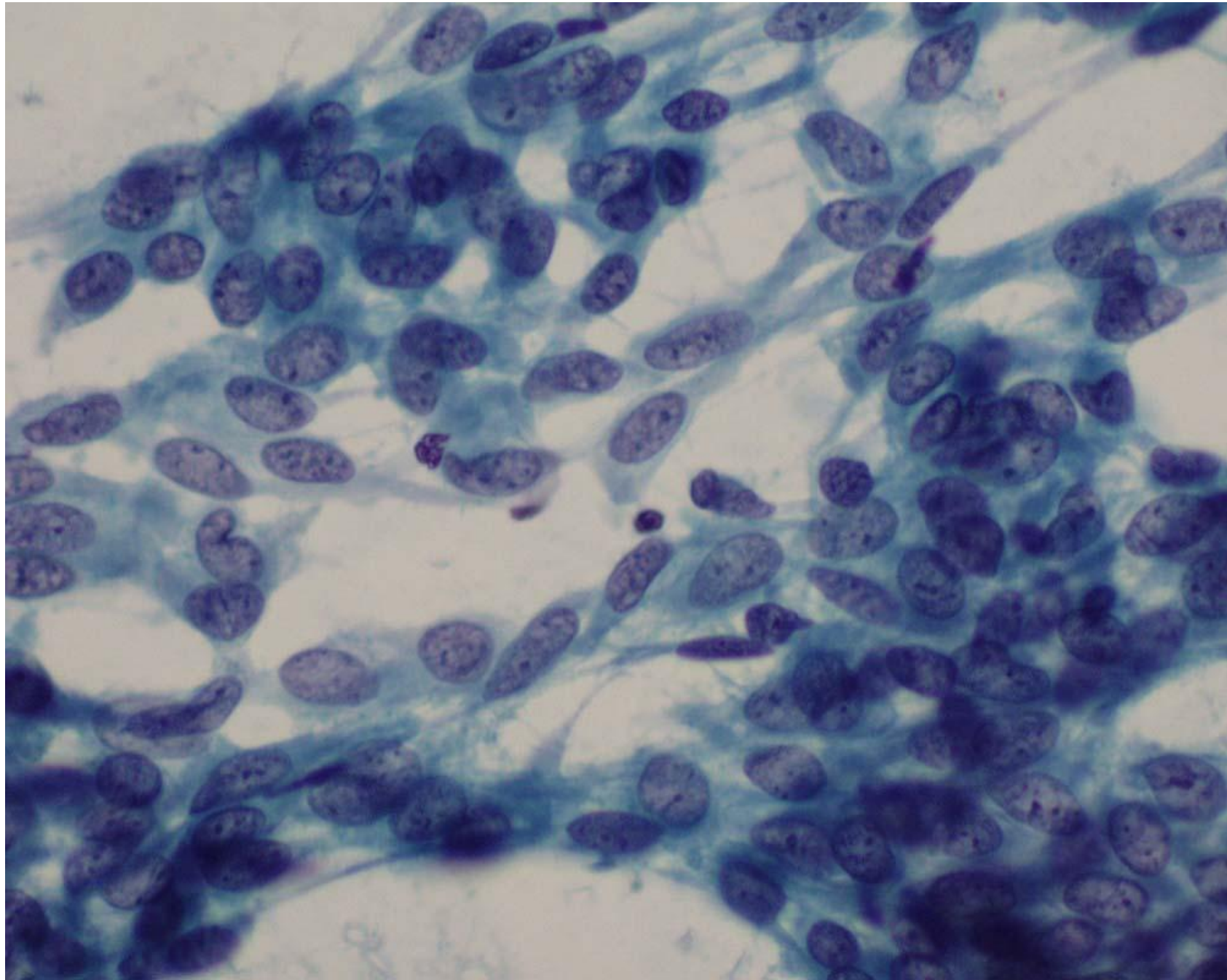


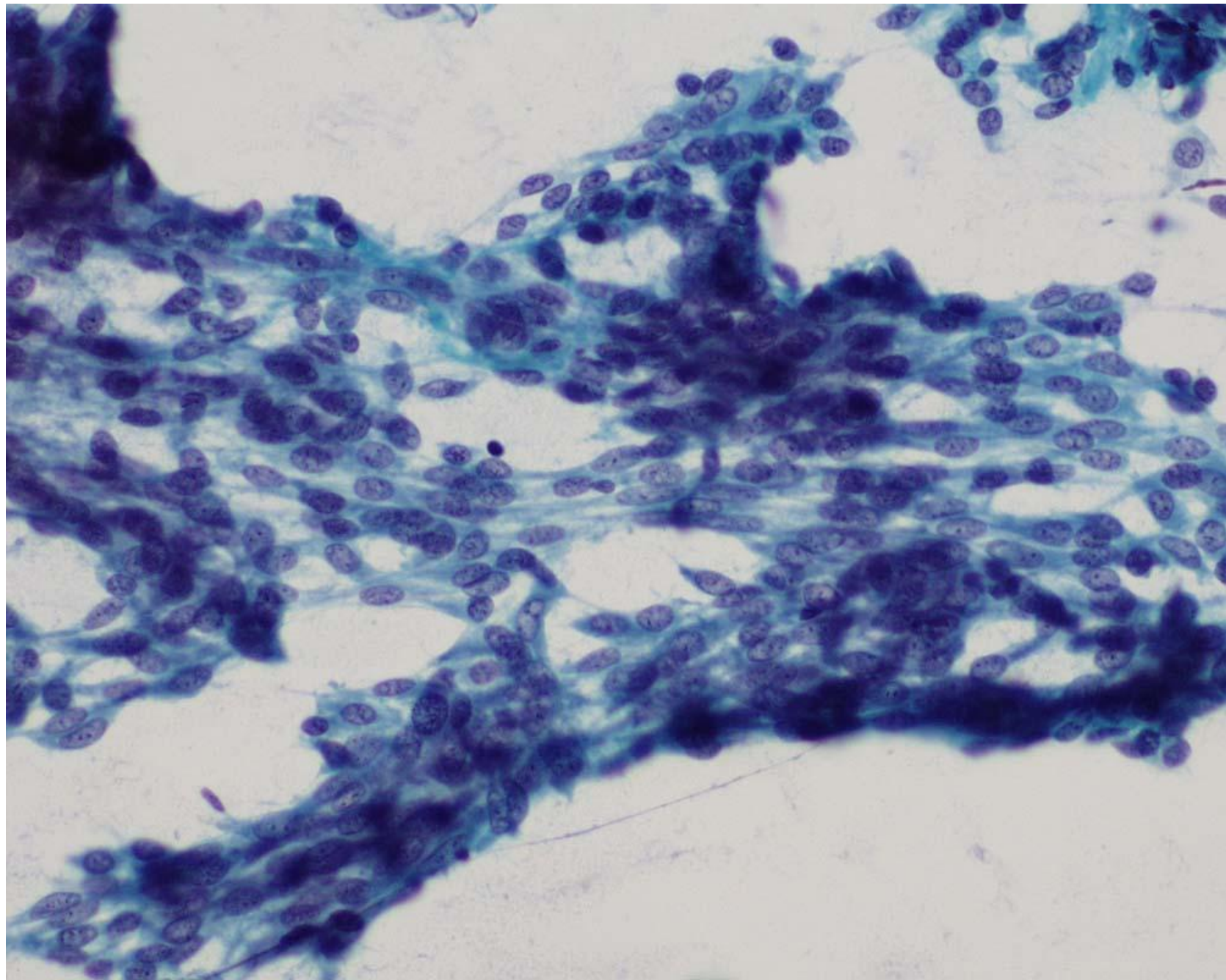


Case 33

F45. EUS FNA Nodular lesion in gastric wall

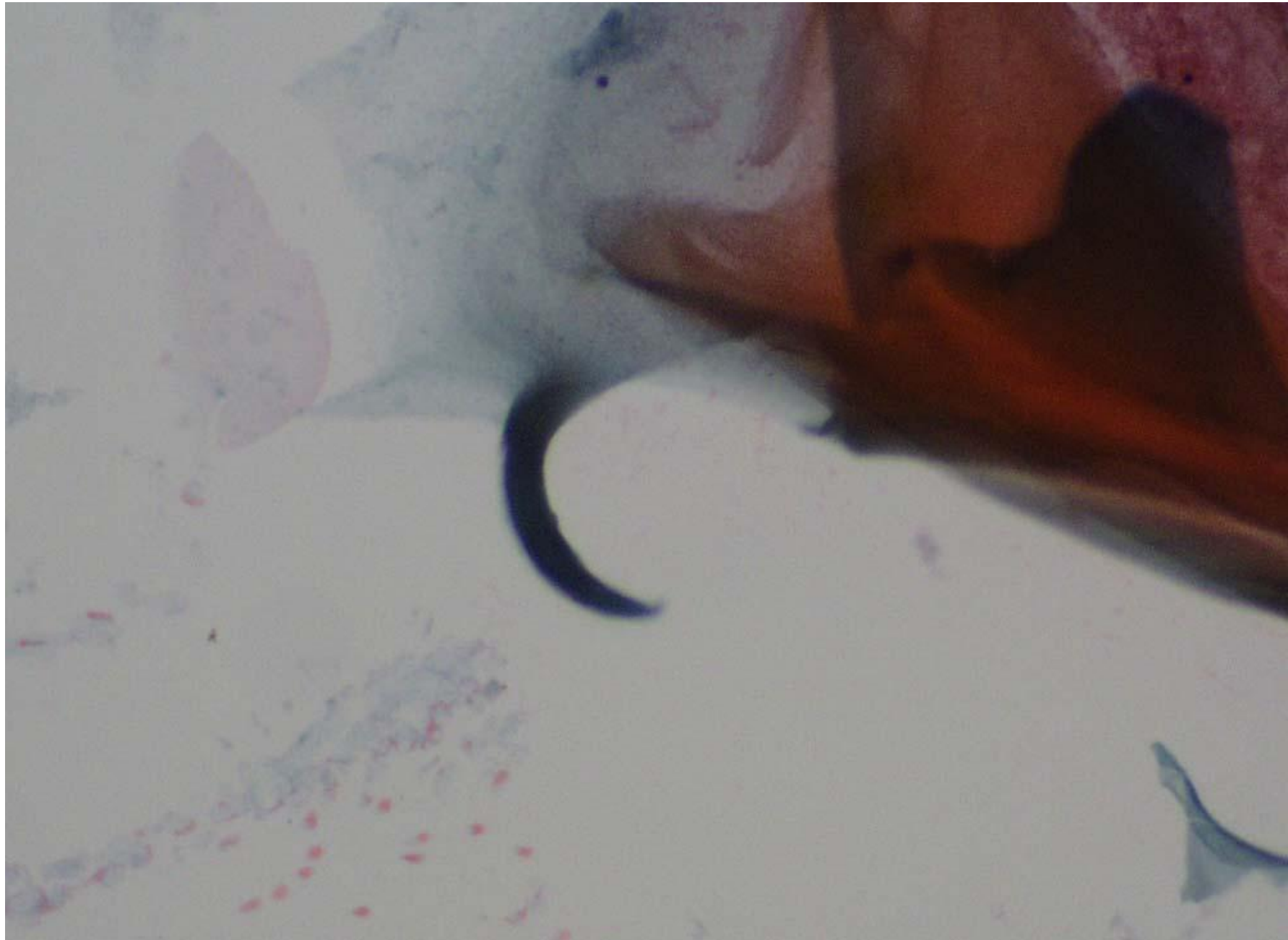


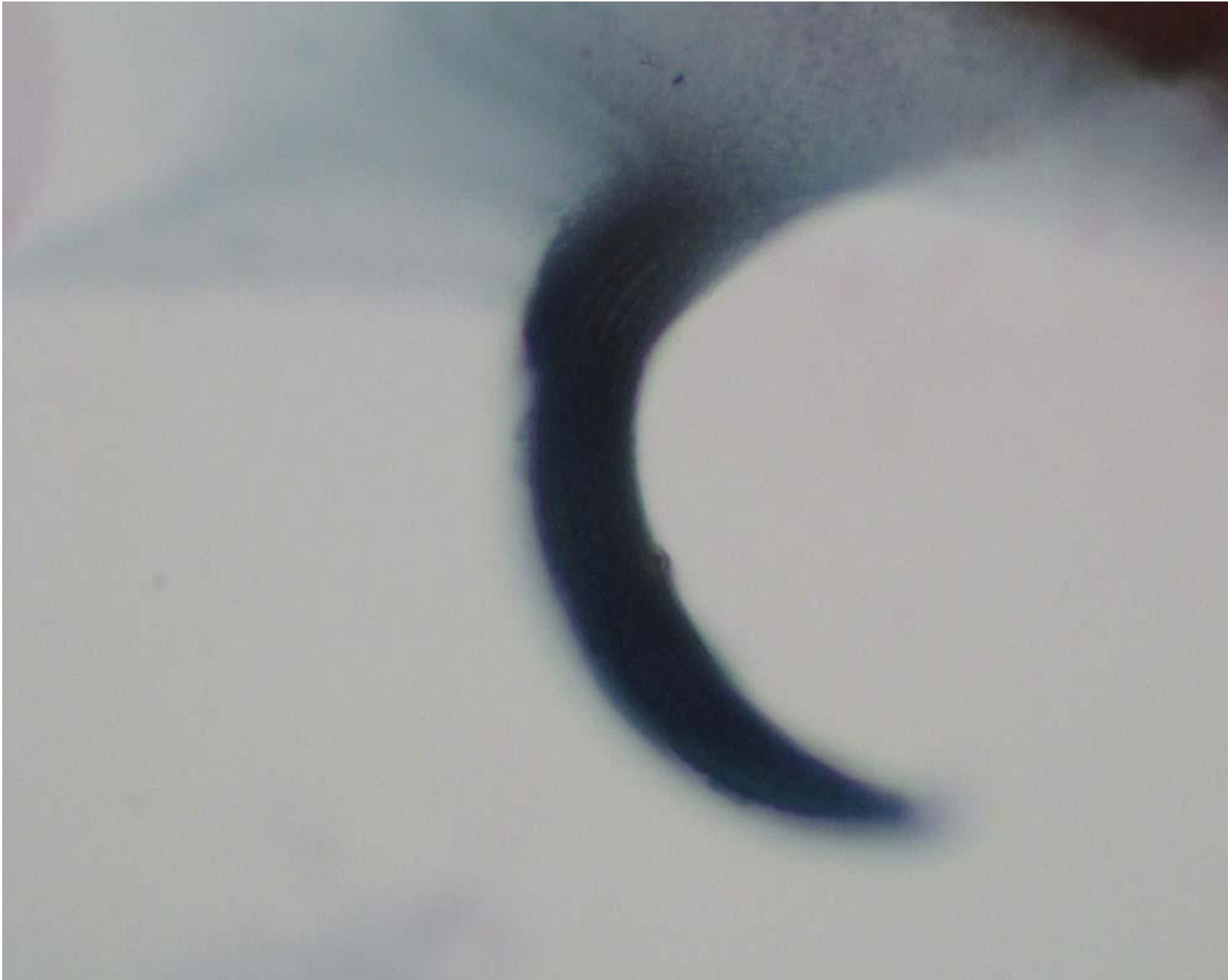

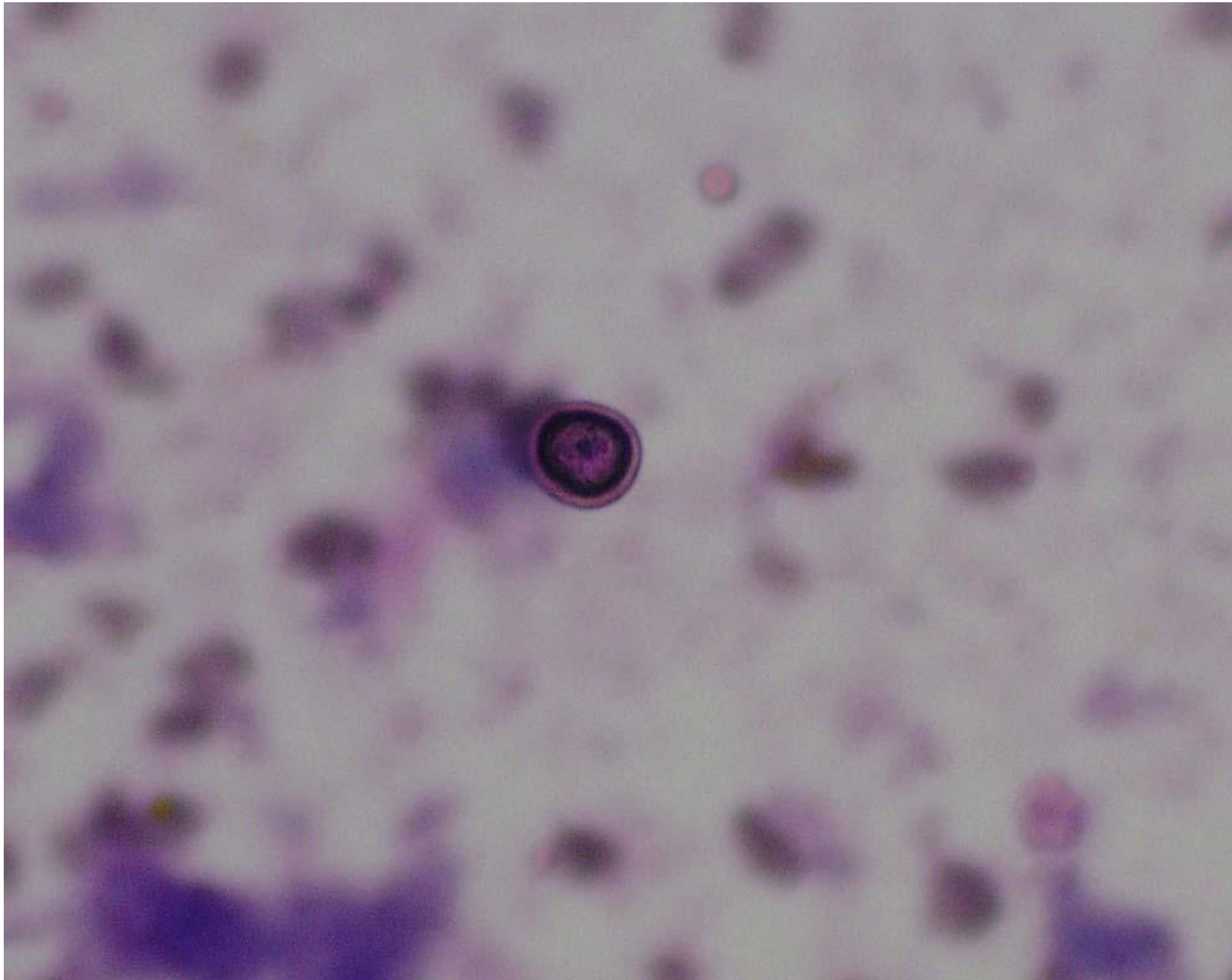


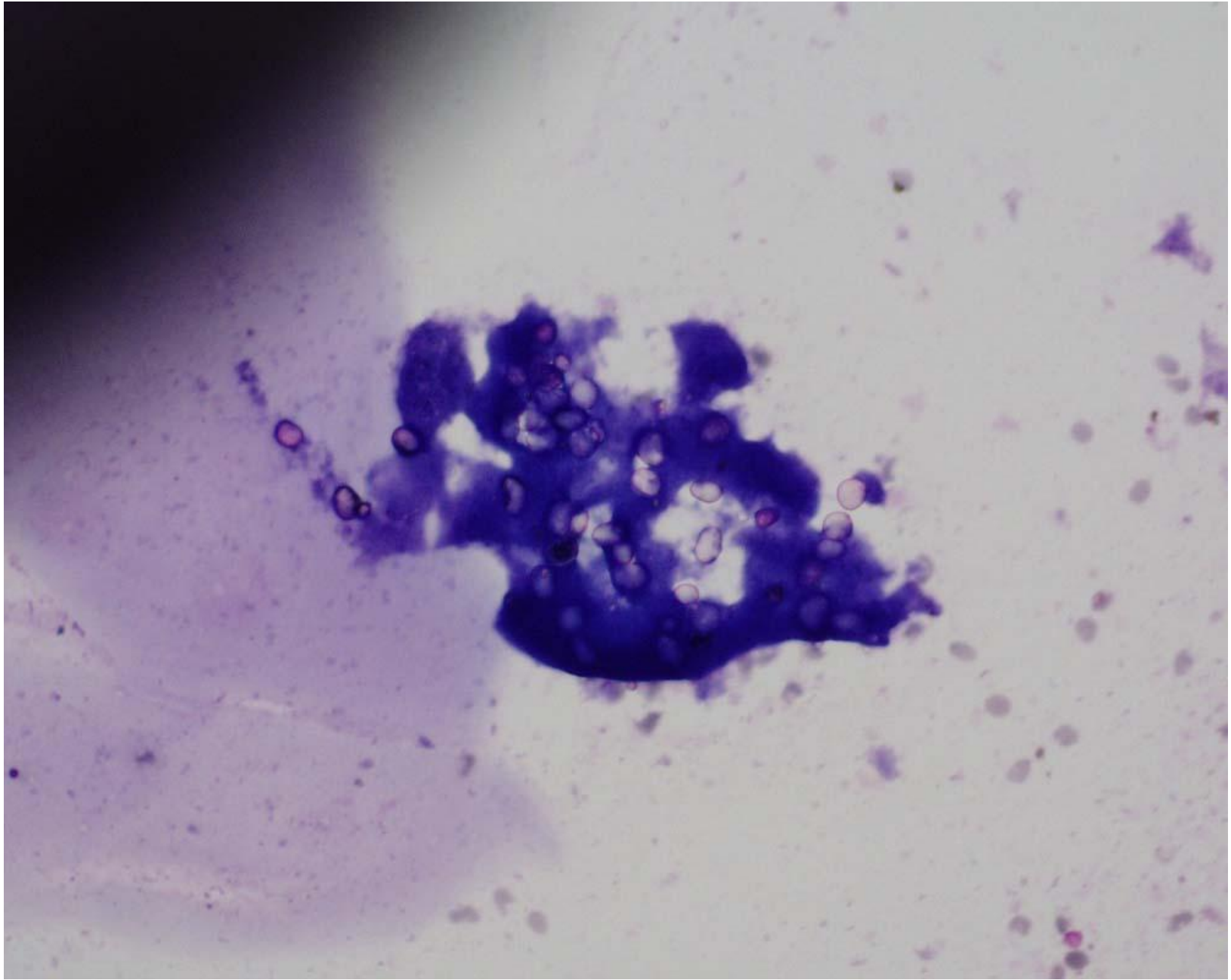
Case 34

M50. FNA Liver cyst



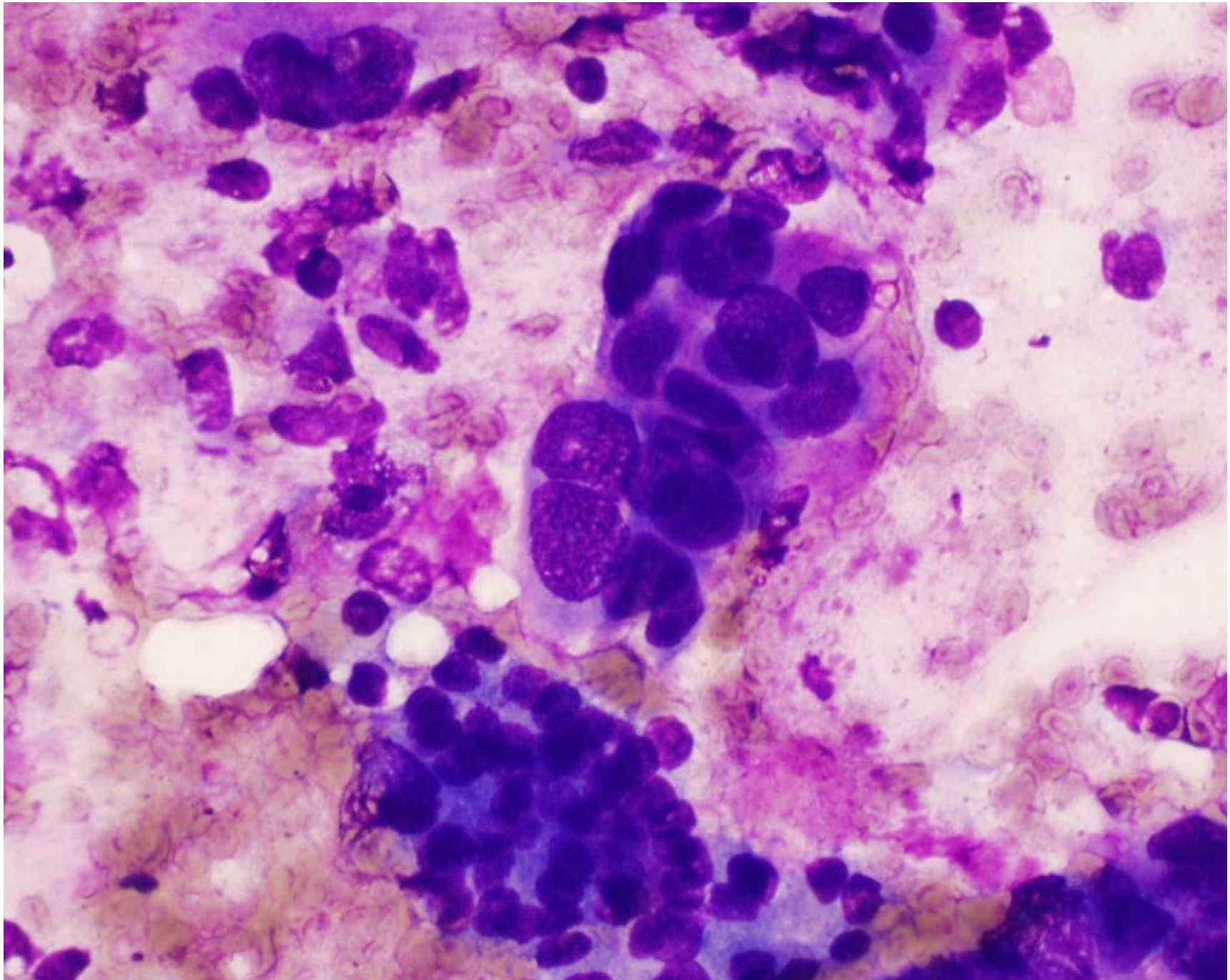


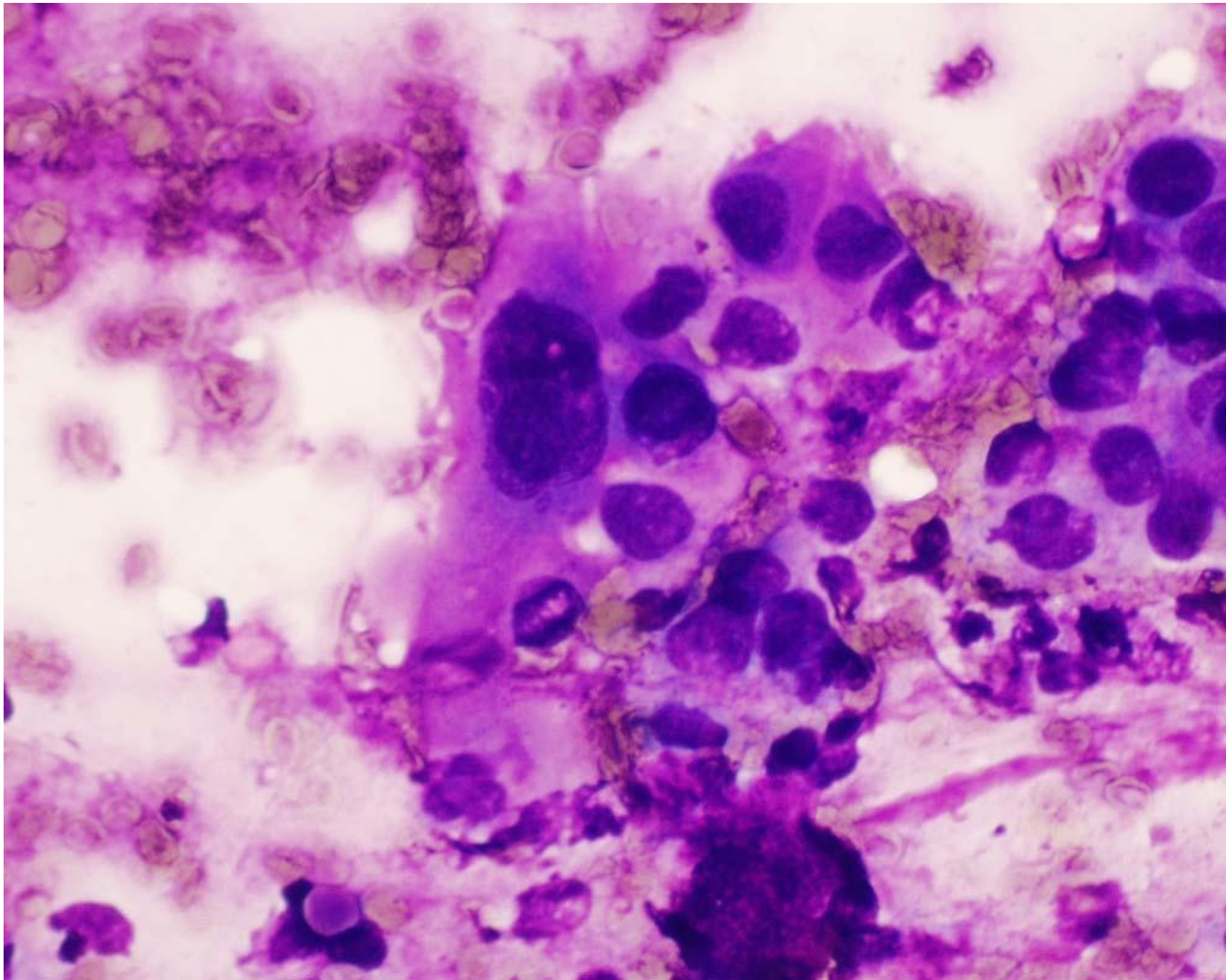


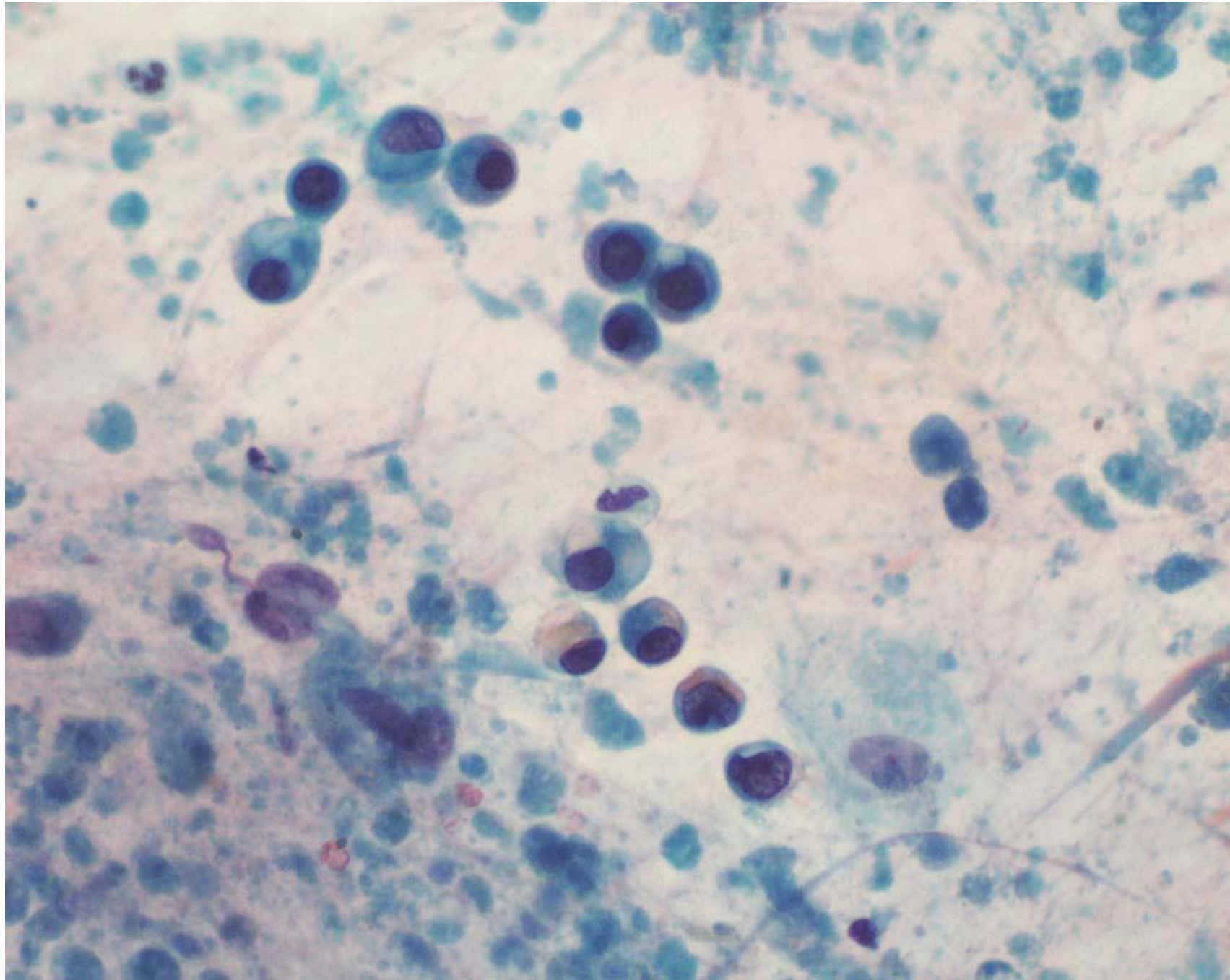


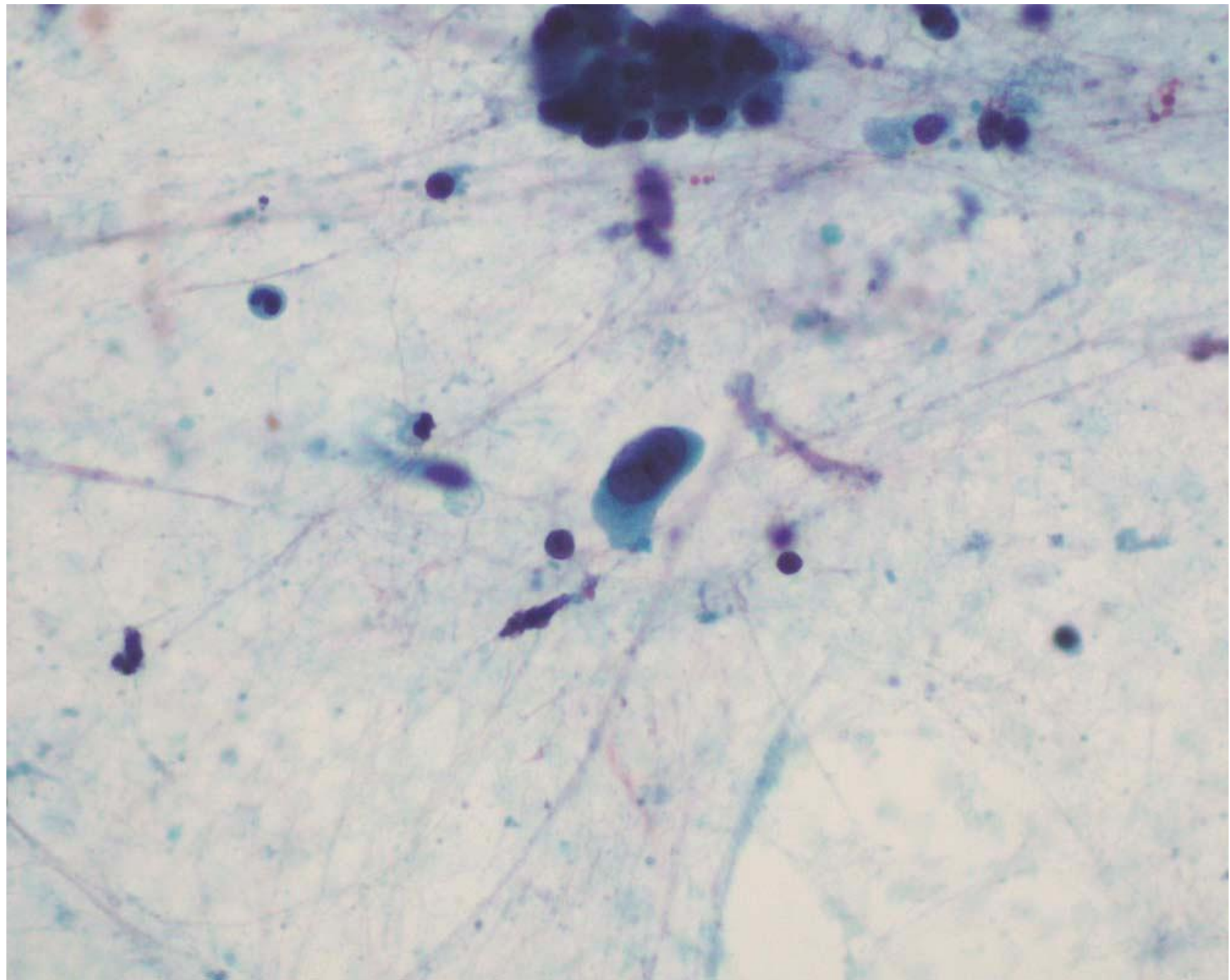
Case 35

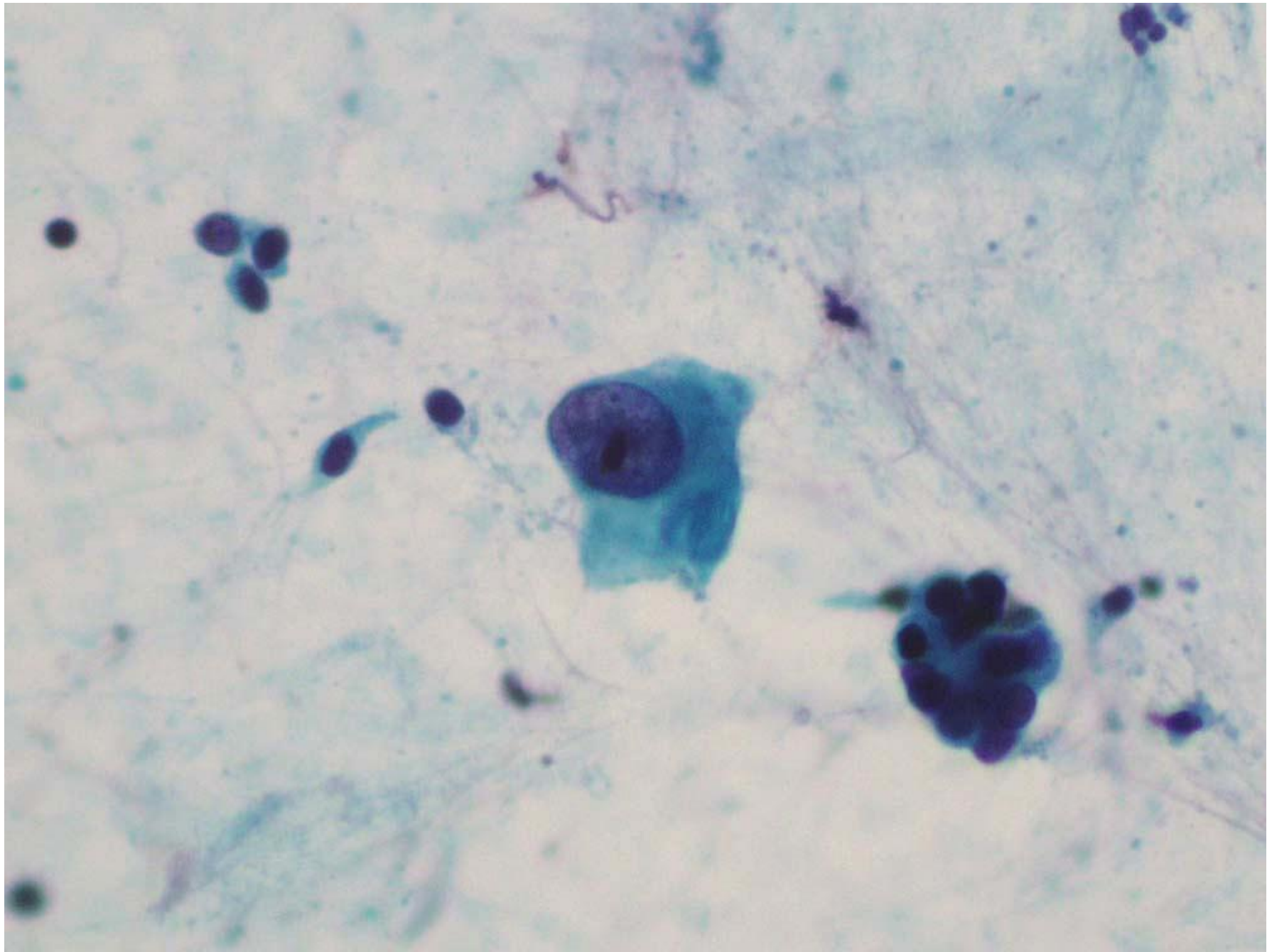
M72. FNA Pancreas





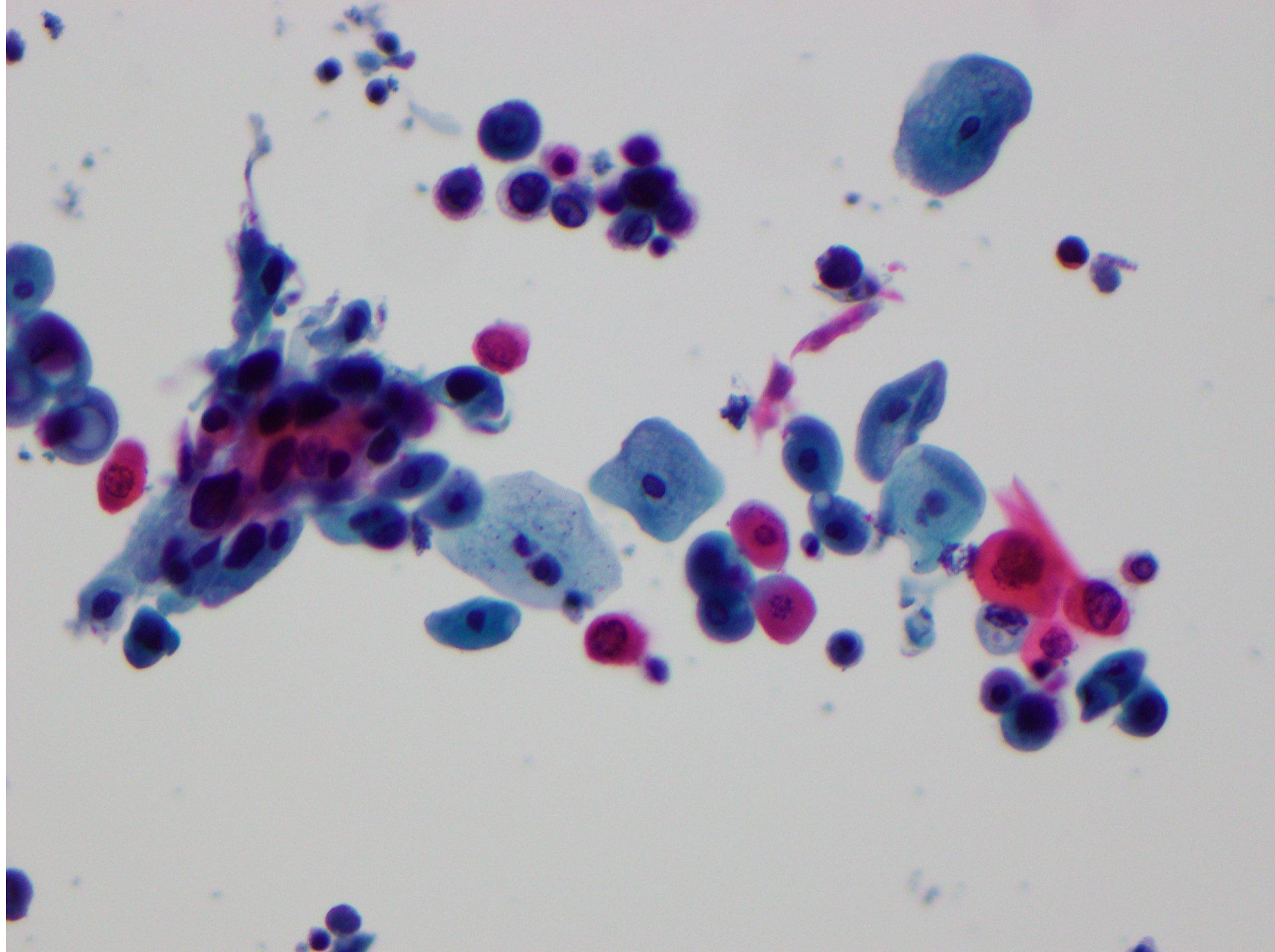


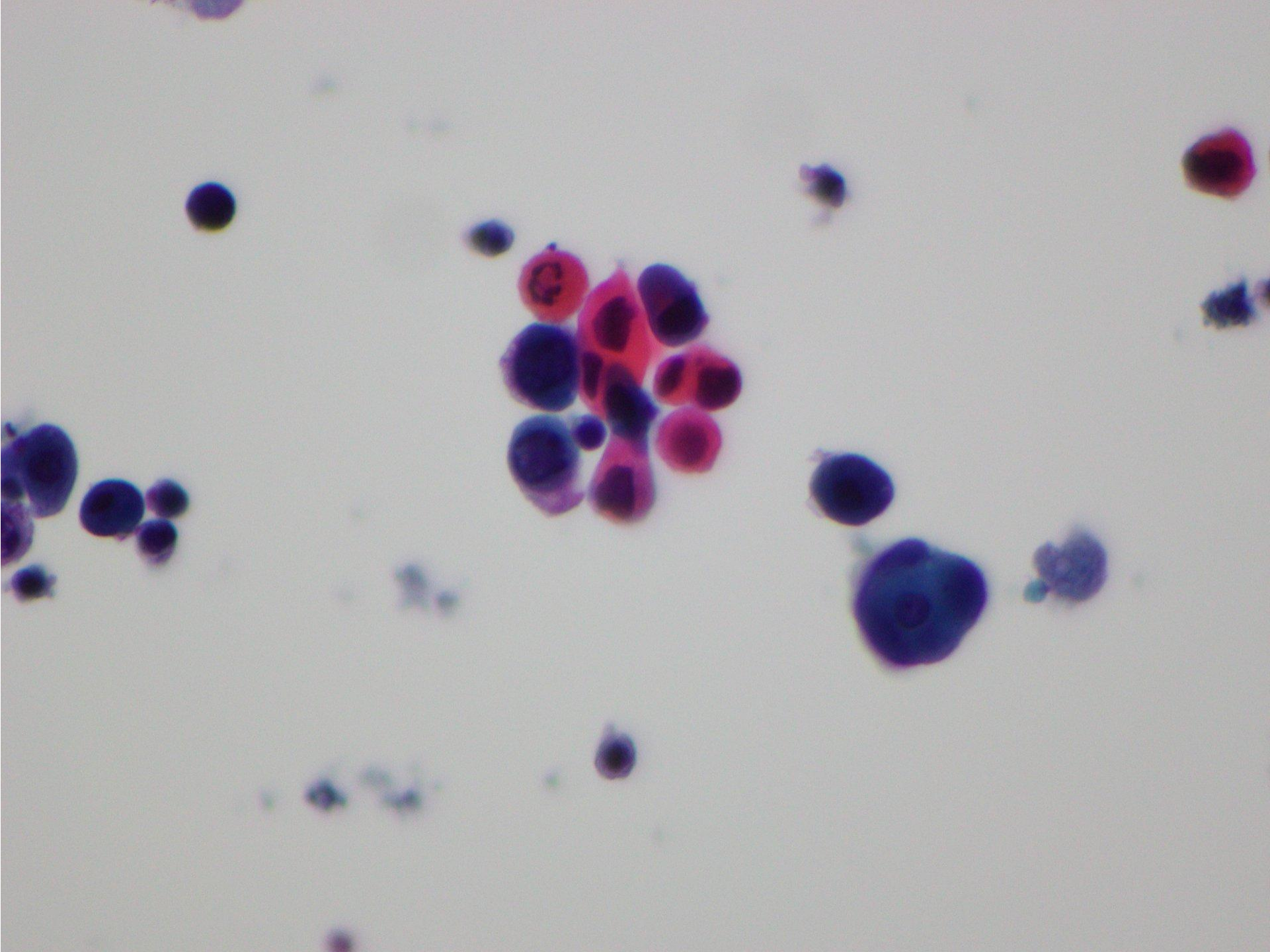


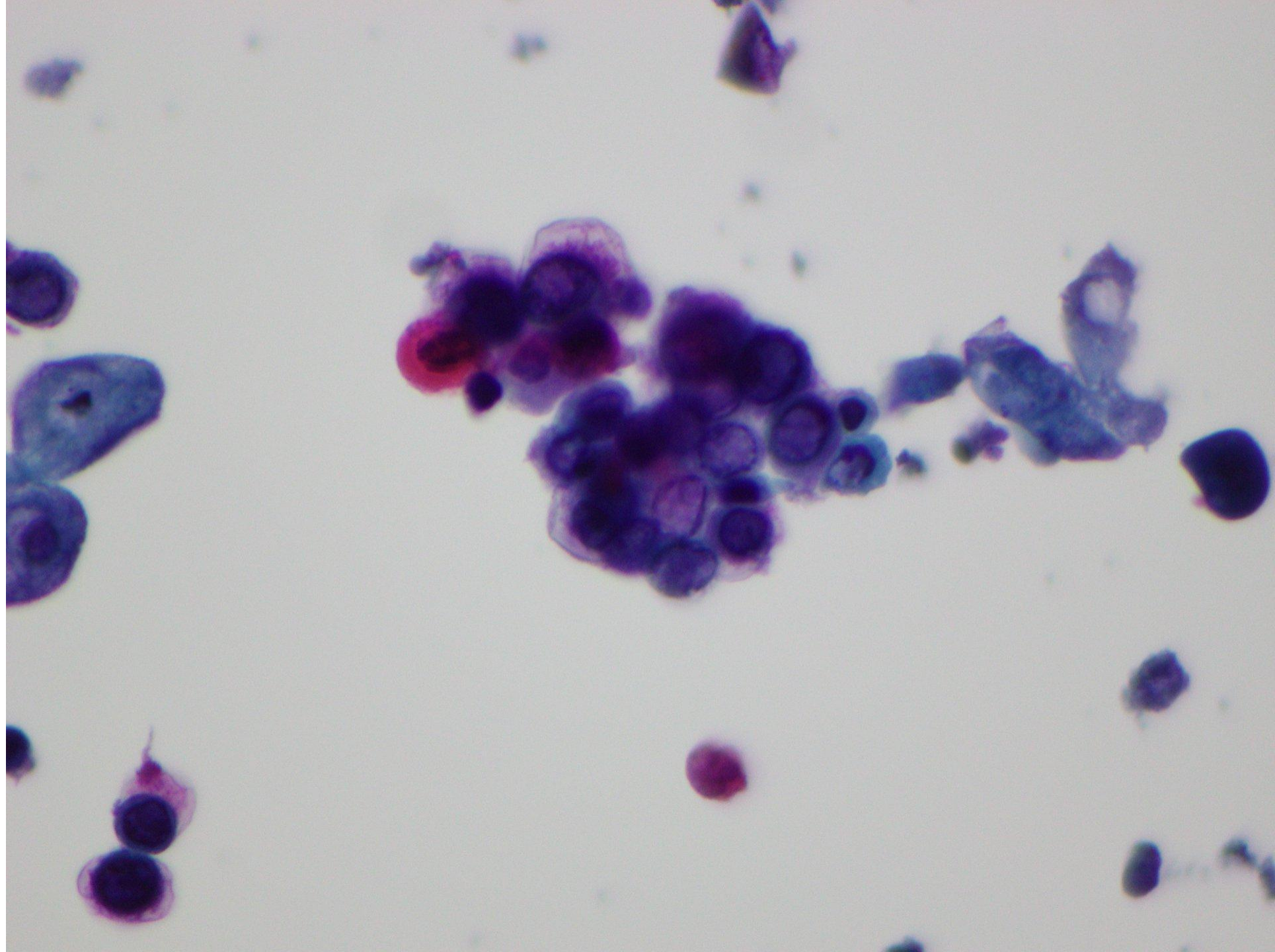


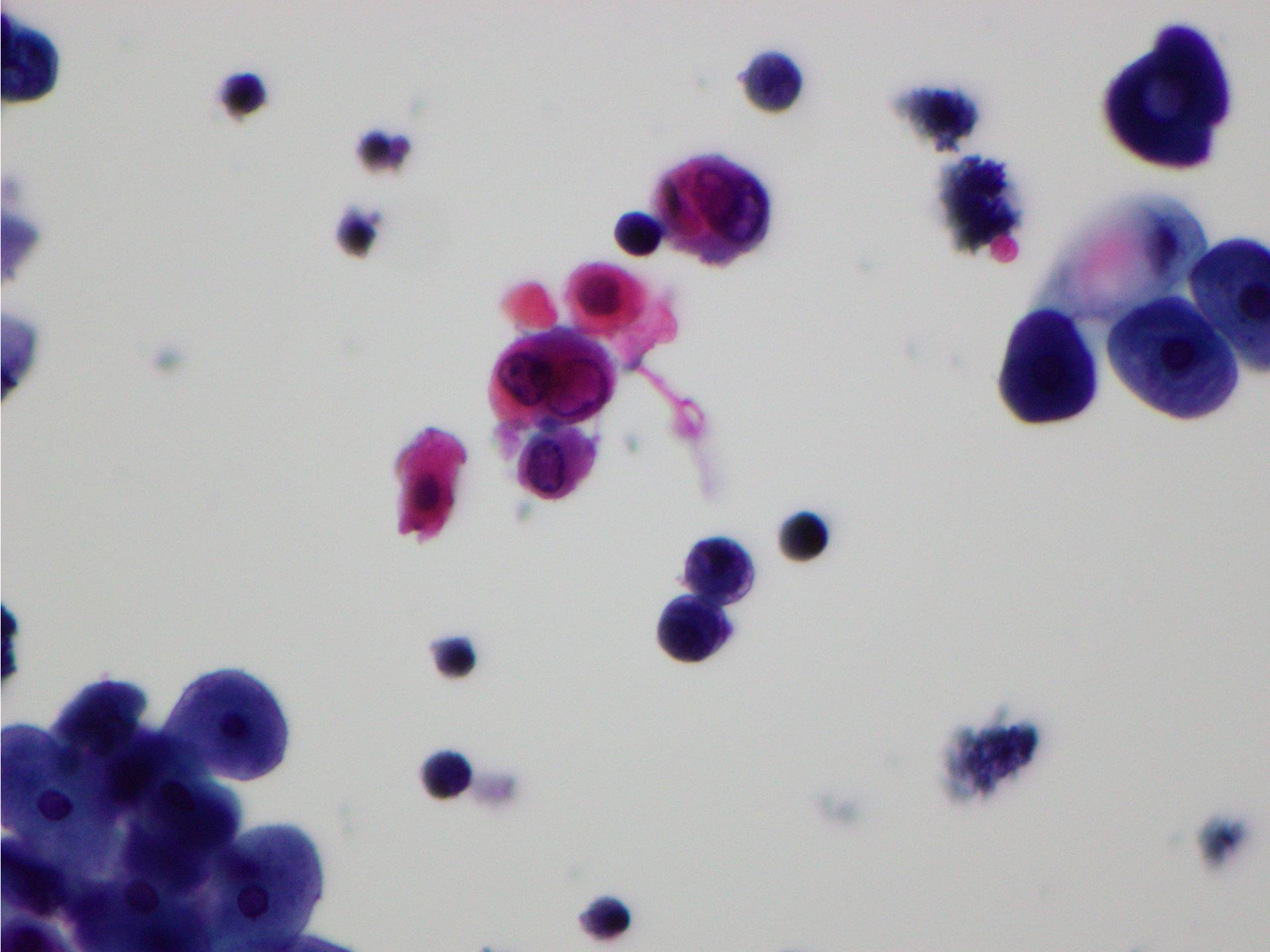
Case 36

M80. Haematuria. Urine.



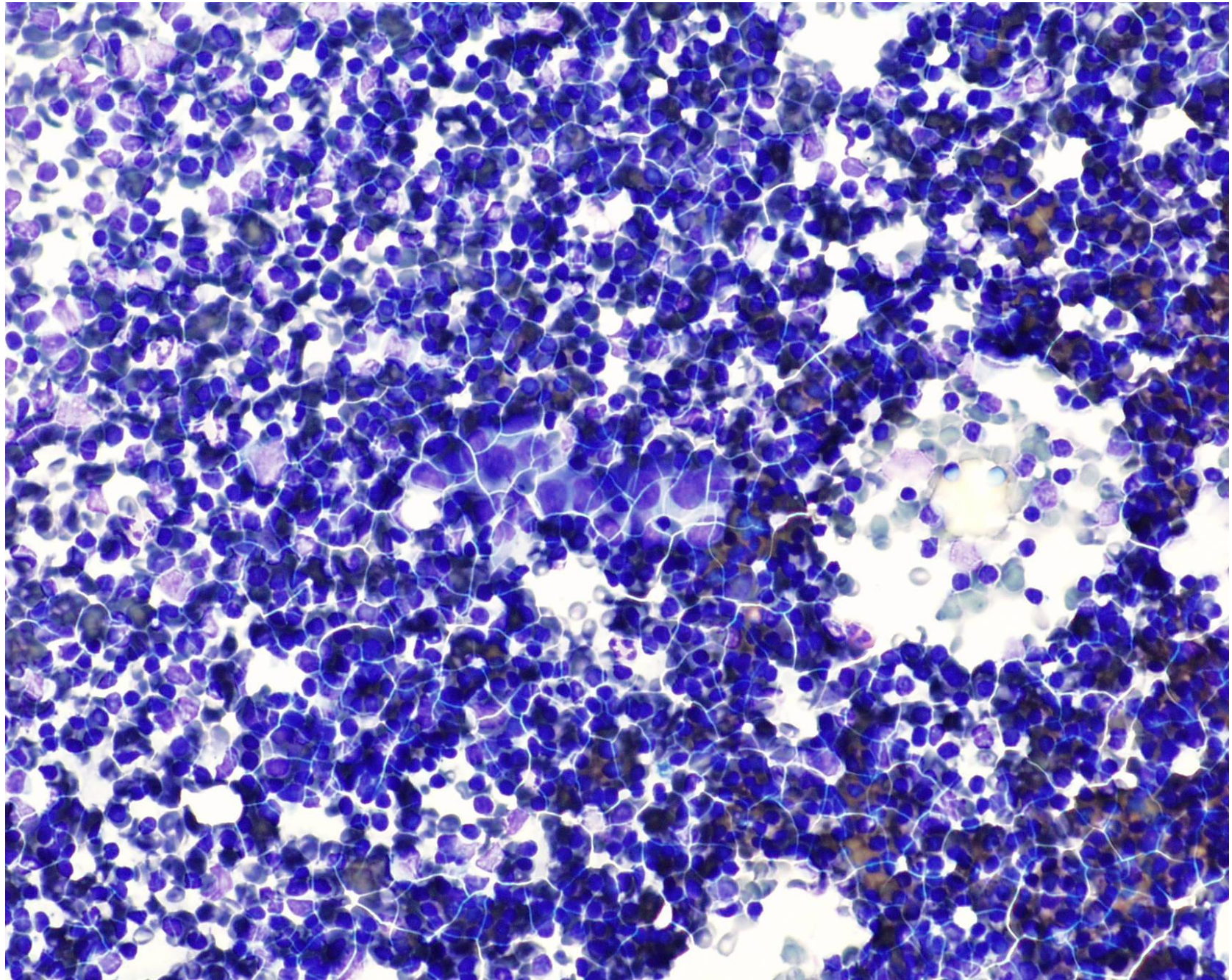


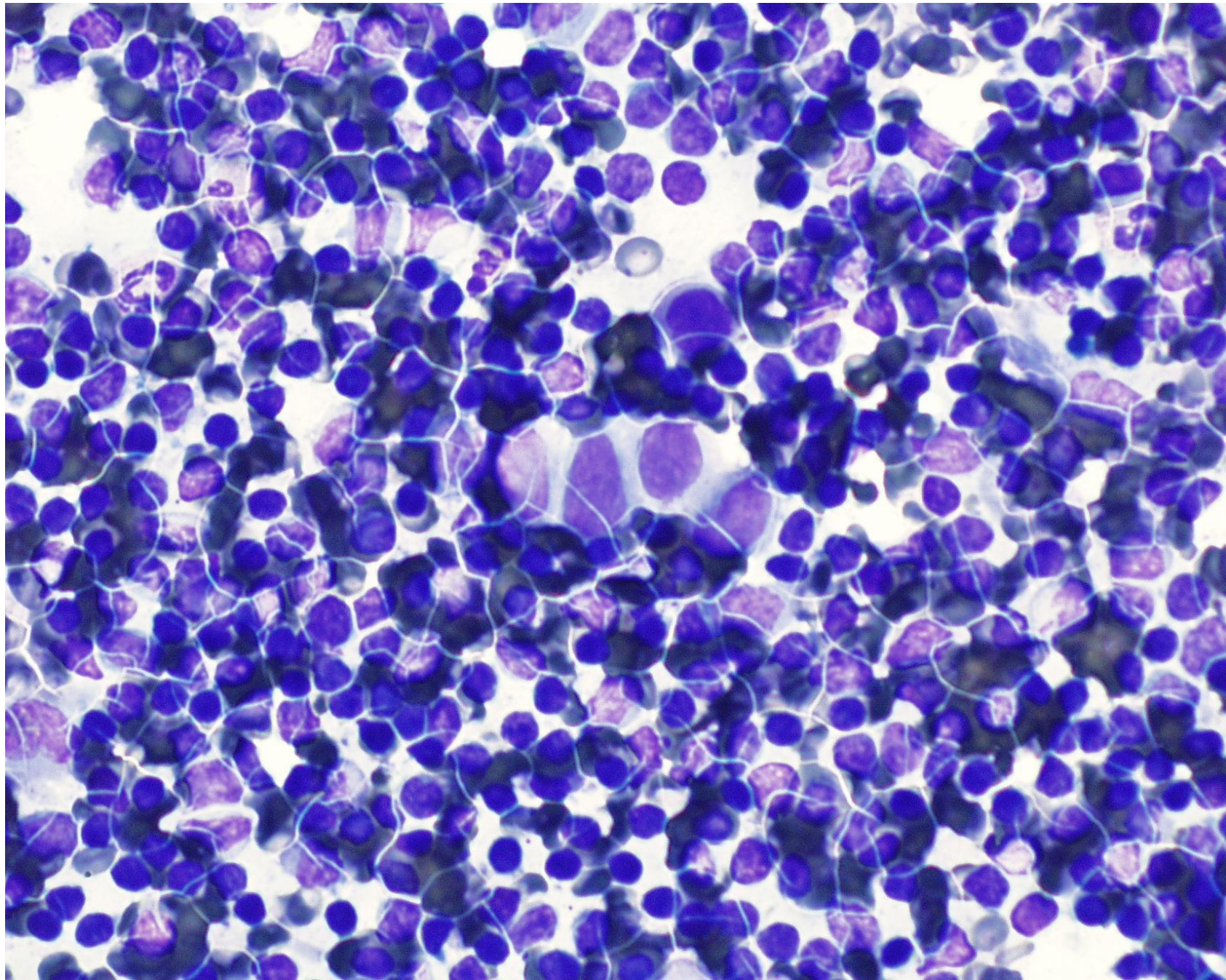


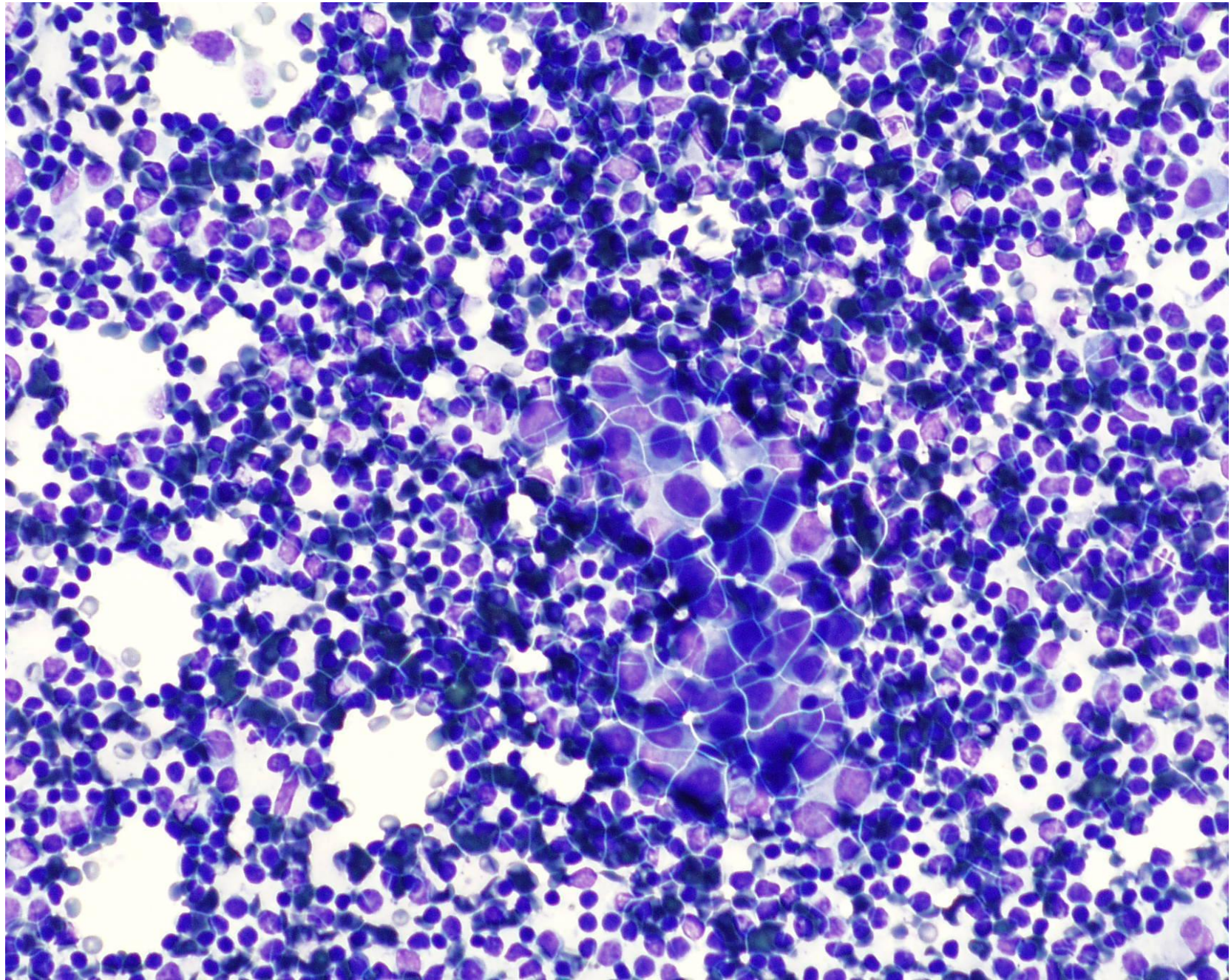


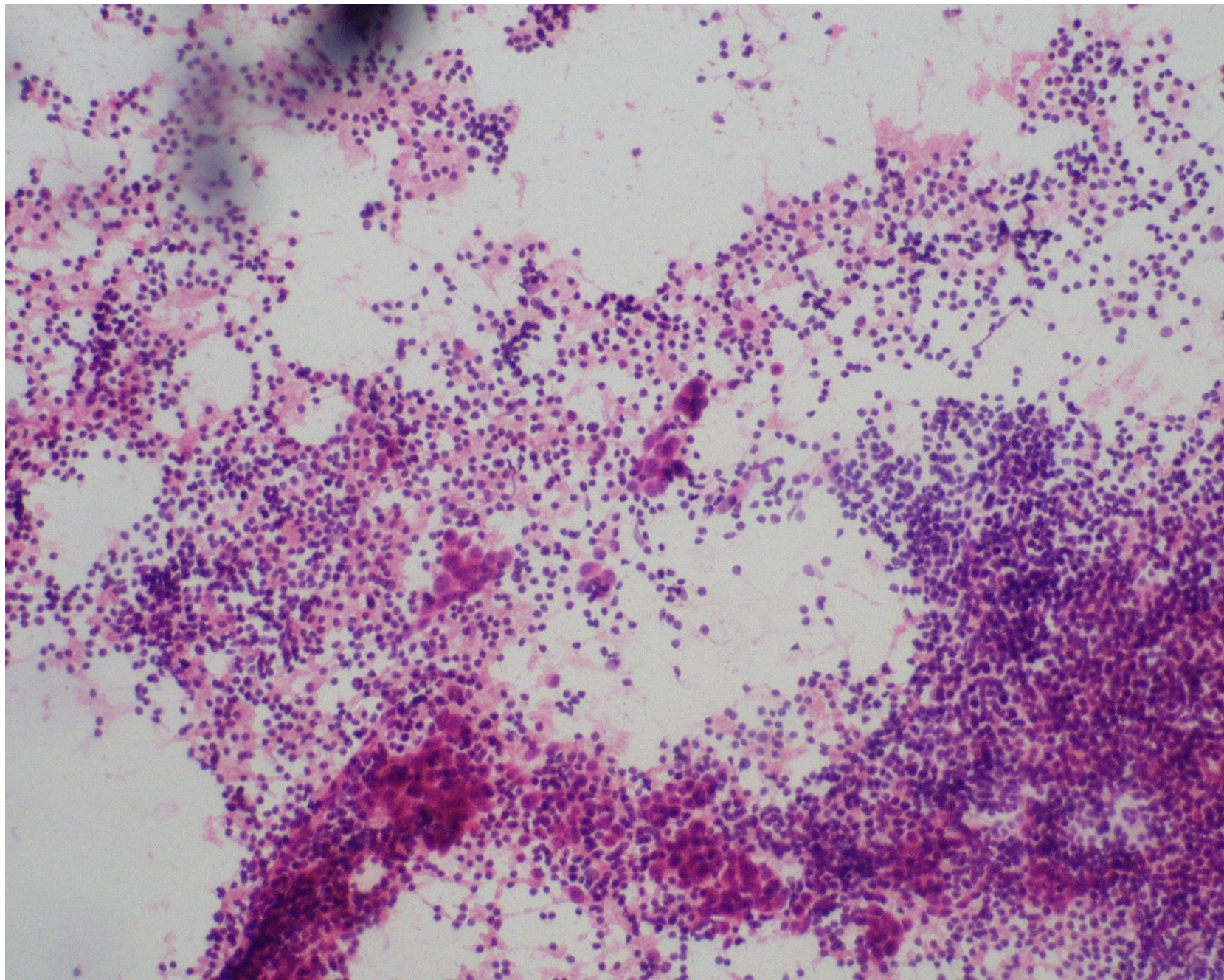
Case 37

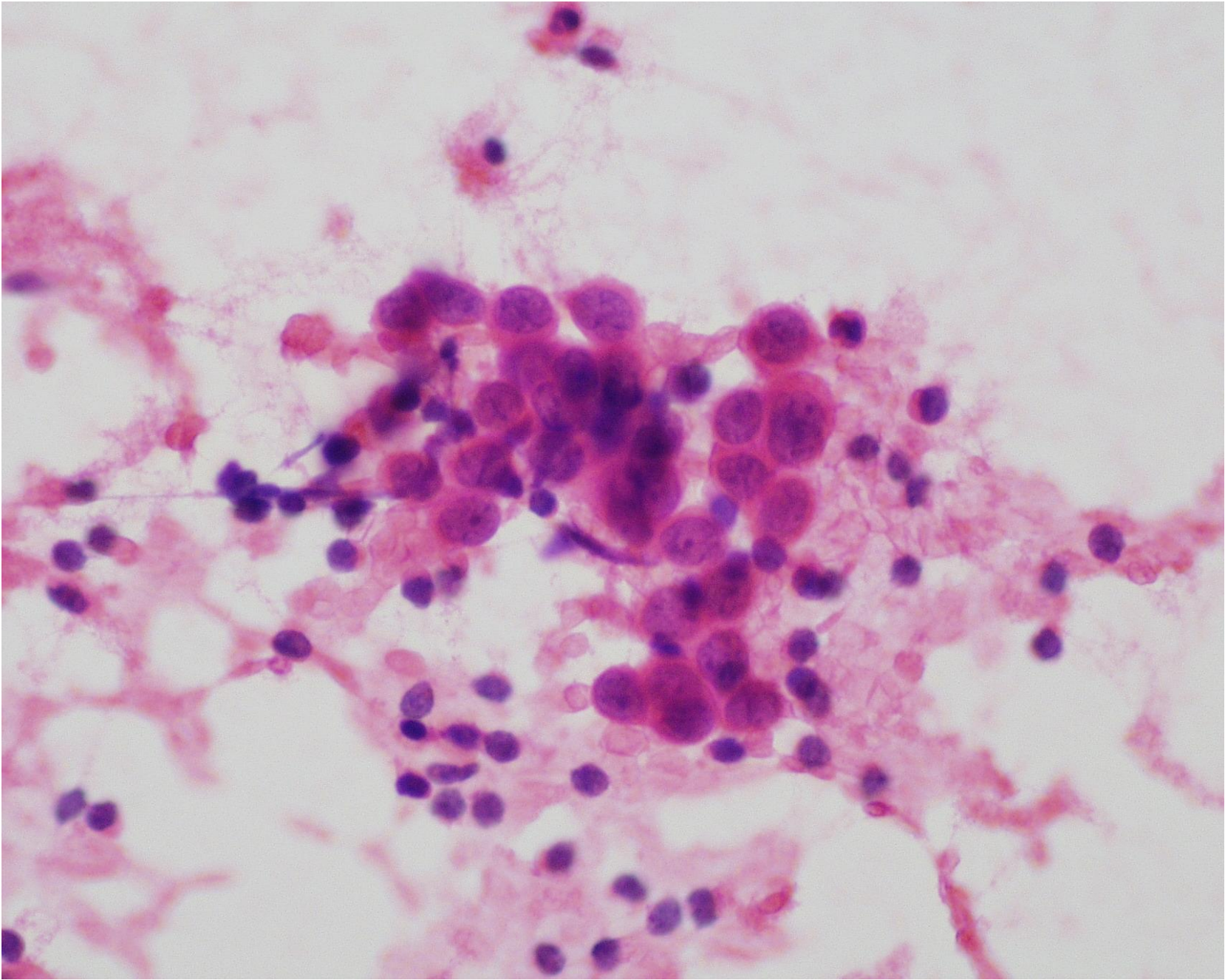
F38. Intraoperative imprint left axillary lymph node.

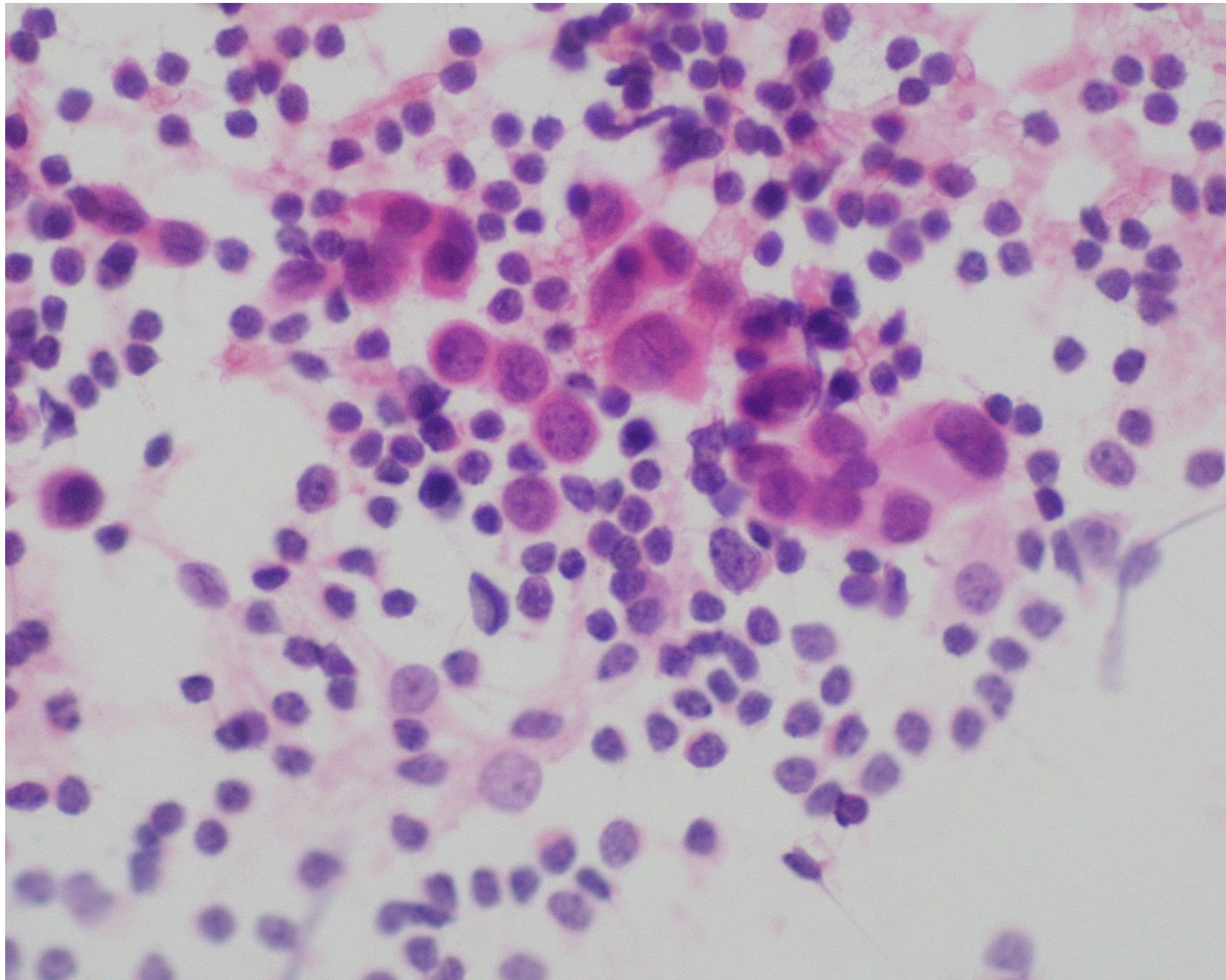






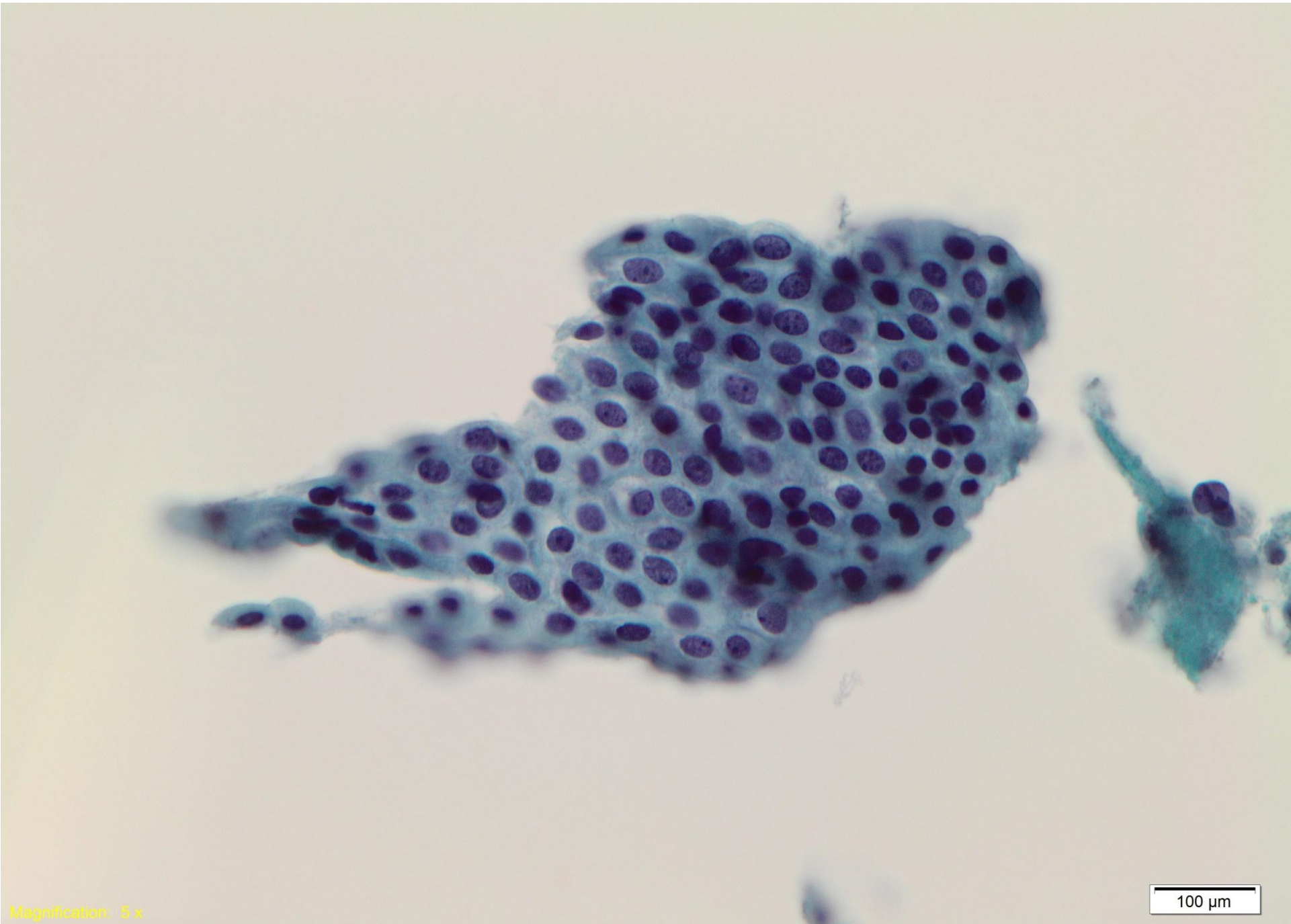






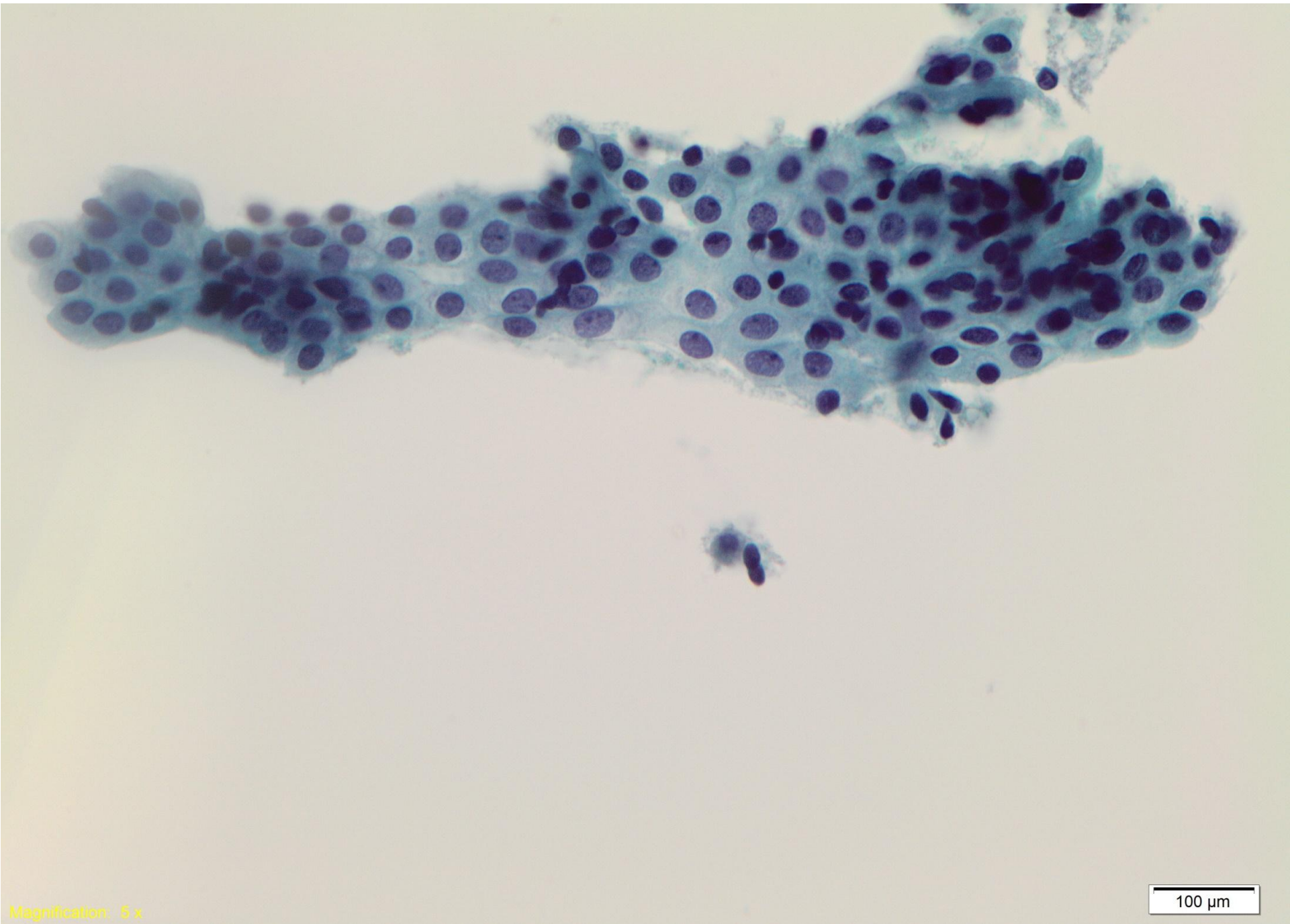
Case 38

F60. Routine cervical screening. LBC.



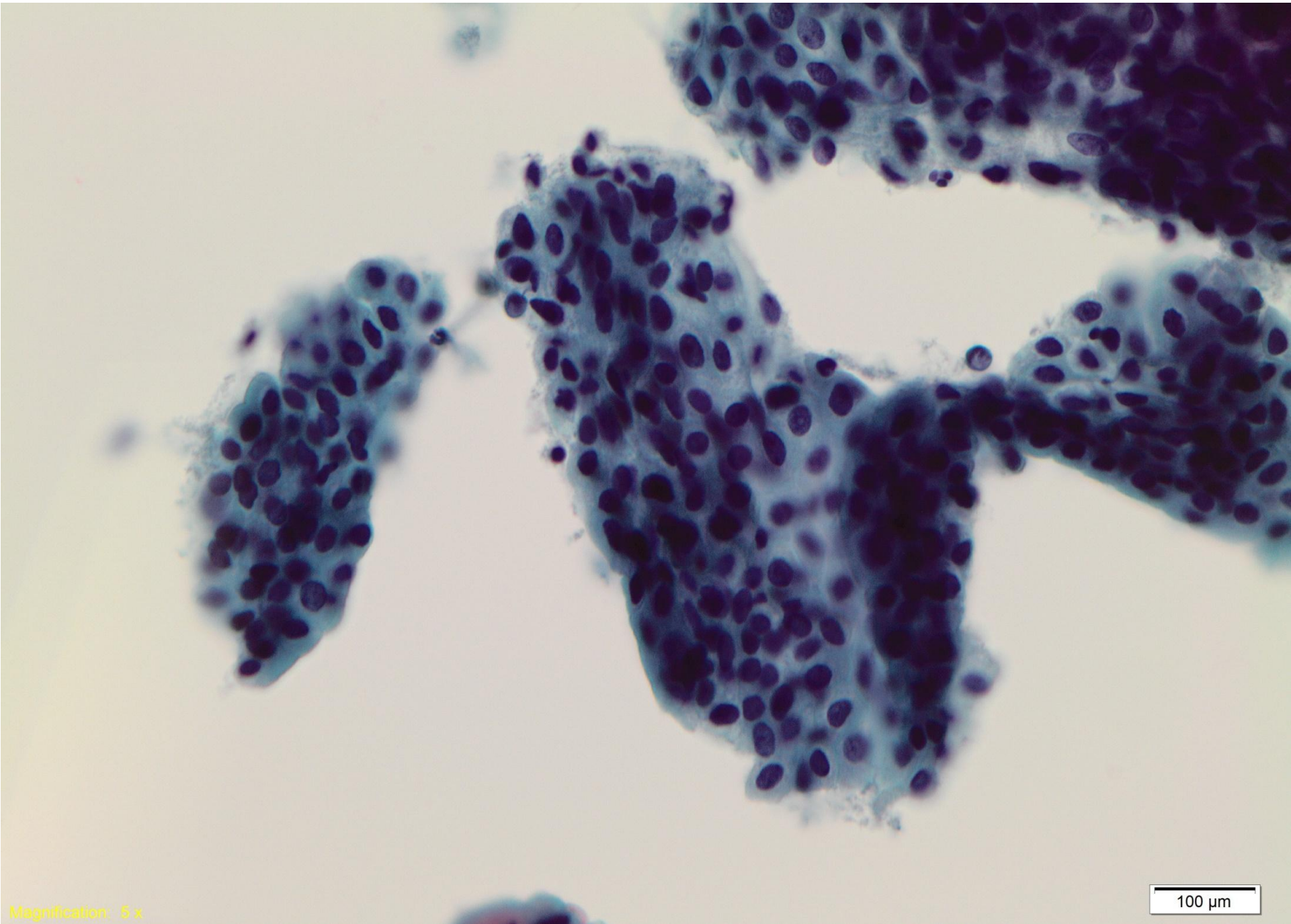
Magnification: 5 x

100 μm



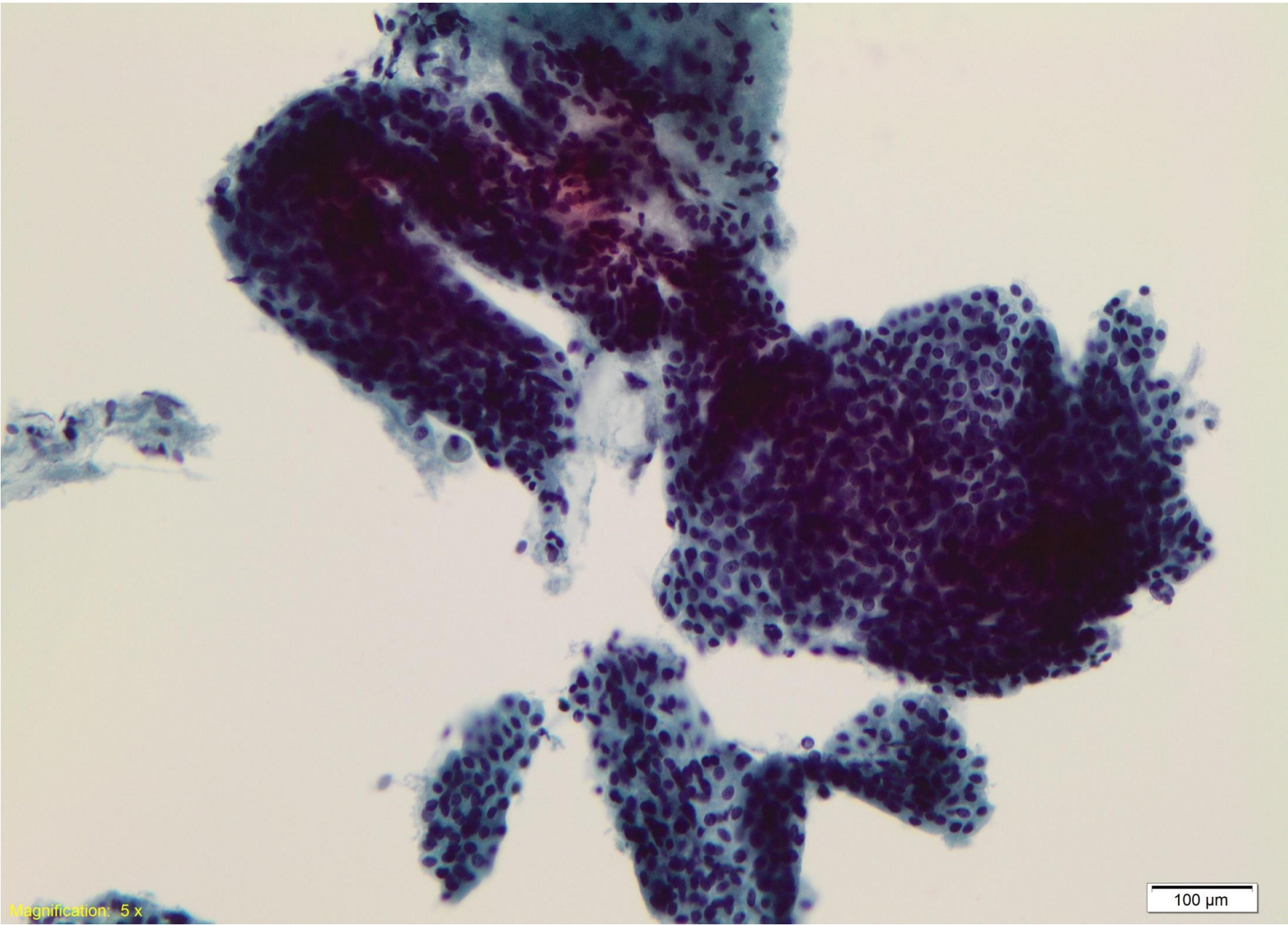
Magnification: 5 x

100 μm



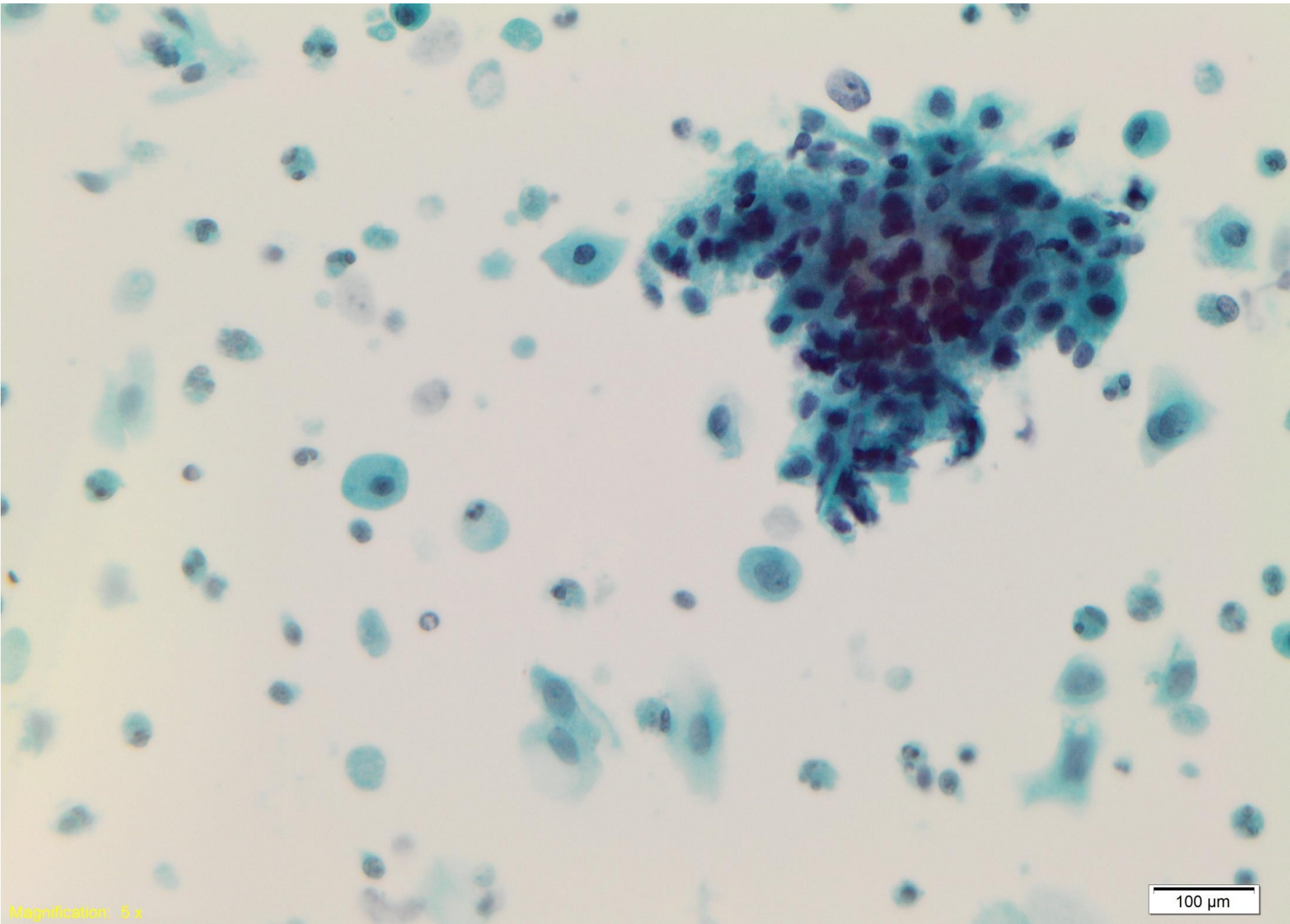
Magnification: 5 x

100 μ m



Magnification: 5 x

100 μm

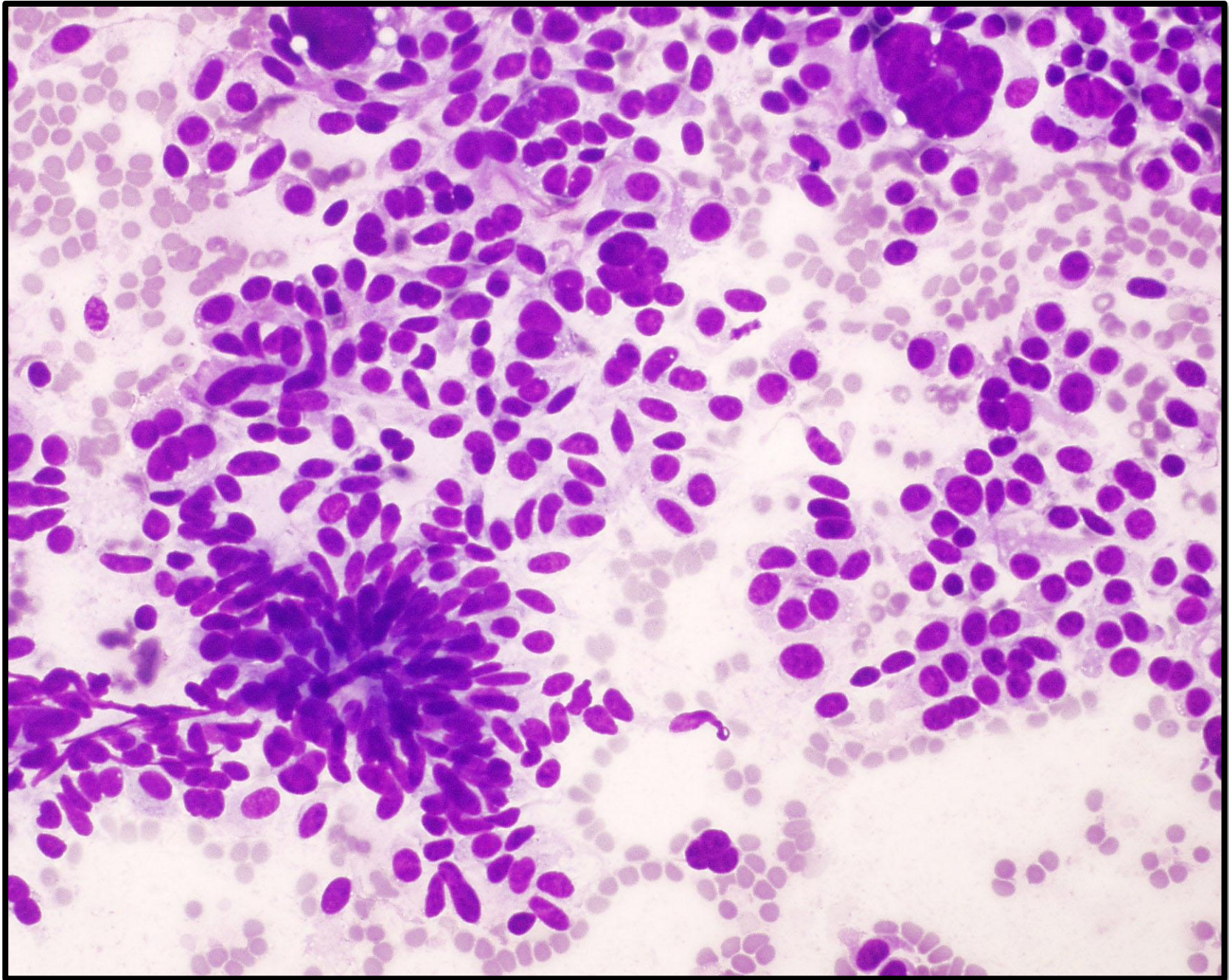


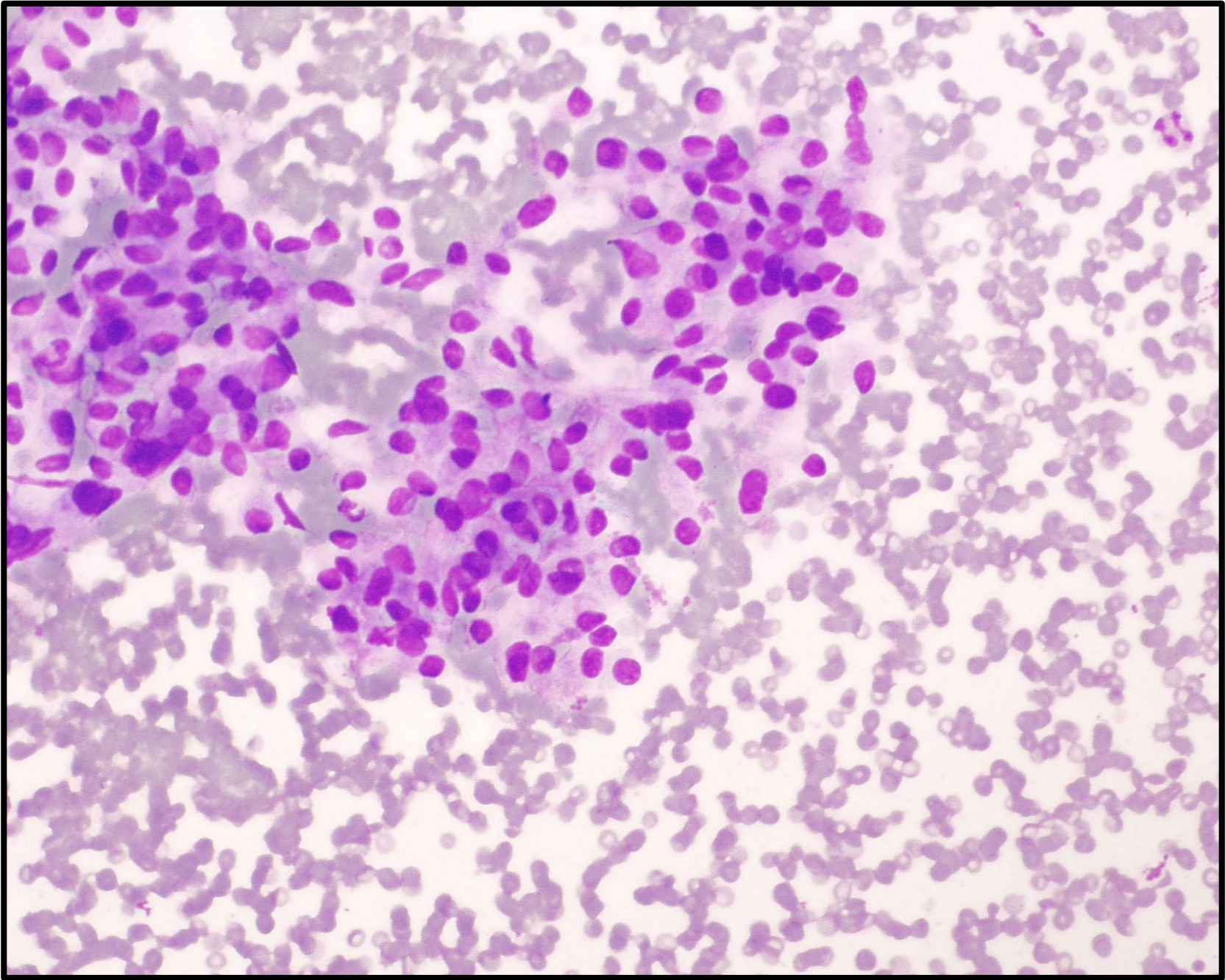
Magnification: 5 x

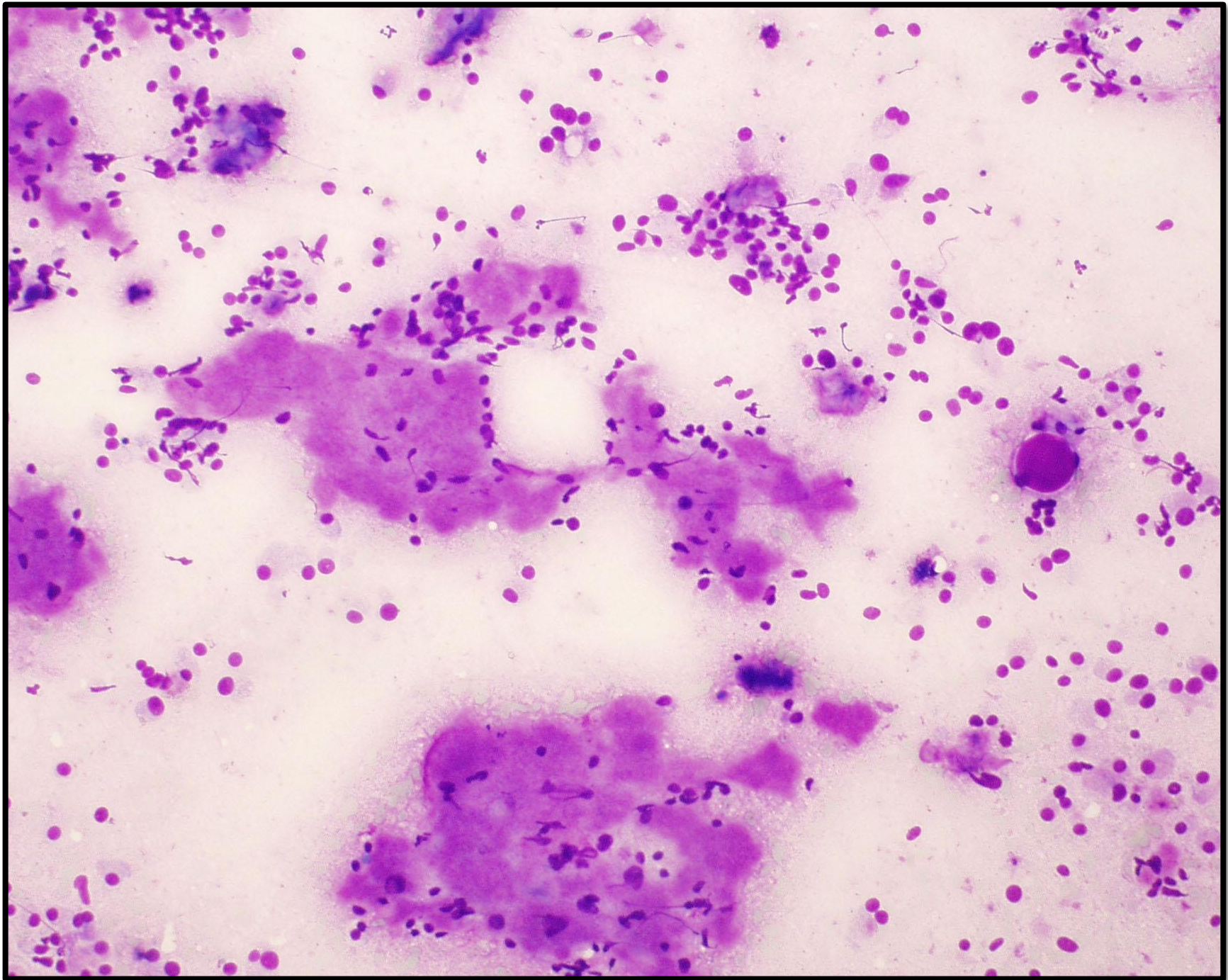
100 µm

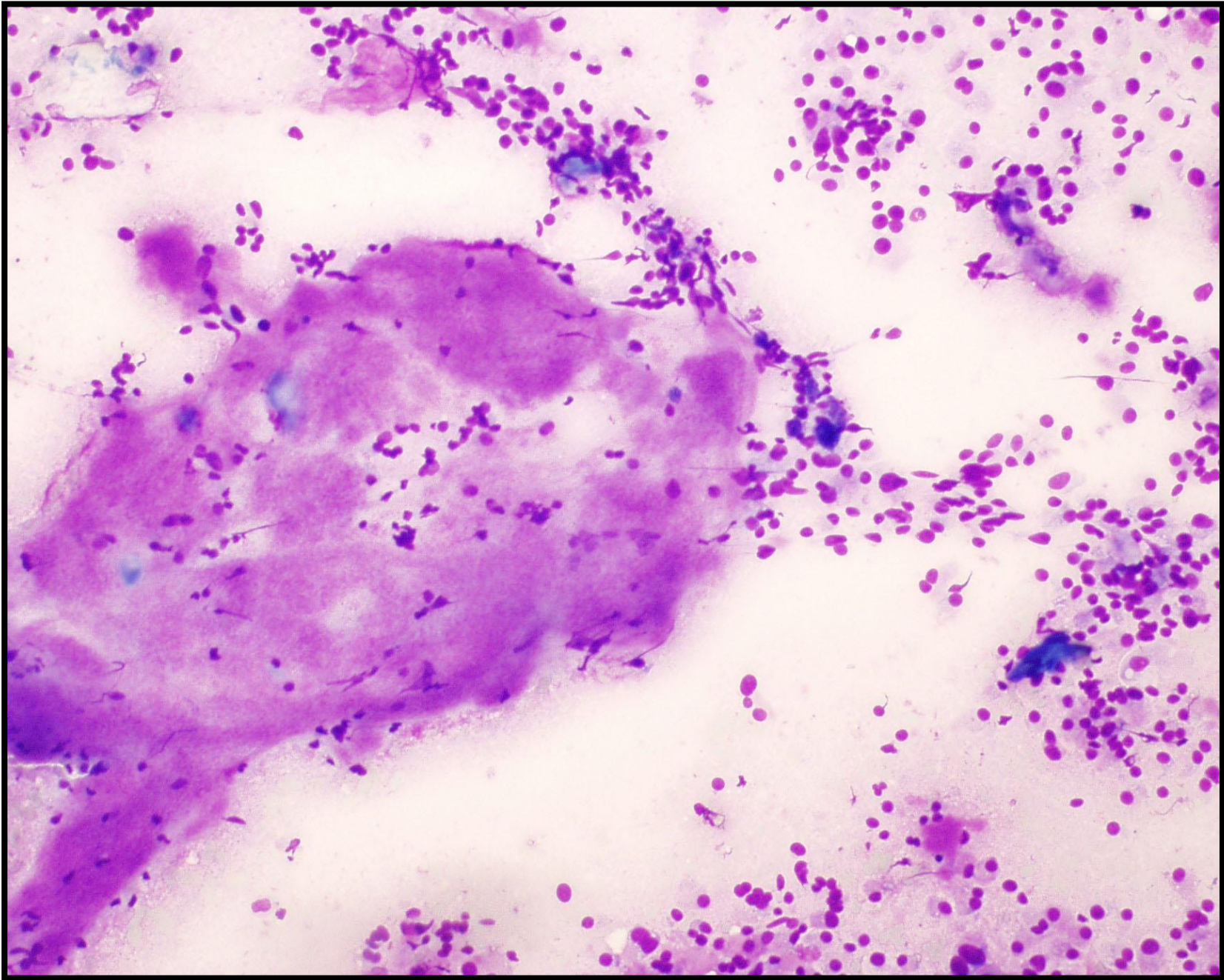
Case 39

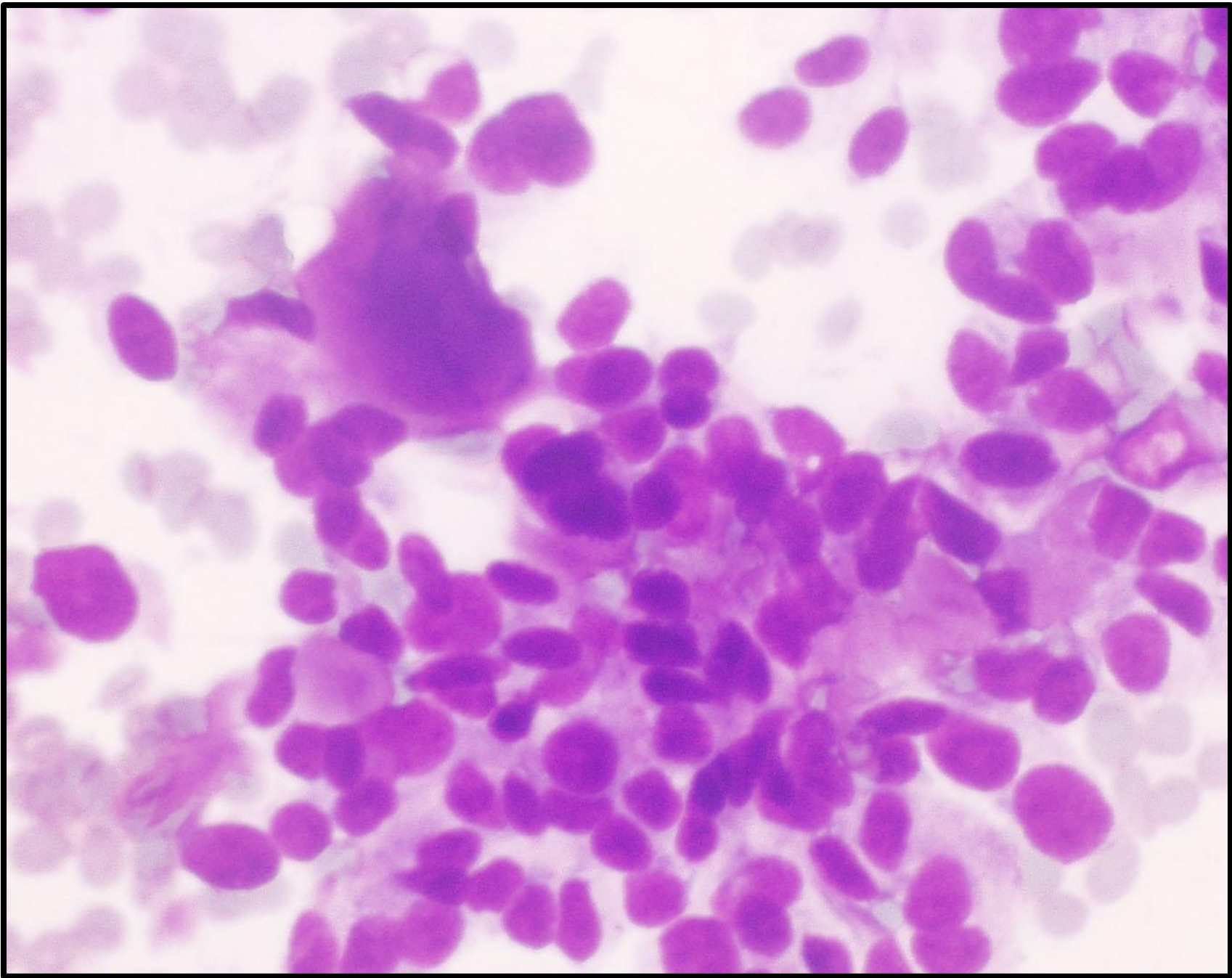
M39. FNA Thyroid solid nodule.

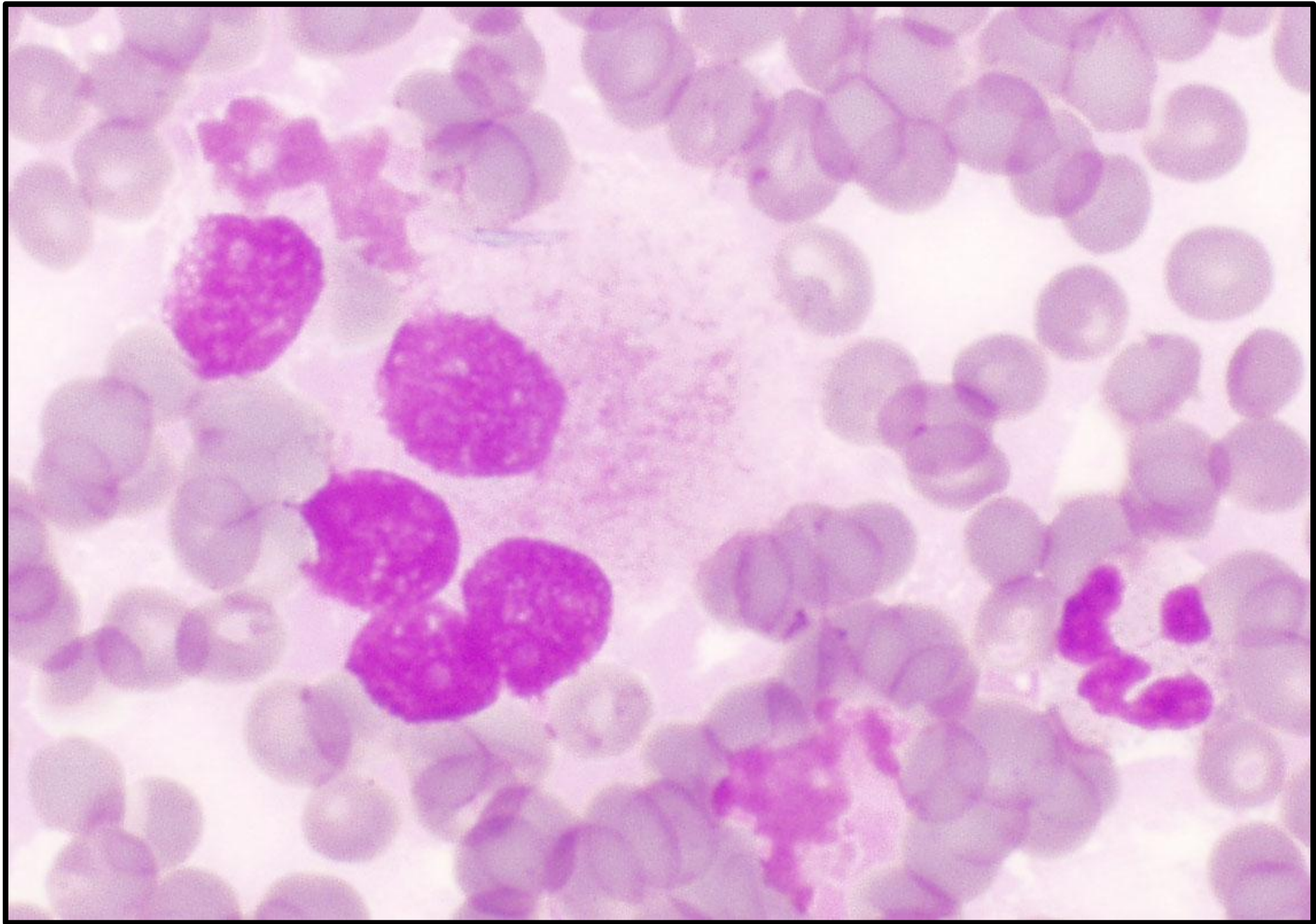


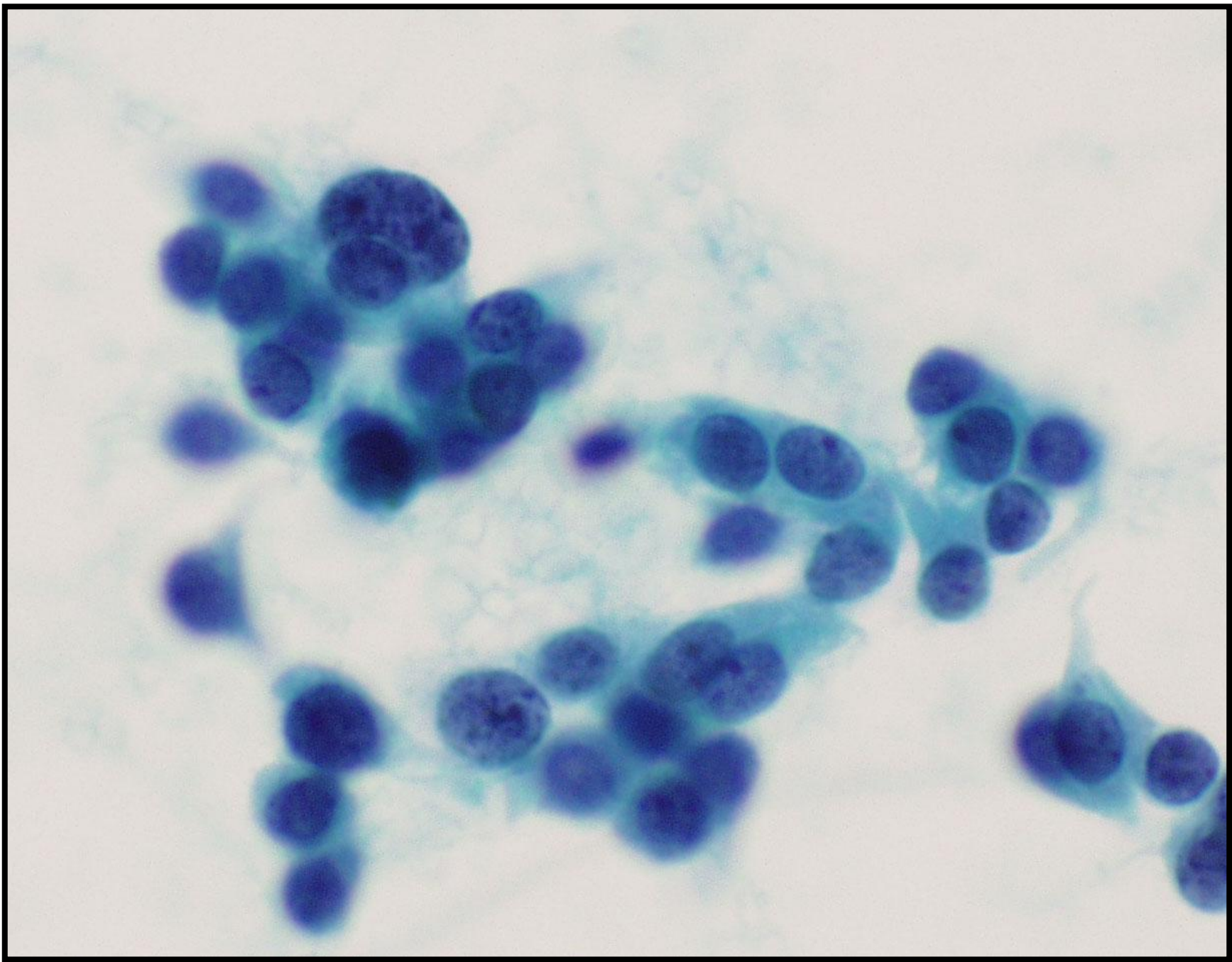






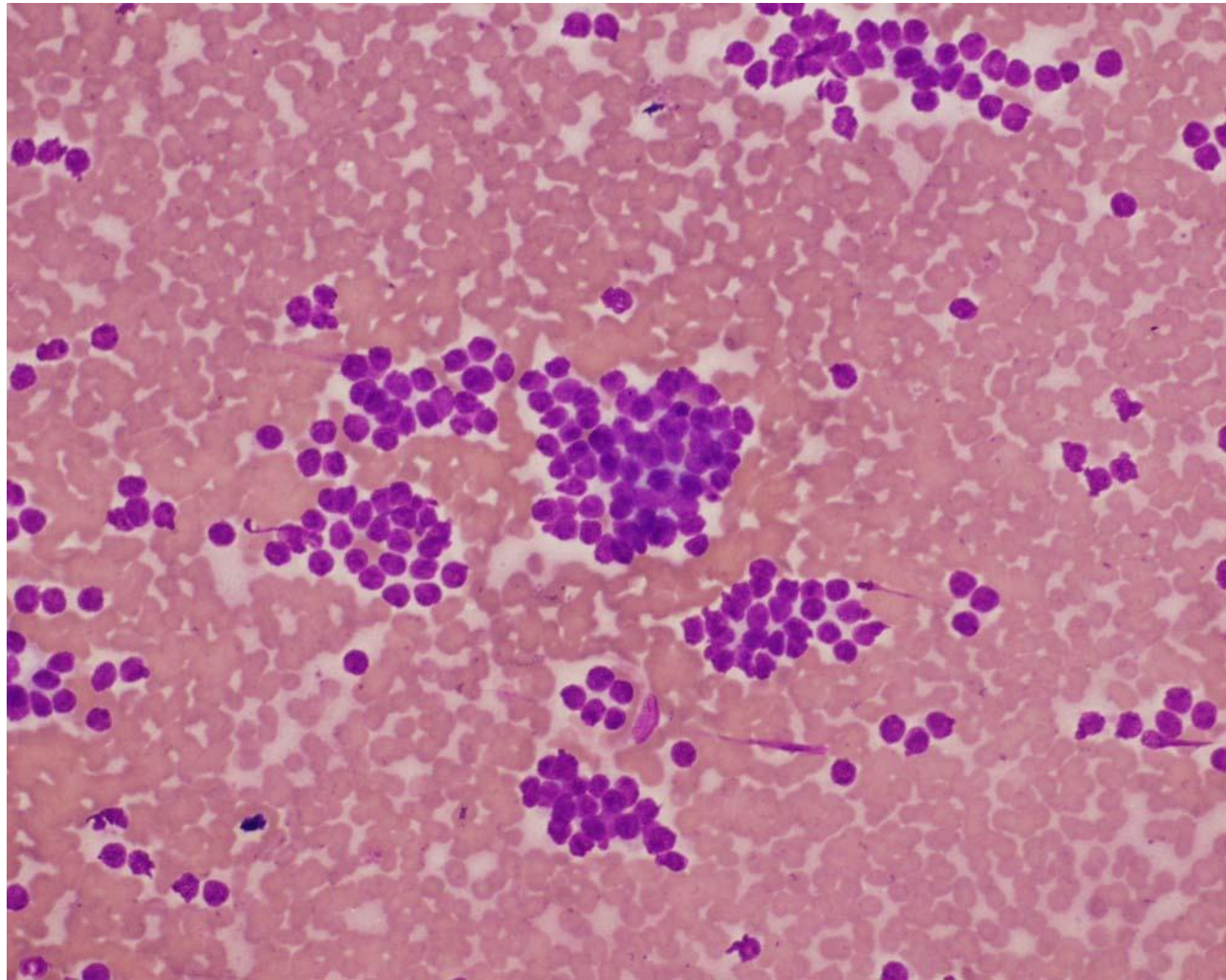


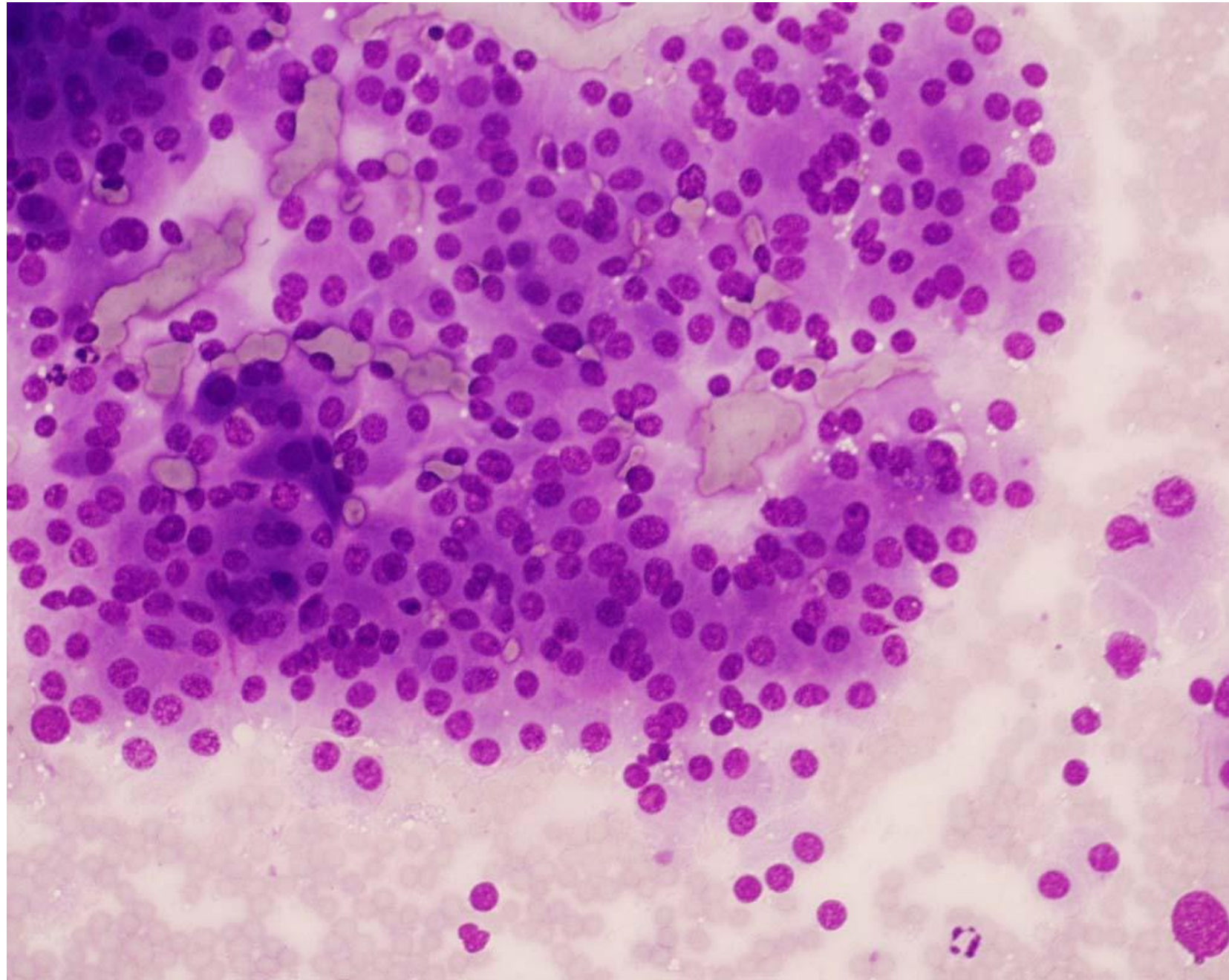


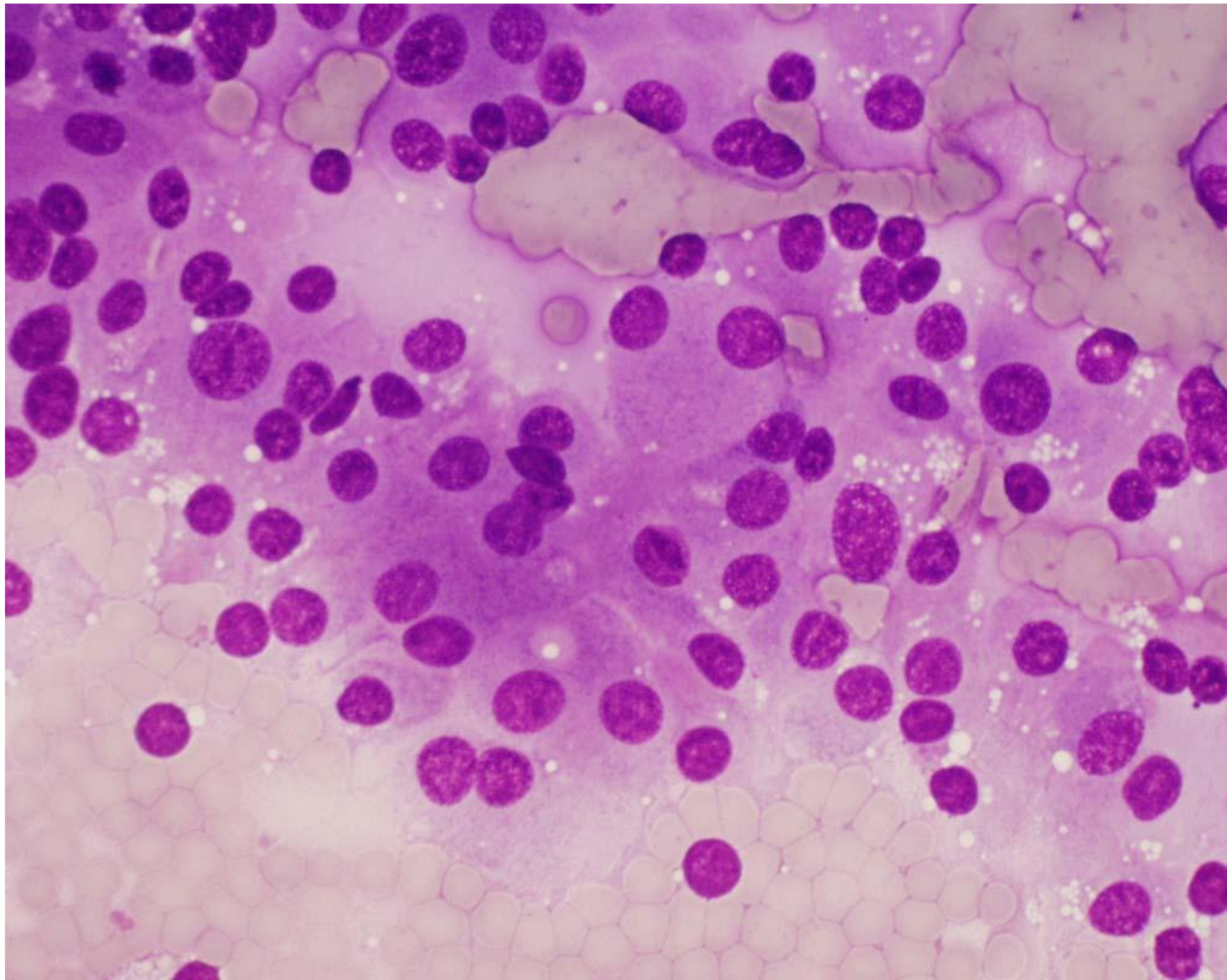


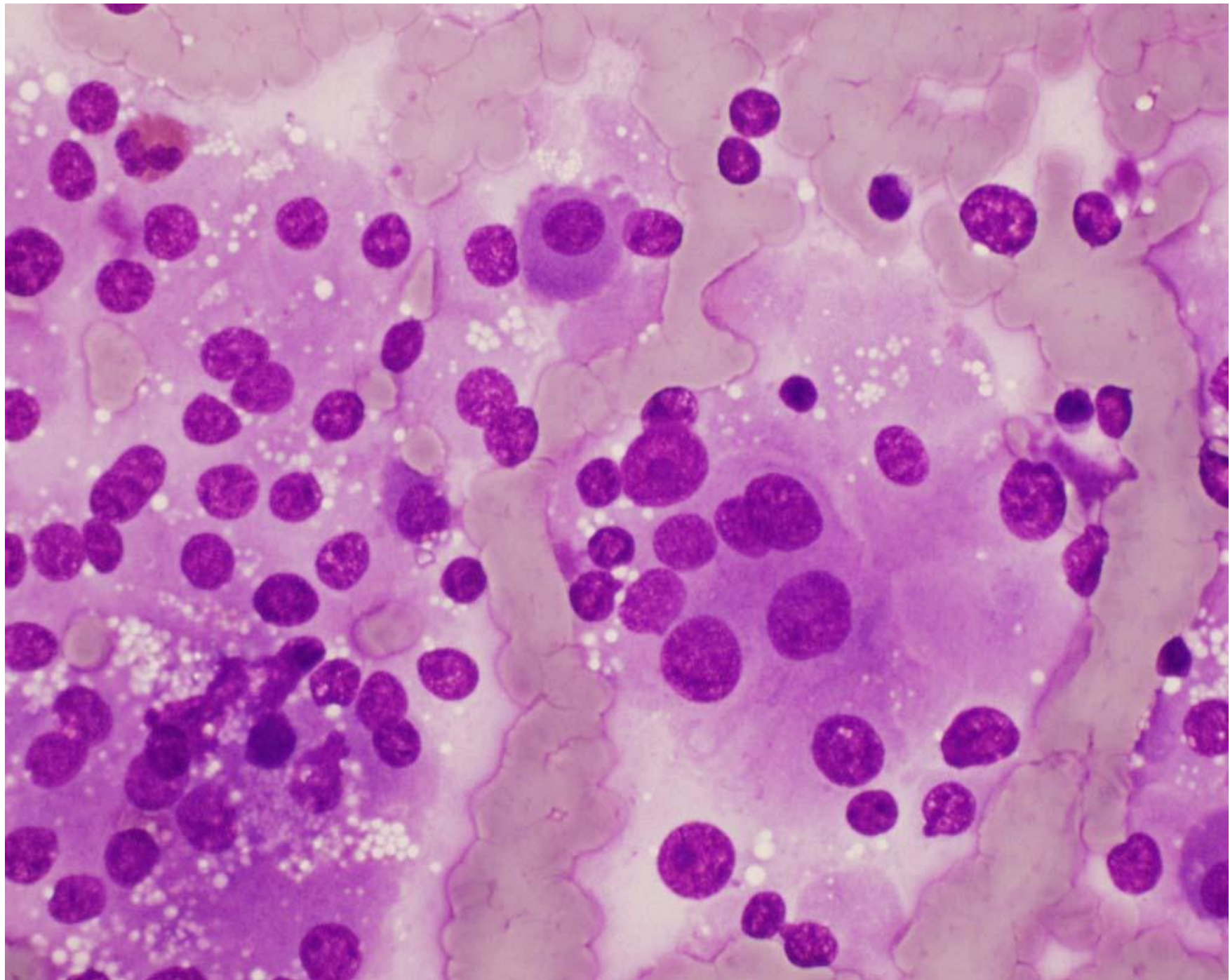
Case 40

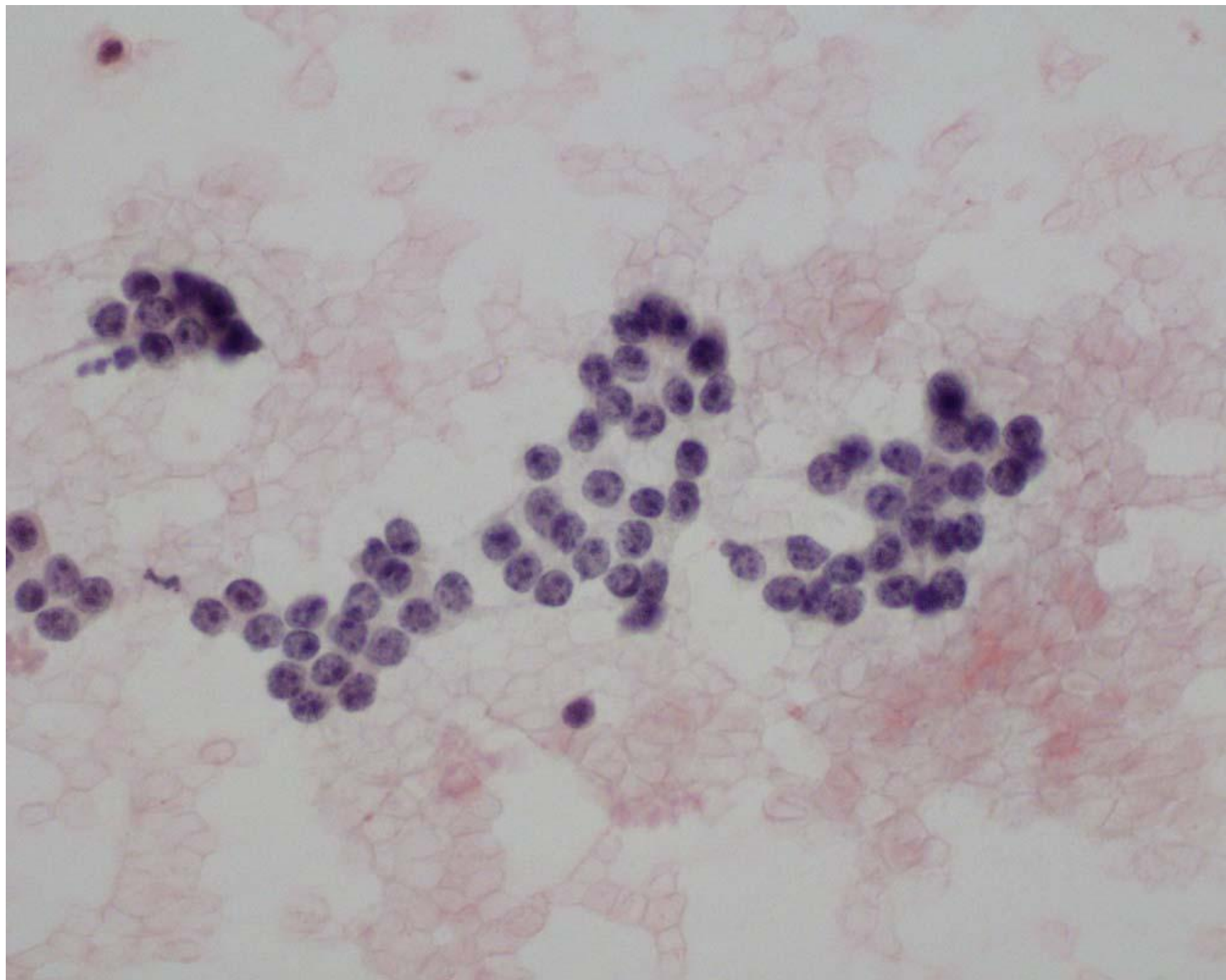
F45. Pancreatic FNA. Nodular lesion pancreatic tail.











The end.....