



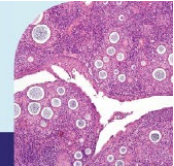
THE 50TH

Annual Scientific Meeting

Of the Australasian Division of the International Academy of Pathology

Friday May 29 to Sunday May 31, 2026

Brisbane Convention & Exhibition Centre



IAP Boot Camp Sunday 31st May 2026

Small Biopsy Boot Camp

Presenter

Yanling (Cindy) Yang

SA Pathology, Flinders Medical Centre, Adelaide, SA, Australia.

Case Presentations 1 – 45

Case 1

View link name: [SBS FS/case 1](#)

Clinical History:

88 Female, peritoneal biopsy, frozen section. Multiple peritoneal nodules.

Case 2

View link: [SBS FS/Case 2](#)

Clinical History:

49 Female, ovarian mass.

Case 3

View link: [SBS FS/Case 3](#)

Clinical History:

57 Male, right perinephric fat nodule.

Case 4

View link: [SBS FS/Case 4](#)

Clinical History:

79 Male, left medial canthus.

Case 5

View link: [SBS FS/Case 5](#)

Clinical History:

71 Male, right frontal brain lesion biopsy. ? GBM. Diffuse T2 changes across corpus callosum and frontal+temporal regions with focus of enhancement.

Case 6

View link: [SBS IHC/Case 6](#)

Clinical History:

50 Female, right spheno-ethmoidal mass.

Case 7

View link: [SBS IHC/Case 7](#)

Clinical History:

26 Female, right nasal mass.

Case 8

View link: [SBS IHC/Case 8](#)

Clinical History:

54 Female, hx of breast cancer. Left axillary tissue, abscess vs necrotic LN vs recurrent breast ca.

Case 9

View link: [SBS IHC/Case 9](#)

Clinical History:

85 Male, right retroperitoneal mass biopsy.

Case 10

View link: [SBS IHC/Case 10](#)

Clinical History:

21 Male, right tonsil.

Case 11

View link: [SBS HE/Case 11](#)

Clinical History:

65 Female, right parapharyngeal mass.

Case 12

View link: [SBS HE/Case 12](#)

Clinical History:

80 Male, right supraglottic mass biopsy.

Case 13

View link: [SBS HE/Case 13](#)

Clinical History:

74 Female, PET avid post nasal space.

Case 14

View link:

Clinical History: [SBS HE/Case 14](#)

71 Male, soft tissue over lateral hypothenar.

Case 15

View link: [SBS HE/Case 15](#)

Clinical History:

60 Female, left foot swelling.

Case 16

View link: [SBS HE/Case 16](#)

Clinical History:

51 Female, smoker, 2 tongue lesions, growing.

Case 17

View link: [SBS HE/Case 17](#)

Clinical History:

78 Female, left buccal mucosal lesion.

Case 18

View link: [SBS HE/Case 18](#)

Clinical History:

34 Female, endometrial curetting.

Case 19

View link: [SBS HE/Case 19](#)

Clinical History:

53 Female, pancreatic head lesion. EUS biopsy.

Case 20

View link: [SBS HE/Case 20](#)

Clinical History:

60 Female, ? inclusion cyst right lower lip.

Case 21

View link: [SBS HE/Case 21](#)

Clinical History:

46 Male, small subcutaneous cystic mass from vola surface of right hand 1st MCPJ.

Case 22

View link: [SBS HE/Case 22](#)

Clinical History:

43 Male, bladder tumour.

Case 23

View link: [SBS HE/Case 23](#)

Clinical History:

79 Male, left nasal mass biopsy. Mass filling left nasal cavity, arising from maxillary sinus.

Case 24

View link: [SBS HE/Case 24](#)

Clinical History:

78 Female, right renal mass bx.

Case 25

View link: [SBS HE/Case 25](#)

Clinical History:

78 Female, right temporal artery bx.

Case 26

View link: [SBS HE/Case 26](#)

Clinical History:

67 Female, left maxillary sinus polyp.

Case 27

View link: [SBS HE/Case 27](#)

Clinical History:

H&E+trichrome. 72 Male, end stage renal failure on dialysis, painful right lower limb nodular lesions.

Case 28

View link: [SBS HE/Case 28](#)

Clinical History:

34 Male, clival brain tumour.

Case 29

View link: [SBS HE/Case 29](#)

Clinical History:

73 Female, clival lesion and multiple bilateral cranial neuropathies.

Case 30

View link: [SBS HE/Case 30](#)

Clinical History:

53 Female, hard palate tumour with bone invasion.

Case 31

View link: [SBS HE/Case 31](#)

Clinical History:

22 Male, proximal right femur lesion.

Case 32

View link: [SBS HE/Case 32](#)

Clinical History:

55 Female, posterior wall bladder biopsy.

Case 33

View link: [SBS HE/Case 33](#)

Clinical History:

59 Male, oesophageal biopsy.

Case 34

View link:

Clinical History: [SBS HE/Case 34](#)

66 Female, 4th ventricle mass.

Case 35

View link: [SBS HE/Case 35](#)

Clinical History:

73 Female, right frontal tumour.

Case 36

View link: [SBS HE/Case 36](#)

Clinical History:

78 Male, large ulcerated right thigh growth, punch bx.

Case 37

View link: [SBS HE/Case 37](#)

Clinical History:

71 Female, weight loss, post-prandial nausea and vomiting.

Case 38

View link: [SBS HE/Case 38](#)

Clinical History:

47 Female, heavy menstrual bleeding.

Case 39

View link: [SBS HE/Case 39](#)

Clinical History:

64 Male, recurrent large pleural effusion, grape like nodular lesions all around the pleura and over lung surface. Ex-smoker, obesity, asbestos exposure ++.

Case 40

View link: [SBS HE/Case 40](#)

Clinical History:

87 Male, rectal polyp.

Case 41

View link:

Clinical History: [SBS HE/Case 41](#)

84 Male, left neck mass core biopsy.

Case 42

View link: [SBS HE/Case 42](#)

Clinical History:

73 Female, sigmoid biopsy, on mycophenolate for myasthenia.

Case 43

View link: [SBS HE/Case 43](#)

Clinical History:

87 Female, left anterior lateral leg.

Case 44

View link: [SBS HE/Case 44](#)

Clinical History:

82 Male, prostate biopsy. Right posterior bladder wall tumour biopsy.

Case 45

View link: [SBS HE/Case 45](#)

Clinical History:

64 Male, right temporal lobe collection with mass effect. B/G follicular lymphoma on 2 monthly monoclonal antibody.